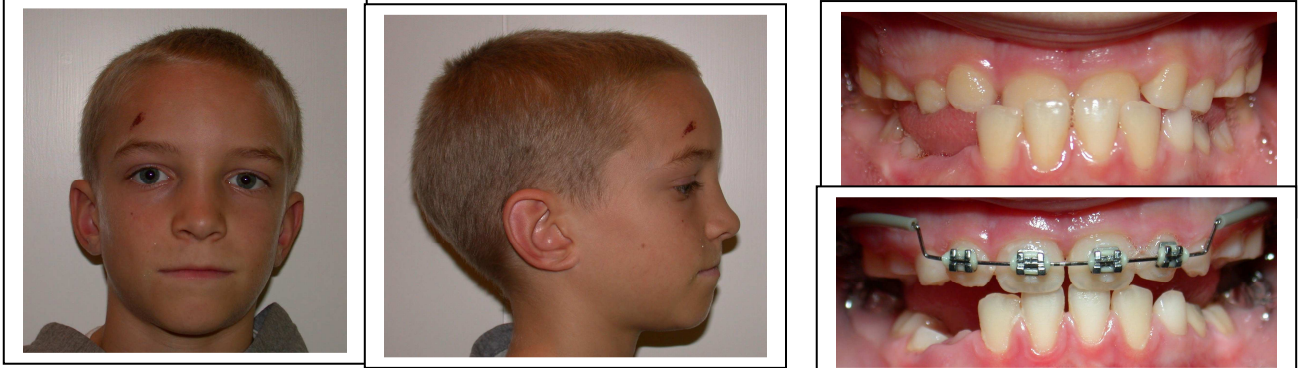


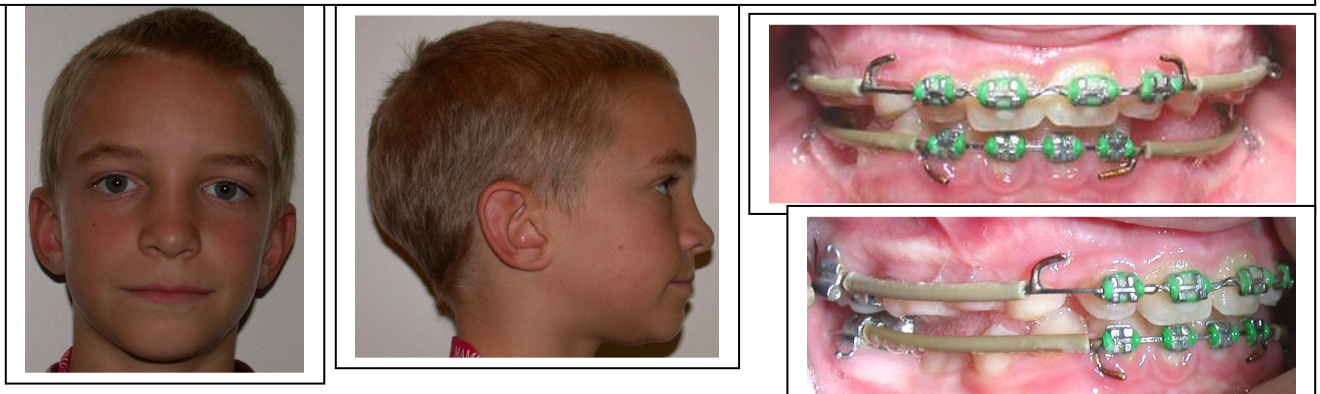
Dr. Larry Brown's system of "Esthetic Orthodontics" is used in these early mixed-dentition, non-extraction cases. This system of *Esthetic Diagnosis and Treatment Mechanics*, combined with the Straight Wire Appliance (SWA) is used as a "fixed functional appliance" in order help eliminate Dysfunctional Habits and then to enact "Growth Modification" so as to *change the face*.

Case: Boy aged 11 years ; CLIII dental and skeletal – "a functional problem"

Beginning - Cross-bite is "jumped in 3 weeks using the Utility Arch Wire



After 9 months –end of 1st phase – pseudo CLIII "growth pattern" has been corrected to a CLI occlusion



24 Months – CLI occlusion is firmly established

