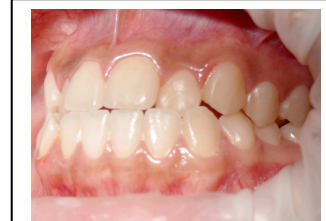
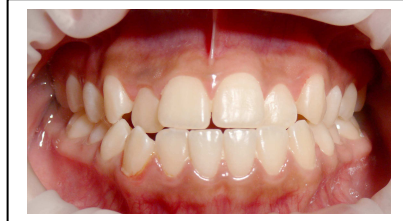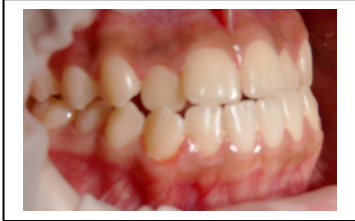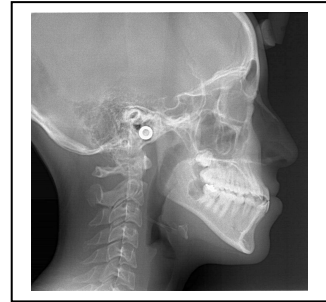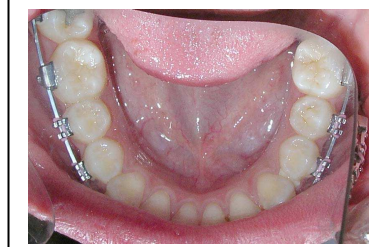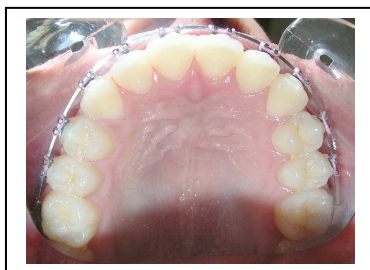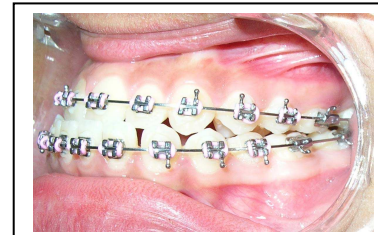
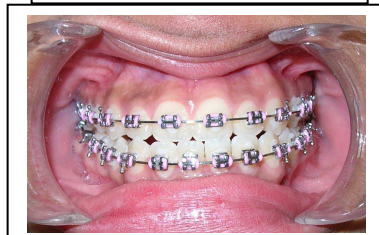
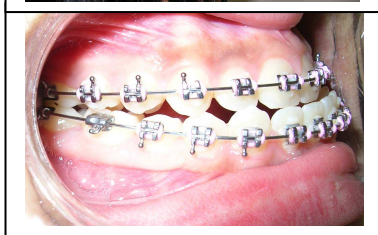



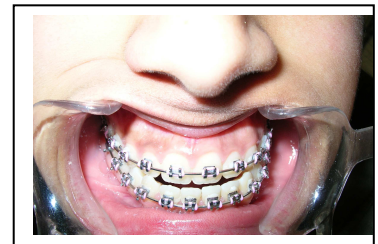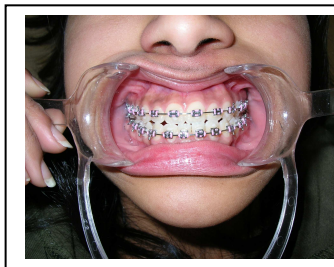Surgical Case: Female age 16 years Full CLIII dental and skeletal.

The mandibular arch is skeletally normal for the ethnic group, however the maxilla is skeletally retrognathic. Treatment plan: orthodontics followed by Le Fort I surgical procedure (maxillary skeletal advancement to correct the CLIII) *by the maxillo-facial surgeon.*

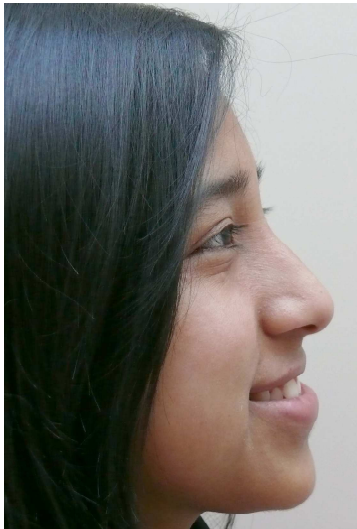


6th month: All teeth are bracketed/banded. The final stages of leveling with the SWA. 21x25 Steel wires.

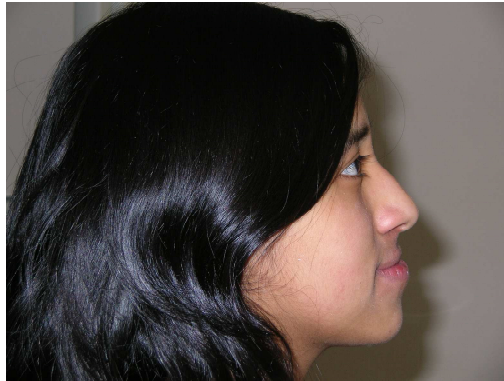


Final photos after the Le Fort 1 surgical procedure - maxillary advancement.

Début



Mois 6



Après

