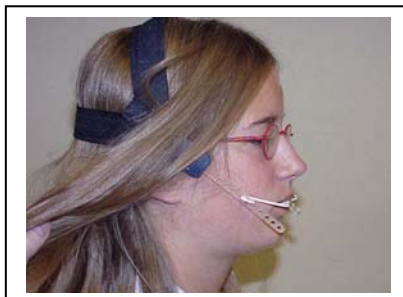


KLAARJE Case: female 11.5 years old ; CLII div I with severe deep bite and vertical maxillary excess
Treatment mechanics: SWA with the heat activated NiTi Transpalatal molar rotator/expander; Hi-pull head-gear for maxillary growth modification and molar vertical anchorage; intra-oral elastics



1st month

6th month

19th month

24th month

