

Orthodontic Extraction and Surgical Treatment of CLIII Malocclusions using the Straight Wire Appliance

Publication for the *Dental News* in Belgium

Orthodontic therapy for patients with CLIII malocclusion in which extractions or orthognathic surgery are needed (mainly adolescent patients at the end of the growth period or adults) requires completely different treatment strategies, as compared to younger growing patients. If a patient has a moderate skeletal CLIII situation, then extraction therapy can be employed. This is called Camouflage CLIII therapy, in that the CLIII dental occlusion and toothcrowding are treated to a more pleasing CLI canine occlusion and the "CLIII Look" is reduced for a more pleasing esthetic soft-tissue profile. In other words, the underlying CLIII skeletal condition remains, but it is *camouflaged*.

In most **extraction cases**, the 1st premolars are the teeth that are most commonly extracted. However, often we must compromise on this idea because many adults already have other missing teeth or have certain teeth which are non-restorable and need to be extracted, so that in each quadrant, a different tooth type may be extracted (or none may be extracted) in order to obtain an acceptable result. Many adult cases require some compromise, but the final treatment result must have acceptable facial esthetics and occlusion.

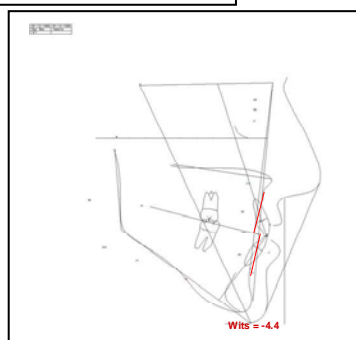
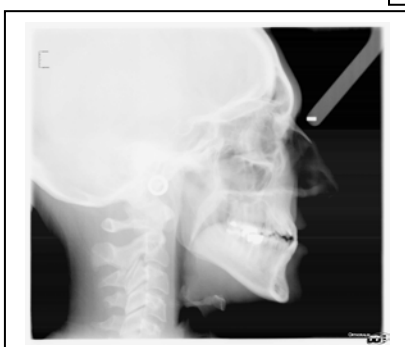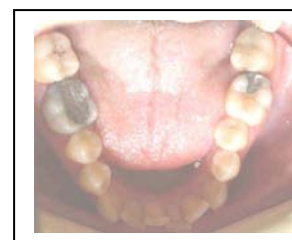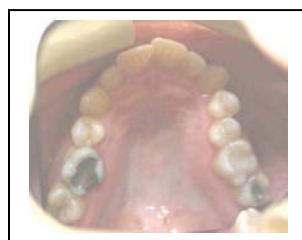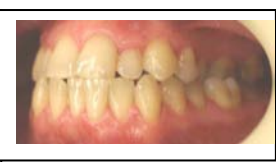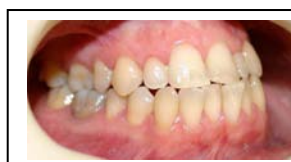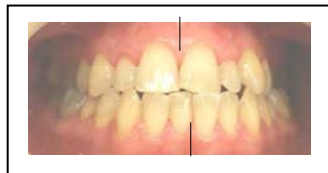"Premolar extraction" provides about 8 mm of space per quadrant and is the accepted way to provide space in order to: 1. *Relieve crowding* 2. *Retract incisors that are too protruded* 3. *Move the posterior teeth mesially*. "Premolar extractions" provide space for crowded incisor alignment where, without the extractions, the treatment would create excessive anterior protrusion that is esthetically and dentally unacceptable. It allows as well to be able to "camouflage" moderate CLIII jaw relationships when "Growth Modification" is no longer available (adult cases).

The important thing is deciding which teeth to extract and then how the spaces are to be closed. Will the incisor teeth be retracted, the posterior teeth be moved mesially or a combination of both?

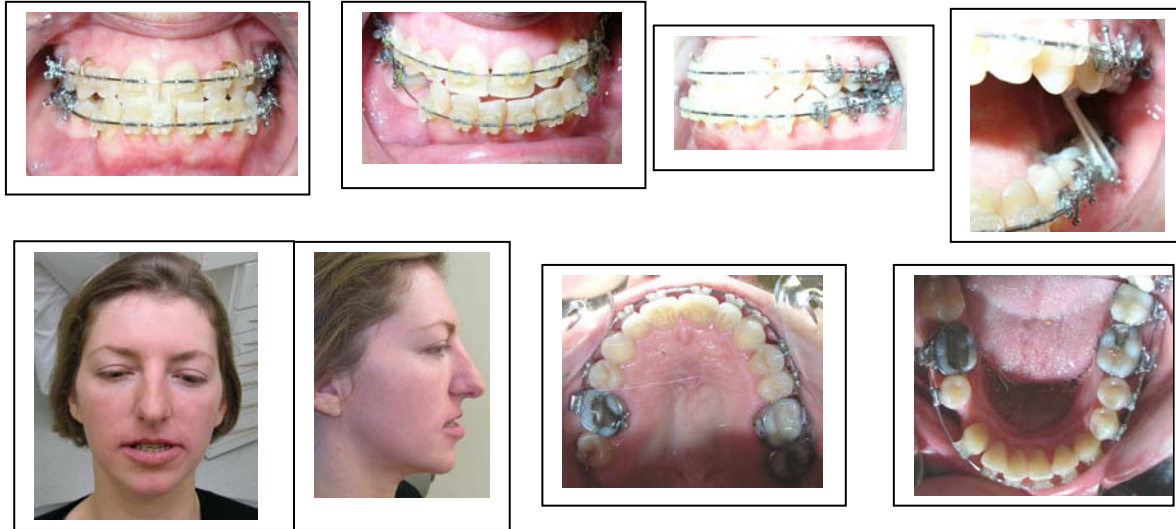
The mechanics used today for all tooth movements during space closures are called "sliding mechanics". Elastic forces, either NiTi closing springs or intra-oral elastics, combined with 19x25 steel wires and brackets of SWA, allow a *translation movement*. *Thus one can move* ("slide") along the wire an individual tooth and/or a group/segment of teeth (en masse space closure) towards their final position in each individual arch and towards the final optimal occlusion. These elastic forces can be "CLI, CLII or CLIII".

Case 1 : Adult female CLIII dental and skeletal posterior cross-bite severe dental crowding maxillary and mandibular midline discrepancies.

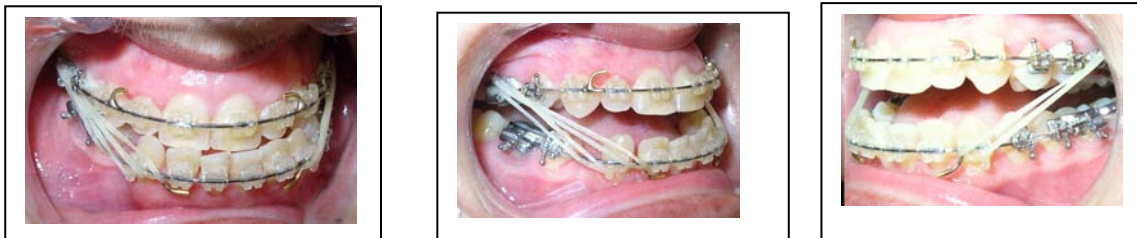Treatment plan: Camouflage CLIII extraction therapy. Extraction of #44 will allow corrections of the CLIII anterior dental positions, aligning the midlines and removing the crowding.



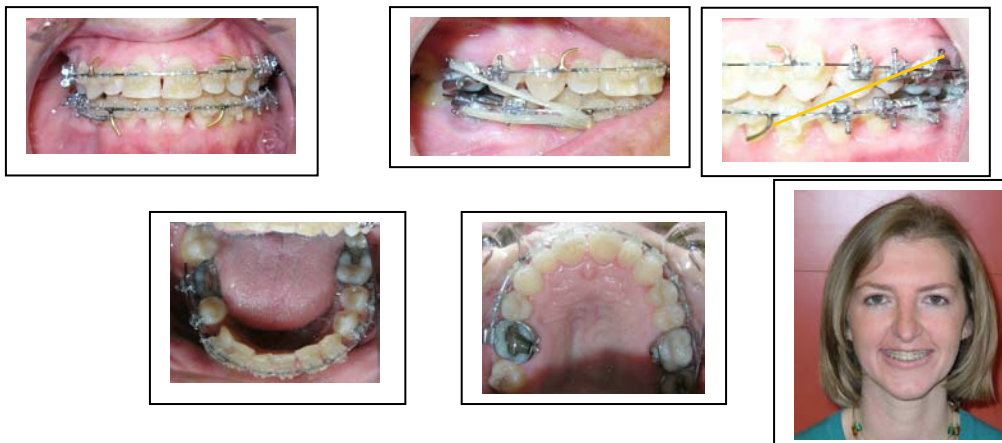After leveling with thermo-activated NiTi wires – 7th month: the posterior cross-bite is corrected using steel wires and elastics, but the anterior cross-bite and midline discrepancies now need to be corrected. The CLIII look is temporarily worsened.



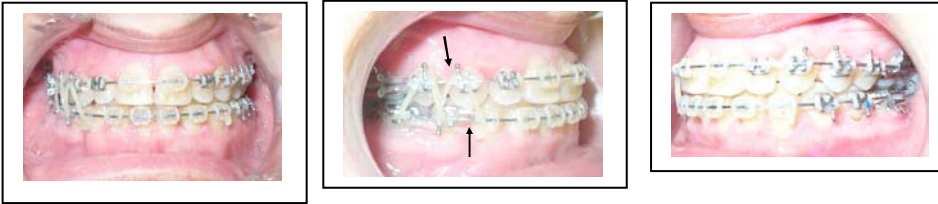
8th month: 19x25 posted steel wires; begin 8mm CLIII elastics, 2 on the right and 1 on the left; this *asymmetric elastic combination* will correct the asymmetrical CLIII situation with “en masse space closure” on the right, and will as well correct the maxillary and mandibular midlines discrepancies at the same time. The maxillary arch will be slightly advanced up to 1 to 2 mm with these “CLIII forces”, which also helps correct the CLIII Look.



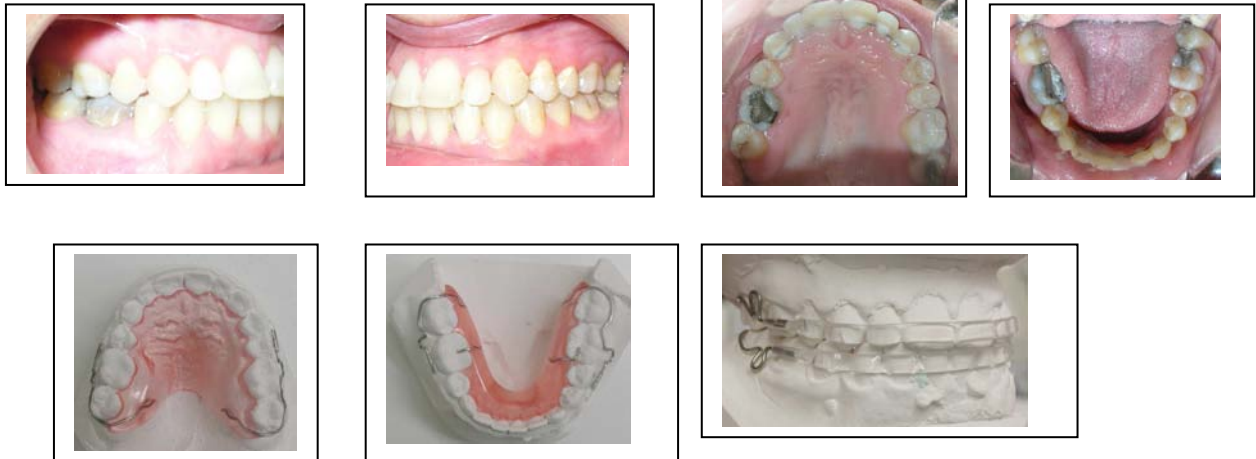
12th month: same 19x25 posted steel wires; midlines are corrected; CLI occlusion; continue 8mm CLIII elastics, 1 per side; CLI elastic and a 200 gram NiTi closing spring attached from 46 to the wire post to close the remaining space.



Finishing: 19x25 HA NiTi wires; after rebracketing, the final settling-in of the occlusion is accomplished using 6mm delta elastics for 2 weeks, 24/24 (wires are "segmented" at arrows).

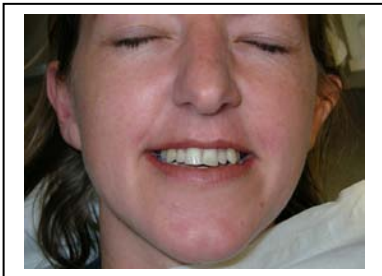

Final and retention: tooth whitening; fixed lingual retention wires : removable QCM retainers



Beginning

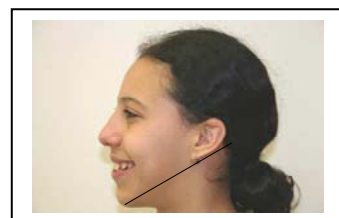
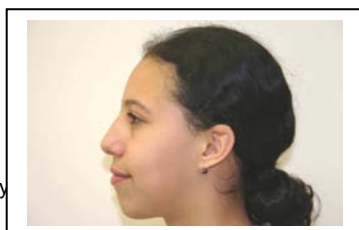
Finish



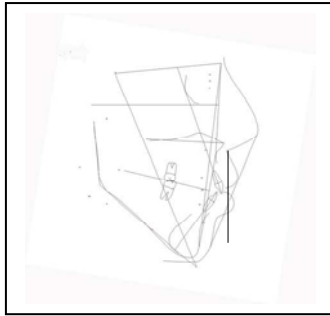
Case 6: *adolescent female patient* is to be treated with **extraction therapy** for several reasons: 1. to gain space to align the unsightly crooked-crowded teeth 2. to correct the CLIII **dental malocclusion (skeletal the patient is about 3mm CLIII)** 3. A high mandibular-plane angle is also a contributing reason ("long-face look") 4. finally because of the excessive "BiPro/CLIII look".

The "too full" appearance and unsightly crowding of the teeth are the *chief complaints* of the patient.

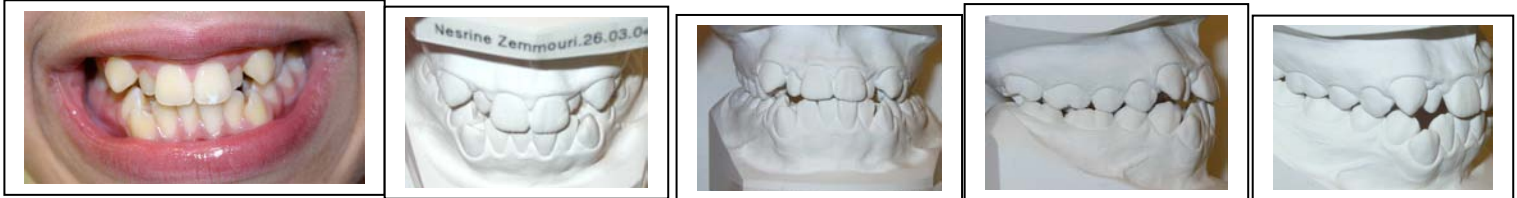
Case 6 : Female, age 13 years, CLIII skeletal (WITS = +3), high mandibular plane angle (46°)
Problems to solve: 1. CLIII dental - full canine and molar CLIII 2. camouflage the CLIII skeletal 3. posterior and anterior cross-bites 4. convex/BiPro/CLIII "Look" 5. "Peg-laterals"



The by Dr Larry






SNA	81.3
SNB	77.8
ANB	3.6
Mx 1 - NA	<u>8.6</u>
Mx 1 - NA	22.5
Md 1 - NB	<u>11.7</u>
Md 1 - NB	29.2
Interincisor Angle	124.7
PO - NB	0.3
GO-GN - SN	<u>46.0</u>
Md1 - APg	<u>7.3</u>
AO - BO Wits	<u>-2.7</u>
Y axis	<u>72.7</u>



The 4 first premolars were extracted in order to create space in both arches to:


1. **MAND:** align the crowded anterior teeth and to have space in order to camouflage the CLIII skeletal by distalizing the 6 lower anterior teeth into a CLI position.
2. **MAX:** to distalize the 23 & 13 about 3mm per side in order to make the composite "veneers" on 12 & 22 (to look more esthetic) .

1


2


3


4


1st month to 4th month

MAND: aligned with 16 HA NiTi, then 20steel.
20 steel with O-C spring compressed 6 to 8 mm in order to distalize 33 & 43 first.

5th month

MAND: bracket the incisors and re-level with 16 HA NiTi.

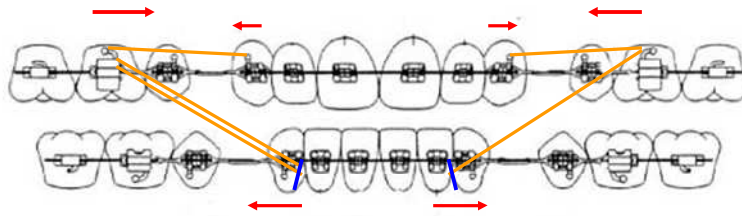


6th month

MAND: 19x25 HA NiTi



7th month



MAX & MAND: 19x25 posted steel wires;

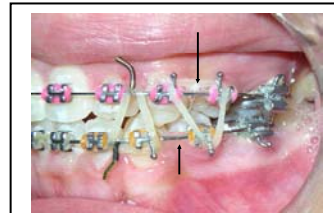
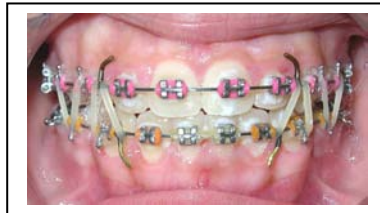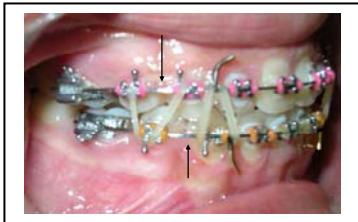CLIII elastics, 8mm, 2 right and 1 left, 24/24 for 6 weeks used to distalize the MAND anterior segment into a CLI position. At the same time this force would mesialize the MAX posterior teeth towards a CLI position.

CLI elastics, 6mm, 24/24 from 16 to 13 & from 26 to 23 in order to distalize the cuspids ~3 mm and also to advance the MAX posterior teeth towards a CLI.

- this set-up would not effect the A-P position of the 4 MAX incisors.

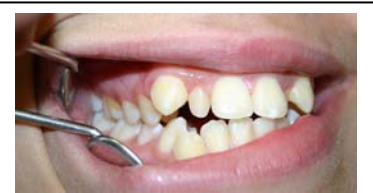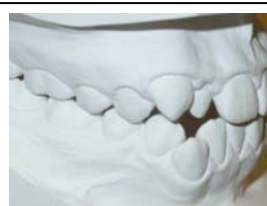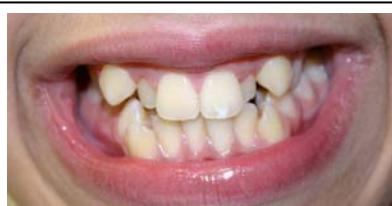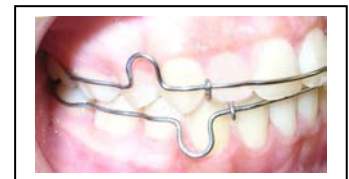
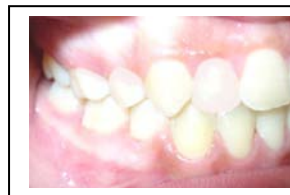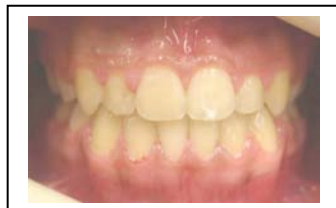15th month:

final finishing: Wires are "sectioned" (cut) distal to the cuspids; 4 mm delta elastics, 24/24, are used to settle-in the occlusion for 2 weeks



16th month:

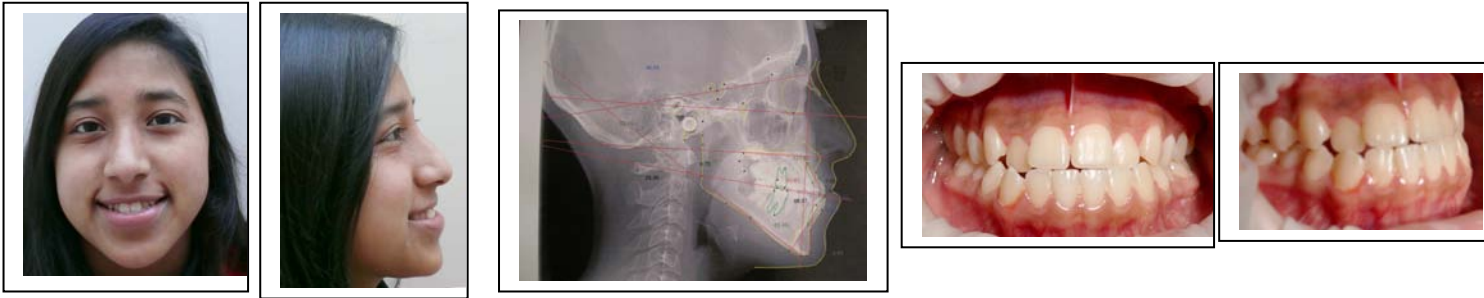
remove braces; fixed and removable retention appliances are made. "Before and after" photos



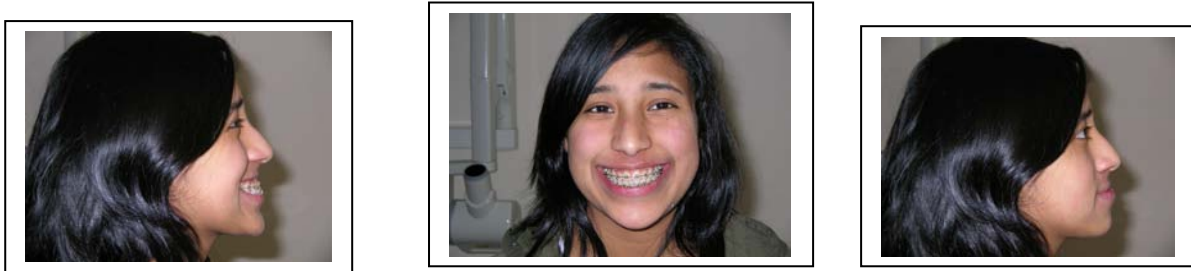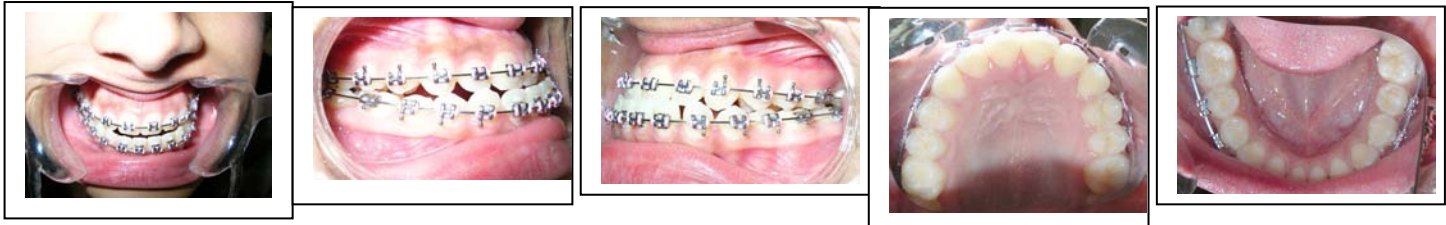
Sometimes the best results can only be obtained with orthognathic surgery combined with orthodontics.

At any rate, the patient must always be explained **all** the potential options and alternatives for treatment, as well as the possible complications. It is for this reason that practitioners today need to have an good understanding of modern-day orthodontics.

For cases with very severe skeletal problems in which **orthognathic surgery** is obviously needed for an acceptable result, the SWA is an ideal and easy to use system for preparation of the occlusion before orthognathic surgeries, such as mandibular retraction and/or a surgical maxillary advancement with or without vertical maxillary impaction. The SWA is left in place during the surgeries and hooks on the wires of the SWA are used by the surgeon to help fix the jaws in their new positions.



6th month: After leveling (all the teeth are bracketed); 21x25 steel wires are in place already for 2 months. The dental arches are "coordinated" in shape so that the maxillary arch can contain the mandibular arch in a CLI position. The CLIII Look is temporarily worsened. *Patient is scheduled for surgery in 2 months.*



2 months after the surgery (Le Fort I maxillary skeletal advancement to correct the CLIII): 19x25 steel wires are in place and are segmented at the "arrows" to allow each segment to settle separately using 4mm delta elastics that are worn for 2 weeks, 24/24.

