

DR. LARRY BROWN

Art of
MODERN
ORTHODONTICS



CONTENTS

Chapter 1 *p 23*

- The Straight Wire Appliance (SWA) explained *p 23*
- Bracketing explained *p 25*
- Molar banding and separators *p 38*
- The auxiliaries of the SWA *p 43*

Chapter 2 *p 49*

- Workshop 1: the correct procedures and mechanical techniques for the following:
 - Bracketing *p 49*
 - Banding *p 54*
- Workshop 2: *p 55*
 - Use of the Nickel-Titanium (NiTi) Heat Activated (HA) levelling archwires *p 55*
 - Placing the basic SWA auxiliaries *p 56*

Chapter 3 *p 59*

- Orthodontic theories on human growth and physical development *p 59*
- Phases of development for the maxilo-mandibular and facial complex *p 59*
- The reasons for malocclusions *p 62*
- Diagnostic and treatment planning, part I *p 64*
- Cephalometric x-ray and cephalometric analysis explained; facial / esthetic analysis *p 66*

Chapter 4 *p 73*

- Workshop 3:
 - The cephalometric tracing
 - Anatomic landmarks, horizontal planes and vertical lines *p 73*
 - The cephalometric analysis *p 75*
 - The tracing and analysis done in a step-by-step manner *p 82*
-

Chapter 5 **p 85**

- Diagnosis and treatment planning, part II *p 85*
 - Step-by-step process of the Classification of the case so that no dental or orthodontic problems are overlooked. *p 85*

Chapter 6 **p 87**

- The “Esthetic Diagnosis”: the final orthodontic treatment plan is based on a combination of the Esthetic diagnosis and the scientific data. *p 87*

Chapter 7 **p 93**

- Diagnosis and treatment planning, part III
 - Growth Modification vs Extraction *p 93*
 - Treatment modalities for Growth Modification *p 94*
 - Guidelines for the treatment of different Age Groups: primary dentition, mixed dentition, adolescent and adult dentitions. *p 95*

Chapter 8 **p 99**

- The effect of breathing and soft tissue dysfunctions on the growth and development of the face, jaws, alveolar bone and teeth *p 99*
- Various exercises that can be used in the treatment of these dysfunctions *p 100*

Chapter 9 **p 101**

- Biomechanics: The biomechanics needed for SWA treatments *p 101*
 - Tooth movement *p 101*
 - Biomechanical force theories *p 102*
 - Archwires and force modules *p 103*
 - Anchorage: horizontal (for space closure) and vertical *p 105*
 - Force systems for molar rotations *p 108*
 - Auxiliary force systems: springs, elastomeric modules, etc. *p 109*
 - Head Gear: Cervical, Combi, Occipital (high-pull) *p 110*
 - NiTi CLII Corrector (fixed functional appliance for CLII correction: is fixed to the SWA) *p 113*

Chapter 10 *p 115*

- Elastic Forces: the elastic forces used for SWA treatments
 - Biomechanics and force principles of elastic forces *p 115*
 - Biomechanics and mechanics
 - CLI force *p 116*
 - Force Modules *p 118*
 - CLII force *p 119*
 - CLIII force *p 121*
- Elastic combinations for different situations and phases of treatment
 - “Special” inter-maxillary elastics such as bite closing, finishing, etc. *p 124*
 - Forces for midline corrections *p 126*

Chapter 11 *p 127*

- Workshop 4: the proper techniques for the following:
 - The use and the manipulation (torque, de-torque, accentuated curve) of the 19x25 and 21x25 steel wires: the “Working” wires *p 127*
 - Placing elastic forces: intra-oral elastics, NiTi closed coil spring *p 128*

Chapter 12 *p 129*

- Workshop 5: fabricating the 16x22 Beta-titanium (Beta-ti) intrusion wire
 - The intrusion wire used for bite opening with incisor intrusion in mixed dentition cases *p 129*
 - The anti-tongue fixed appliance *p 131*

Chapter 13 *p 133*

- Workshop 6: the fabrication and use of:
 - 16x16 steel or 16x22 Beta-ti Utility Arch Wire (UAW) *p 133*
 - 17x25 pre-formed NiTi Reverse Curve of Spee wire (RCS) *p 137*

Chapter 14 *p 139*

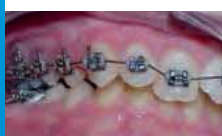- Workshop 7:
 - The HA NiTi Transpalatal Expander and the HA NiTi Transpalatal Molar Rotator *p 139*
 - Introduction in the use of the HA NiTi Transpalatal expansion appliances *p 141*

Chapter 15 *p 147*

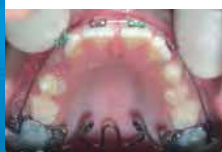- Clinical cases: The diagnosis and treatment protocol for the system of Dr. Larry Brown

Chapter 16 *p 149*

- Clinical CASES: CLII, non-extraction: Mixed dentition and adolescent.



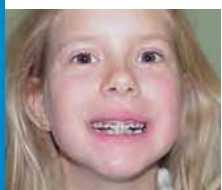1. Case: JP, boy, 12.5 years old. TP (Treatment Plan): Use of bite opening RCS wires, asymmetric CLII elastics and oblique elastic to treat an asymmetric CLII div II with deep bite. *p 149*



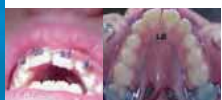2. Case: Ea, female, age 10 years 8 months. TP: CLII div I malocclusion treated with the NiTi transpalatal Rotator and 16x22 Beta-ti and RCS intrusion / bite-opening wires. *p 161*



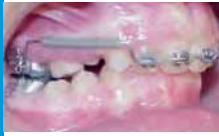3. Case: Mi, female, dental age 10.5. TP: Use of NiTi Expander to: correct $\frac{3}{4}$ CLII molar, gain 6 mm of space for 13, gain space to be able to shift the maxillary M-L 2 mm to the left (need 2mm of space on left side to correct). No CLII elastics were used in the treatment. *p 167*



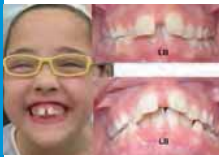4. Case: Le, female, dental age 11. TP: Use of the HA NiTi Expander, an intra-oral molar distalizer using a lock-stop with compressed O-C spring, and CLII elastics to correct: CLII molar with open-bite tendency, unilateral X-bite with mandibular slide, deviation of both midlines, and the lack of space (13mm) in the maxillary arch and 6 in the mandibular. Use of delta elastics for final bite settling. *p 170*



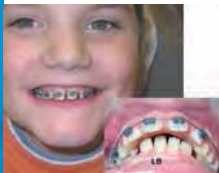5. Case: Se, female, Dental age 10. "Two Phase" treatment. Use of NiTi Transpalatal Expander: to correct a severe CLII div I with OJ of 15 mm, anterior open bite and soft tissue dysfunction. Using the UAW to gain 8 to 10 mm of space for 33, 43. *p 191*



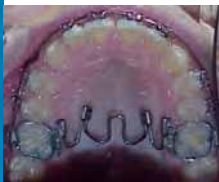6. Case: Ke, female, 12 years old, dental age 11.5. CLII div II. OB = 10 mm. Deep CoS (4 mm). TP: Maxillary 1st molar distal rotation and arch expansion using a TPA (HA NiTi Rotator) and wires; use of the 16x22 Beta-ti and RCS intrusion wires for bite opening; use of High-pull HG and the TPA to provide vertical anchorage to the maxillary posterior segment and for maxillary Growth Modification. Use of CLII asymmetric elastics for the final corrections of the CLII malocclusion, mandibular midline, and final bite opening. Use of delta elastics to settle-in the occlusion. *p 199*



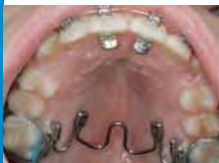7. Case: Ki, girl, dental age 10. Full CLII div I dental and skeletal. TP: use of the NiTi Expander and 16x22 Beta-ti intrusion wires in the treatment of a severe CLII div I with deep bite, a 15 mm OJ and soft tissue dysfunctions. *p 218*



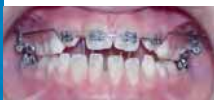8. Case: Ls, boy, age 12 years, dental Age 11 years. TP: Use of the NiTi Transpalatal Rotator, RCS NiTi wires and asymmetric CLII elastics to correct a severe CLII div I, OJ = 12 mm, OB = 6 mm and soft tissue dysfunctions. *p 226*



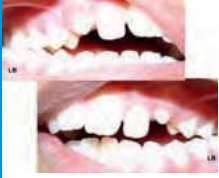9. Case: Mn, boy, 11.5 dental years old (13 chronological age.) TP: Use of NiTi Rotator, 16x22 Beta-ti and 17x25 RCS intrusion wires, High-pull Head Gear and asymmetric CLII elastics for the treatment of: Full CLII div II, severe OB = 9 mm, OJ = 5 mm, very deep CoS, gummy smile, maxillary vertical excess. *p 232*



10. Cases: 6 cases with different problems demonstrating the use of [Bite Ramps](#) combined with the SWA and its auxiliaries. Discussion on so called “self-ligating bracket systems”. *p 238*



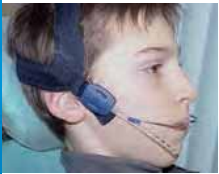11. Case: K, female, 10 years old. TP: Use of NiTi transpalatal appliance, mandibular fixed lingual anti-tongue thrust appliance, maxillary 16x16 steel “extrusion wire”, CLII and box elastics to treat: CLII div I with anterior incisor flaring, anterior open bite of 4mm and severe soft-tissue dysfunctions. *p 251*



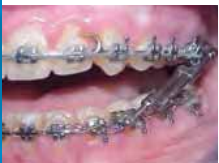12. Case: Ma, female, age 13. TP: The use of the SWA, CLII elastics and box and delta bite closing elastics to treat: CLII div I, 12 mm OJ, 4 mm anterior open bite, and soft tissue dysfunctions that occur during swallowing and speaking. Use of finishing Step-bends to create additional anterior overbite. *p 257*



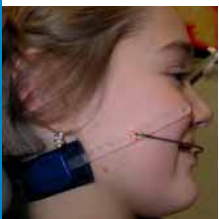13. Case: Na, female, 13 years old. TP: Use of High-pull HG, "auxiliary 16x22 *extrusion wire*", fixed lingual arch anti-tongue appliance and bite-closing elastics to treat: CLII skeletal, soft tissue dysfunctions, 6 mm anterior and posterior open bite, tongue habit with soft tissue dysfunctions, a vertical growth pattern with a steep MPA and a convex profile. *p 265*



14. Case: Pr, boy, 11.5 years old. TP: use of NiTi Transpalatal appliance, High-pull HG, NiTi CLII Corrector (a fixed functional appliance) and elastics to treat: CLII div I, maxillary vertical excess, OJ = 10 mm, OB = 6 mm, dolichocephalic, long face vertical growth pattern, convex profile, high MPA (46°) and soft tissue dysfunctions. Treatment of an impacted canine. Delta elastics for final occlusal interdigitation. *p 271*



15. Case: Do, boy, 12 dental years old. TP: Use of Transpalatal NiTi Expander, high-pull HG, NiTi CLII Corrector and elastics to treat: Full CLII div I, OB = 6 mm, OJ = 12 mm, convex profile, severely narrow palate with Vertical Maxillary Excess, and strong dysfunctional habits. *p 292*



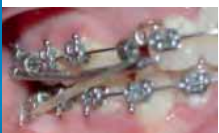16. Cases: [10 cases](#) demonstrating Maxillary 1st Molar Distalization (distalization of the 1st molar before the 2nd molar erupts). *p 309*

Extra-oral:

- Cervical and Combi Head Gear. *p 309–326*

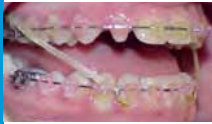Intra-oral:

- Sliding Yoke combined with CLII elastics. *p 327*
- Various laboratory intra-oral appliances. *p 338*
- "Mini-screw distalizer system": using mini-screws to provide "anterior anchorage" against the reactionary forces of a compressed (using lock-stops) +300 gr O-C spring. *p 340*
- Lock-stop with compressed O-C spring. Use of CLII elastics for "anterior anchorage". *p 345*

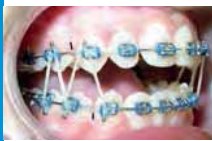

Chapter 17 p 351

CASES: CLIII non-extraction: mixed dentition and adolescent.



1. Case: JI, female, dental Age 11. TP: the SWA, 16x16 UAW, and CLIII elastics to treat: CLIII skeletal growth pattern: Wits = -4. p 351

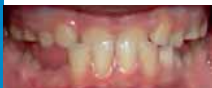

2. Case: Mk, boy, 13.3 years old, dental age ~11.5. TP: Use of SWA with archwire expansion, O-C springs, CLII elastics, and delta elastics for bite settling to correct: CLIII with unilateral X-bite due to a mandibular slide to the right. Correction of the maxillary midline that is shifted to the left. p 359



3. Case: Jn, boy, age 13 years. TP: use of NiTi Expander and CLIII elastics to resolve *non-extraction*: The severe CLIII skeletal/dental, with bilateral posterior and anterior x-bite, due to a previous orthodontic treatment that was improperly done. Use of the mandibular 19x25 NiTi wire with 20° lingual crown torque to aid in resolving the problem of hyper labially-tipped incisors. Re-bracketing used for final occlusal finishing. p 364

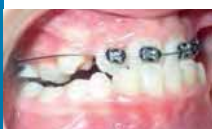4. [Workshop 8: Expansion wire](#) used to correct CLIII X-bites. p 370



5. Case: Sr, boy, dental Age 10.8. TP: Use of a 16x22 Beta-ti expansion wire in a 2x4 situation to correct an anterior (CLIII) X-bite in a case with a "functional" CLIII due to dental interferences. p 371



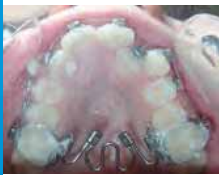6. Case: Bt, male, age 14 years, dental age 12. TP: Use of a steel expansion wire, X-elastics, CLIII and bite closing elastics to correct: a unilateral X-bite due to a mandibular slide, posterior and anterior X-bite, the CLIII dental and skeletal occlusion and the lower midline. Profile problem: the upper lip is flat and the lower lip is too prominent. Thus, must develop/enlarge the maxillary arch in all directions and reduce the prominence of the mandibular arch. p 378



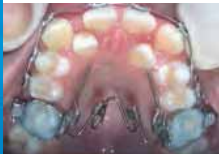7. Case: Tm, boy, 11 dental years old. Example of a "set-up" using HA NiTi Expander, wires and lock-stops to correct a CLIII (mandibular slide) with bilateral posterior and anterior cross-bites. p 389



8. Case: Ad, female, dental age 11. Skeletal functional problem: mandibular slide causing an A-P (functional) problem. TP: Maxillary 16x22 Beta-ti expansion wire. Distalization of the mandibular teeth into existing natural spaces in order to correct the CLIII dental and skeletal anterior X-bite using CLI space closure techniques (like a mini-extraction case). *p 390*



9. Case: Boy, age 13. TP: The NiTi transpalatal Expander is used for the following reasons: the “regaining” of significant space is indicated (maxillary arch: 14 mm); to correct a CLIII (with posterior and anterior X-bites) due to a significant mandibular slide; the palate is narrowed and V-shaped; the maxillary molars are severely rotated meso-lingually; there is a need to vertically stabilize the maxillary arch. *p 394*



10. TP: Use of the NiTi Expander, archwires, O-C springs, CLIII and oblique elastics to correct: CLIII skeletal/dental with bilateral and anterior X-bites, severe maxillary crowding, “CLIII Look” with a protruded mandible and retruded/underdeveloped maxilla with concave upper lip, and soft tissue dysfunctions. Inverting 180° the maxillary lateral brackets in order to labially torque the roots of the laterals. *p 397*

Chapter 18 *p 403*

Anchorage in space closure when using the SWA.

- Optimal forces *p 403*
- Different anchorage situations *p 403*
- Methods to control anchorage *p 404*

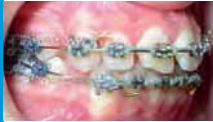Chapter 19 *p 407*

Extraction treatments: Space closure and tooth movement using sliding mechanics.

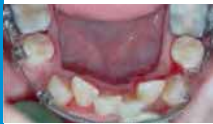- Levelling considerations *p 407*
- Forces used for space closure *p 408*
- Different anchorage situations and the variations thereof: Moderate, Maximum, Minimum *p 409*
- Clinical situations that can occur during space closure *p 410*
- Space closure and tooth movement in non-extraction cases *p 412*

Chapter 20 **p 413**

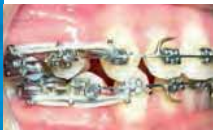CASES: Extraction treatments: diagnosis and space closure mechanics in CLI and CLII cases.



1. Case: Rf, boy, age 13 years. TP: *4 premolar extraction treatment using en masse, reciprocal, CLI space closure* (200gr NiTi coil springs) to treat an esthetic problem: “teeth too far forward” (protrusive) with BIPRO look, convex profile, slightly elevated MPA. Functionally the patient does not have proper lip closure (forces lips closed). *p 413*



2. Case: Adult. *Maximum anchorage*. TP: treatment using O-C springs (010x030) to push cuspids distally. The distalizing forces from these springs push the cuspids toward their final positions, and as there are no mesial forces on the posterior segments, there is maximum posterior anchorage. *p 420*



3. Case: Aa, female, 15 years old, CLI occlusion. TP: 4 premolar extraction treatment, *moderate anchorage becoming maximum anchorage* (cuspid first distalization followed by en masse distalization of the incisor segment) to correct: the facial esthetics (convex profile, high MPA with BIPRO look due to protrusion and crowding of the anterior segments). Use of re-bracketing for final finishing. *p 424*



4. Case: Ge, young adult female, 14 years old. CLI, crowding, high MPA, BIPRO look with convex profile. TP: *Maximum anchorage* using CLI forces for cuspid first distalization followed by CLII en masse retraction of the maxillary incisor segment. Use of re-bracketing for final finishing. *p 432*



5. Case: Female, 12.5 years old; dental age 11.5 years. CLI dental and skeletal with agenesis of 41 & 31. TP: *Minimum anchorage mechanics* to advance the mandibular posterior teeth using a combination of: lock-stops with compressed O-C springs, CLI and CLII elastics and 200gr NiTi closing springs. *p 440*

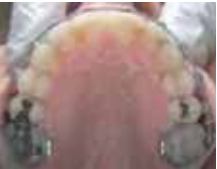
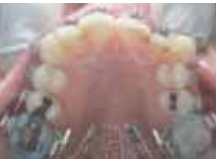
6. Case: Mo, adult female, CLI with crowding. TP: *moderate anchorage is changed to minimum anchorage*: CLI forces are used to “advance first” the 2nd premolars, then after they are advanced, the molars are advanced – all without distalizing the anterior segments. Occlusal inter-digitation using delta elastics. *p 451*

7. *Orthodontic Camouflage and Orthognathic Surgery* *p 457*
 - Camouflage CLII *p 457*
 - Camouflage CLIII *p 459*
 - Orthodontics combined with surgery. *p 461*



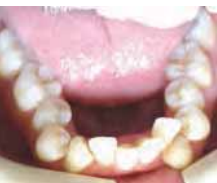8. Case: Pa, adult female, CLII dental and skeletal. This case describes the limits of *non-extraction camouflage CLII* orthodontic treatments in non-growing patients. Use of “Short CLII elastics”. p 464



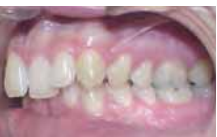9. Case: Ae, adult female, CLII dental/skeletal. The use of the HA transpalatal appliance to disto-rotate and distalize the maxillary 1st molars in *the correction, non-extraction, of an adult CLII malocclusion*. p 469



10. Case: Pe, adult female, Full CLII occlusion, Wits +6. TP: *Camouflage CLII extraction therapy* (extraction of 2 maxillary premolars). Levelling with RCS intrusion wires to reduce the “gummy smile”. Space closure combines CLI and CLII forces. Composite veneers used on undersized maxillary laterals. 19x25 NiTi wire with 20° additional torque used for additional labial crown torque to the maxillary incisors. Use of re-bracketing for final finishing. p 472



11. Case: Kt, adult female, Full CLII dental/skeletal (Wits +8). TP: *camouflage CLII, extraction of 4 premolars*. Protrusion of maxillary incisors, severe mandibular crowding (20mm). Demonstration of problem solving: imprecise bracketing and mechanics. p 483



12. Case: Je, adult female, 19 years old. Full CLII dental and skeletal (Wits +9), 8 mm OB, 6 mm OJ, deep curve of Spee (4 mm), moderate crowding. TP: *Camouflage CLII extraction therapy*. Use of RCS wires for bite opening with incisor intrusion, sliding yoke for unilateral maxillary molar distalization. CLII elastics for final en masse space closure, midline correction and bite opening. Delta elastics for settling-in the occlusion. p 493



13. Case: Ae, female, 18 years old. TP: Extraction of 3 premolars and 1 molar to correct a dental and skeletal CLII with a BIPRO Look. Problems to solve: *Moderate anchorage becomes minimum anchorage*. Use of mini-screw. Re-bracketing and the use of the 19x25 NiTi wire with additional labial crown torque for final finishing. p 533

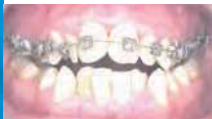

14. Case: Ie, adult female. Patient complains about unsightly smile with crowding. TP: *Camouflage CLII* with extraction of 2 upper premolars to correct: a full CLII skeletal and dental. CLI en masse space closure combined with CLII asymmetric forces. Composite veneers for undersized maxillary laterals. p 542

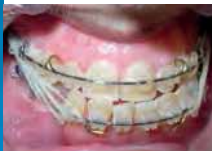

Chapter 21 p 553

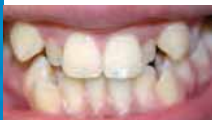CASES: Extraction treatments: diagnosis and space closure mechanics in CLIII cases.



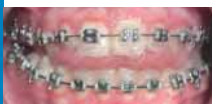1. Case: Pl, adult male, 30 years old. Full CLIII dental (Wits = -6), bilateral posterior and anterior x-bite, crowding, CLIII Look and profile, and anterior open-bite. TP: *CLIII camouflage extraction therapy*. Use of HA NiTi transpalatal Rotator, wires, O-C springs, closing springs and elastics for the treatment of the full CLIII malocclusion. p 553



2. Case: Wy, adult female. Full CLIII with anterior and posterior X-bite, severe crowding. TP: *Camouflage CLIII with unilateral extraction; asymmetric/unilateral space closure*. Use of CLIII and CLI asymmetric forces for en masse distalization of the lower anterior segment and correction of the midlines. CLII, CLIII, oblique and delta elastics for final finishing. p 562



3. Case: Ne, adolescent female, 14 years old. Full CLIII, bilateral X-bite, severe crowding. TP: *camouflage CLIII* with extraction of 4 premolars. BIPRO characteristics. For space closure: use of O-C springs for "cuspid first" distalization (33, 43), and CLI and CLIII forces. Box and delta elastics for closing the open bite. Re-bracketing and delta elastics for finishing. p 573



4. Case: Le, adolescent female, age 13. Full CLIII dental and skeletal (Wits -3.5), anterior open bite (5 to 7mm) with bilateral posterior and anterior X-bite. Mouth breather. Poor lip posture. Tongue interposition. Long face type. TP: *camouflage CLIII* with extraction of 36, 45. Use of archwires with expansion. *CLIII en masse space closure* of the lower anterior segment of 9 teeth. *CLI "minimum anchorage" space closure* to advance lower molars. Box elastics for final closure of the open bite. p 581

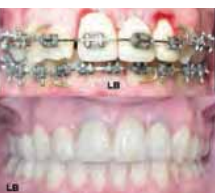Chapter 22 **p 589**

Orthodontic treatment combined with Oral Surgery

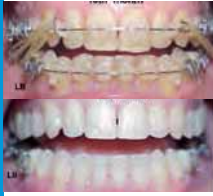- Description of the most common orthognathic surgeries used today.
 1. The Lefort I down-fracture *p 589*
 2. The BSSO of the mandible *p 593*
 3. The corticotomy of the palate (surgical expansion) *p 598*
 4. The genioplasty *p 599*
- How to differentiate and to diagnose a surgical case from a non-surgical one.
- The handling of surgical orthodontic cases (these cases are treated differently than routine orthodontic cases): What may be a simple GM treatment in a young patient becomes a surgical case in adults.
- Maxilo-facial surgeries are combined with orthodontics to treat severe dento-facial problems of any type.
- Surgical treatment is for those orthodontic problems that are so severe that neither Growth Modification nor camouflage extraction therapy offers an acceptable dental, occlusal and esthetic solution.
- Surgery is used to correct skeletal problems of the jaws and/or problems of the dento-alveolar segments.
- Both jaws and the chin can be repositioned in all 3 planes of space.
- **Diagnosis and Treatment planning.**
- **Pre-surgical orthodontic treatment.**
- **The surgical procedure.**
- **The post-surgical orthodontic treatment and finishing.**

Chapter 23 **p 601**

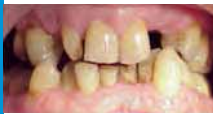└ The following 3 cases demonstrate the use of orthodontics in preparing a patient before prosthetic and esthetic restorations. They demonstrate the use of orthodontics to correct a malocclusion beforehand in order to prepare an optimal occlusal base. Without this, the restorative treatment would be compromised to the extent that it would be impossible to have a pleasing esthetic result along with an acceptable occlusion.



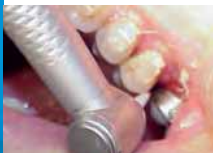1. Case: La, adult female. Full CLII div I, Wits +6, OJ = 9 mm, OB = 5 mm, deep CoS. X-bite 16 & 17. TP: Patient would like to replace the fixed bridge from 11 to 22 and have made a porcelain veneer on 12. *Camouflage CLII extraction treatment* will be completed first to correct the OB & OJ and to create space in the anterior segment such that the crowns can be made larger and more attractive. En masse asymmetric space closure using CLI closing springs and CLII elastics. Tooth whitening. New porcelain bridge 11 to 22 and a porcelain veneer on 12. *p 601*



2. Case: Ce, adult female. CLI skeletal, slight crowding, missing molars (36 & 46), mesially inclined molars (37, 38, 47, 48), super-erupted molars (16 & 26). TP: improve the smile and occlusion with orthodontics so that the missing posterior teeth can be properly restored with implants or bridges. Use of the SWA, wires and elastics. Bracketing technics to improve the Smile esthetics; tooth whitening. *p 607*



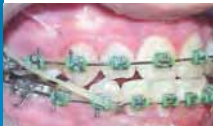3. Case: Js, adult. CLIII with severe crowding and severely worn down teeth. After extraction of 2 lower teeth, the arches will be leveled in order to correct the CLIII malocclusion. After, the maxillary arch will be restored (bridges and crowns on all the teeth) and then the mandibular arch (crowns and veneers on the front 6 to 8 teeth) to support the new occlusion and for esthetic reasons. *p 616*



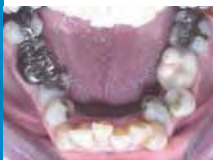Chapter 24 *p 621*

Stripping and Air Rotor Slicing. These procedures are used to gain small amounts of space as needed in various dental arch segments/quadrants to alleviate minor crowding, to camouflage a small CLII or CLIII skeletal/dental problem or to correct midlines. Slicing can be used in place of premolar extractions as a conservative space gaining method.

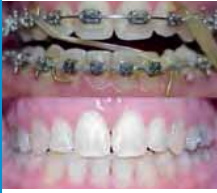The following 3 Cases demonstrate the protocol for Slicing and Stripping. *p 624*



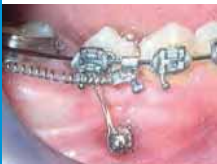1. Case: Nk, adolescent male, 13.5 years old. Bilateral posterior dental X-bite. 1/2 CLIII dental with severe crowding. TP: CLIII malocclusion will be treated with slicing and CLIII elastics. Use of delta and box elastics for bite settling. *p 624*



2. Case: Re, adult, CLII dental & skeletal (Wits +8). Severe crowding, deep CoS, super-erupted lower incisors. CLII profile with retruded chin. Patient would like "esthetic dentistry": recommended orthodontics beforehand and then the patient could have a much superior Esthetic Dental treatment. TP: extract 2 lower teeth (to relieve 19 mm crowding). Space closure by compressed O-C springs. Slicing of the maxillary left quadrant to provide space for the correction of the midline and CLII canine. Use of CLI and CLII elastics for space closure and to correct the CLII occlusion and the midlines. *p 636*

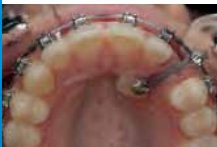

3. Case: Ae, adult. Skeletal CLI. Moderate to severe crowding. Anterior open bite tendency. Cross bite 12. Missing 14, 24 and 32 (extracted for a previous "orthodontic treatment"). TP: teeth straightened for a nicer smile. Slicing will be used to solve the problems created by the previous extractions so as to obtain a more optimal occlusion. 33 will be sliced and reshaped as 32, and 34 will become 33, etc. Use of unilateral CLII elastic combined with an oblique elastic. *p 649*



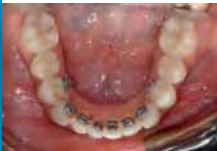Chapter 25 *p 663*

Mini-screws: an overview of the uses of mini-screws (TADs).



Chapter 26 *p 681*

Impacted teeth: an overview of impacted teeth (7 different cases).



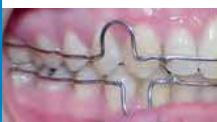Chapter 27 *p 691*

Lingual orthodontics: 2-D, Simplified Lingual technique. An affordable system that can be used to align mild to moderately crowded anterior segments. Use of indirect bracketing that can be prepared by the doctor and/or the staff in the office.



Chapter 28 *p 697*

Finishing bends: Step-up/step-down. Step-in/Step-out. Bends can be made in HA NiTi wires using step pliers that are available in various size steps from 0.25 mm to 3 mm.

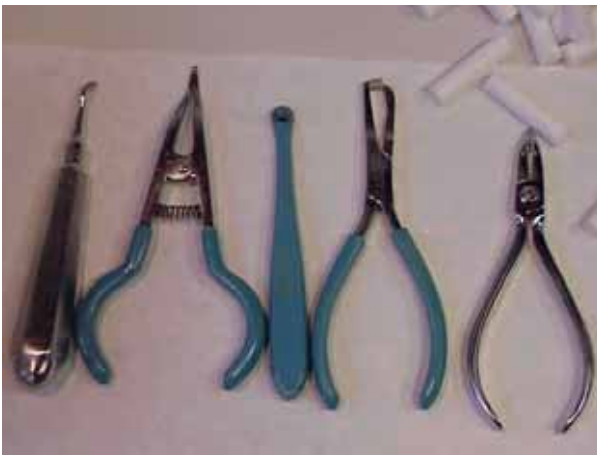

Chapter 29 *p 699*

Removing the SWA, finishing and polishing the teeth surfaces, placing fixed lingual wires and removable Hawley retainers.

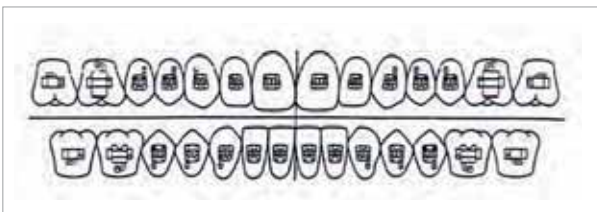


Etch; Composite and primer; Cold spray; Brackets; Study models.



Banding

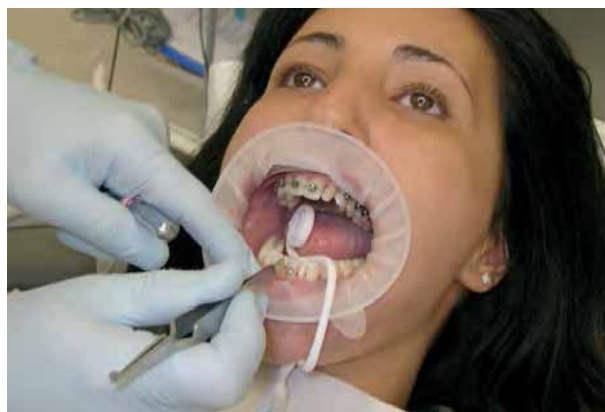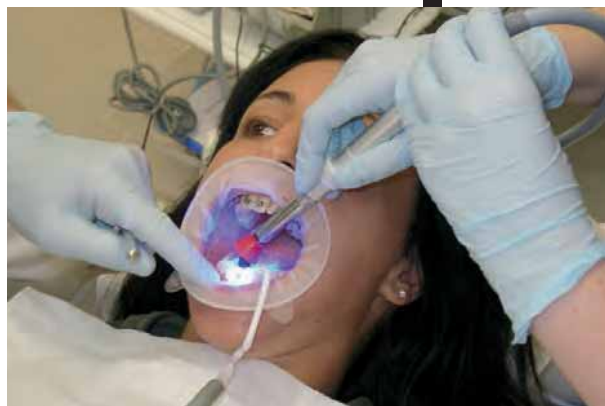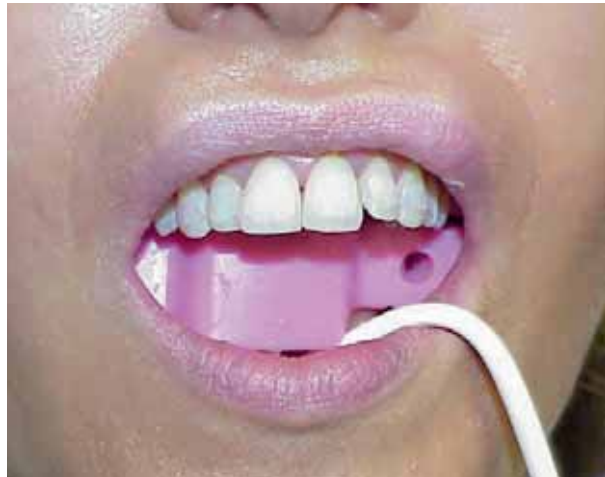
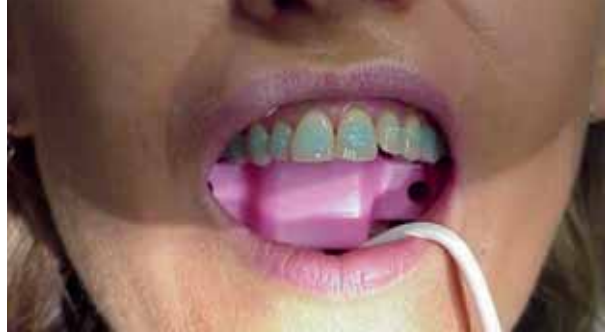1. Heavy band pusher
2. Separating pliers
3. Band biter
4. Band removing pliers
5. Weinghardt pliers

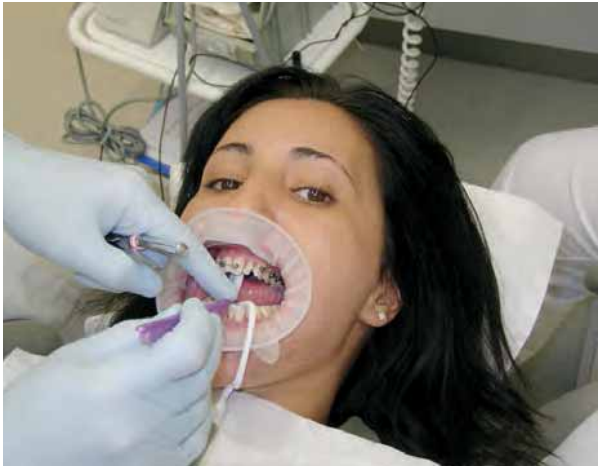

Since many cases are started in the mixed dentition, often only 4 incisors are bracketed and 2 molars are banded (“2 by 4 set-up”) in each arch (depending on the age and development of the patient). It is important that the incisors are bonded on the LA point. As the other teeth erupt fully later on, then these are bracketed at the correct height in relationship to the incisors.

THE PROCEDURE

First polish the teeth, then etch 30–60 seconds, then rinse. Do not let saliva touch the teeth after rinsing and drying.





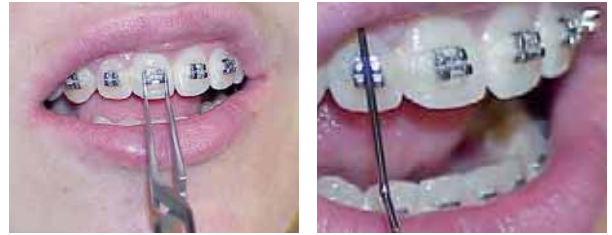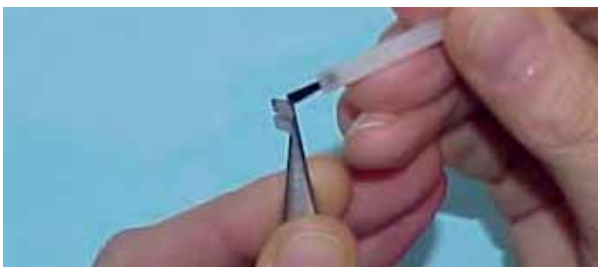Set up the necessary brackets on the special “sticky pad”. The gingival edge/side is on the top for the maxillary and on the bottom for the mandibular.



Squeeze the lower part of the handle of the bracket holder/tweezer to grab and release the bracket.



Squeeze the upper part of the handle while placing the bonding material.



Place the bracket using the tweezers, then align with a bracket aligning instrument.

Bracket Height Gauge

- Measure the length of the clinical crown.
- To start, place a bracket on the LA point of a central Incisor. The tie wings must straddle the LACC equally so as to “sit on the LACC like a saddle on the back of a horse”.
- Then take the Height Gauge to position the bracket at the desired height. This instrument can be used on the anterior teeth and the premolars.

- There are 4 different heights indicated on the instrument.

Example : if the length of the tooth is 8 mm, then the center of the bracket (the slot point) is sited at 4 mm on the LACC, and the side of the height gauge marked 4 is used for this.

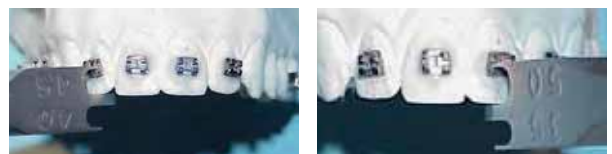- The instrument is constructed so that the thin blade part can fit perfectly in the horizontal slot of the bracket in order to hold the bracket against the tooth surface.

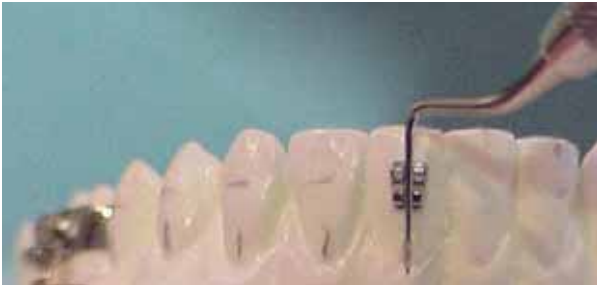
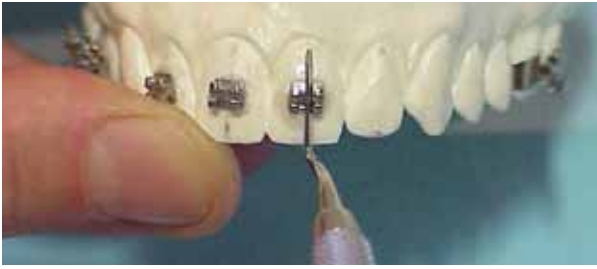
The longer central part is placed on the incisal edge or on the cusp tip of the tooth with the handle parallel to the occlusal plane. Like this the bracket is positioned at the correct height.

For height consistency: Very important – **The handle is always oriented parallel to the occlusal plane.**

The handle is always oriented parallel to the occlusal plane for all teeth. If this is not done, the bracket heights from front to back in the arch will not be correct and true leveling will not be possible.

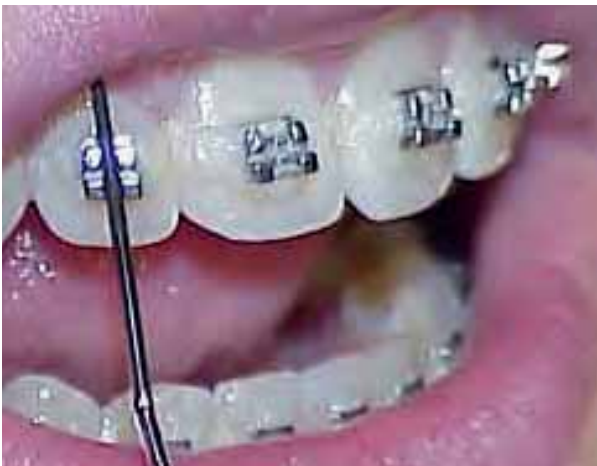



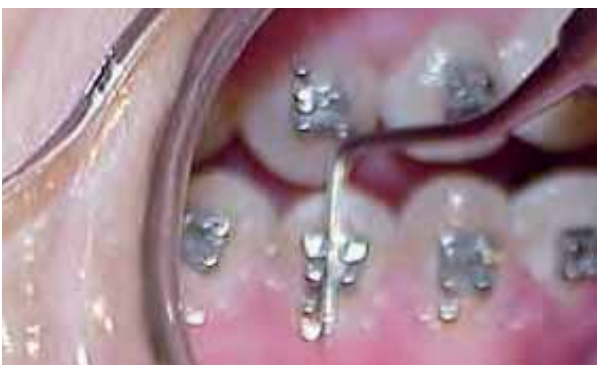- Then the bracket is aligned on the LACC with an aligning instrument or a periodontal probe.

Only align the bracket on the LACC with this instrument and not with the height gauge, which is used to find the height only.

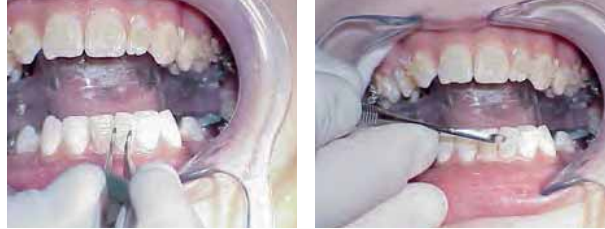
- Now continue with the other teeth.



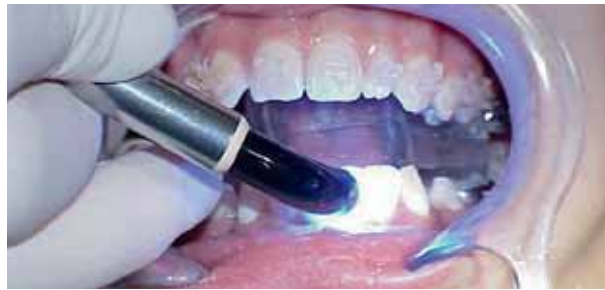One must site up or down from the incisal and occlusal view either directly or with a mirror, especially with the premolars/bicuspids.



A “bonding enhancer” (silane) can be used for the metal posterior brackets and for porcelain brackets.



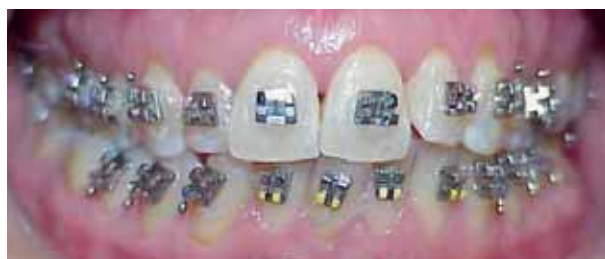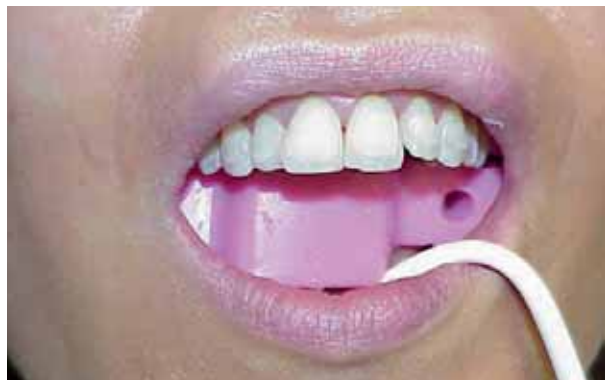Always use special orthodontic light-cure, non-mix composites for bonding of the brackets/tubes. The composite is made so that it will cure “under” metal brackets.



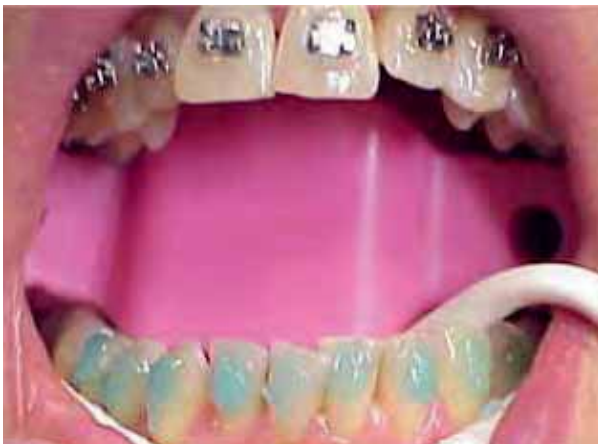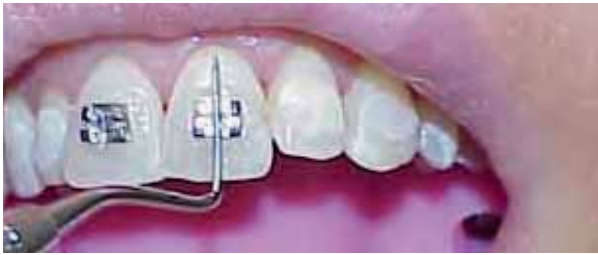After etching, rinse, dry and do not let saliva touch the teeth again or there will be contamination and the brackets will come loose.

After etching and drying, bond the 2 maxillary centrals first. Then the 2 laterals. Make sure they are properly placed in relation to the LA point and to each other.

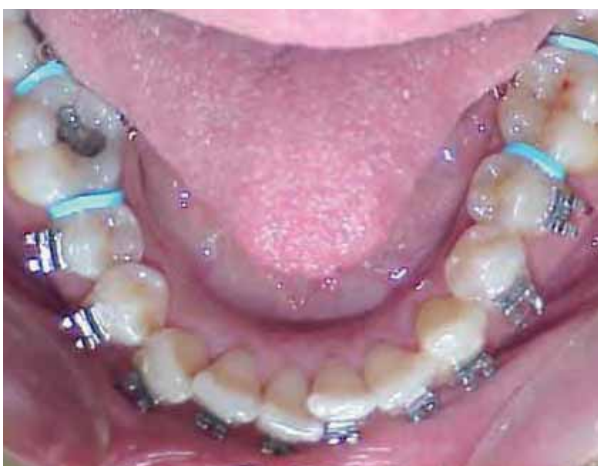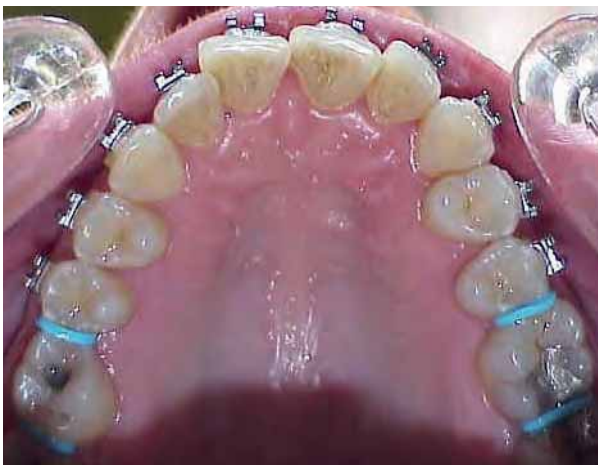Then do the right side: cuspid, 1st premolar, 2nd premolar. Their heights are set in relation to the central incisors and each other. Then do the left side. The same visit or at a later date, the lowers are bracketed in the same manner.



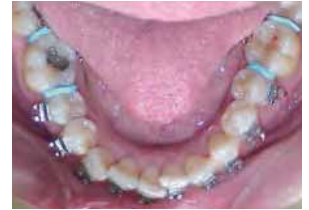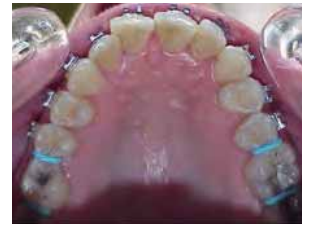Use an instrument to align the bracket on the LACC.



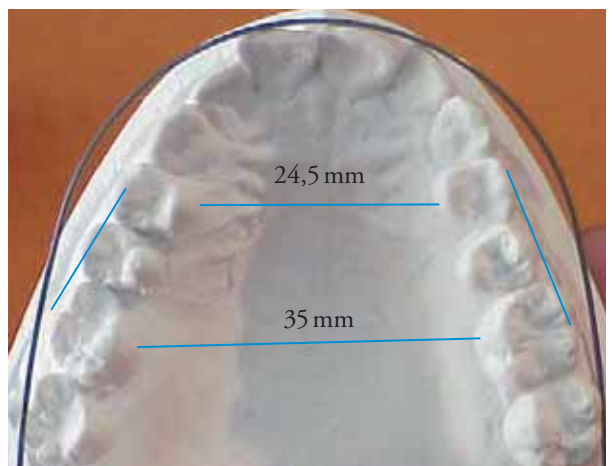
When siting the brackets, always look “down the developmental ridge” from the occlusal side using a mirror.



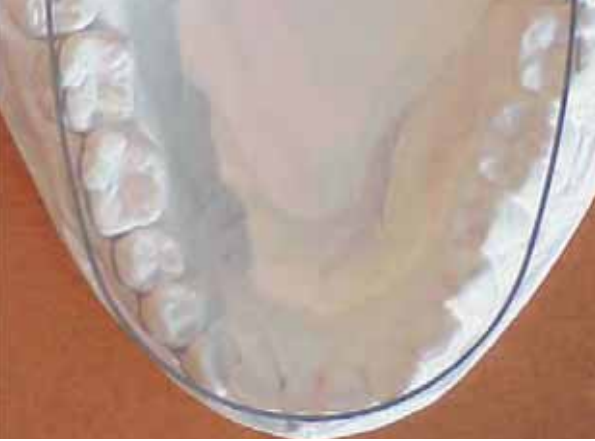Separating pliers with elastomeric separators. ♡



The arch wires are pre-formed (shape was developed as a result of the studies of Dr. Andrews and Roth). The U&L shapes are coordinated to enable the maxillary arch to contain the mandibular in a Super CLI finish.

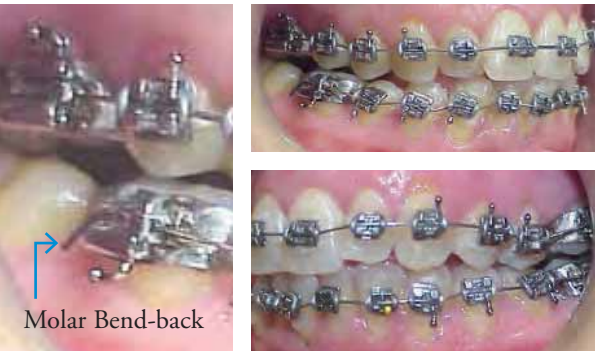
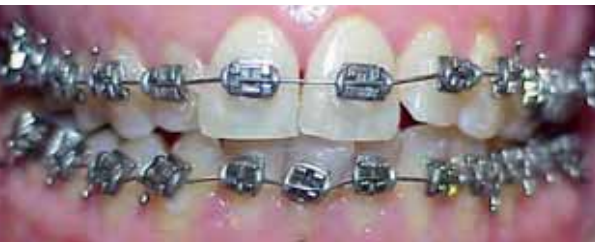
If the natural arch form is larger than this pre-formed wire size, then a larger pre-formed size can be used, or wires that are formable (certain NiTi and steel) can be expanded and used. This does not happen often.




The wire is placed through the molar tube/slot and then tied into the bracket slots with “elastomeric” ligature ties. Metal ties are used in some circumstances.


Make sure to cut off the “distal-end” of the wire.



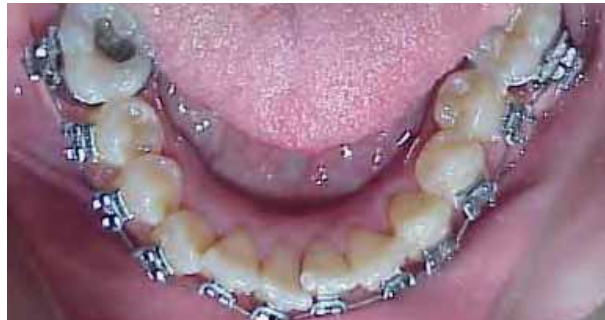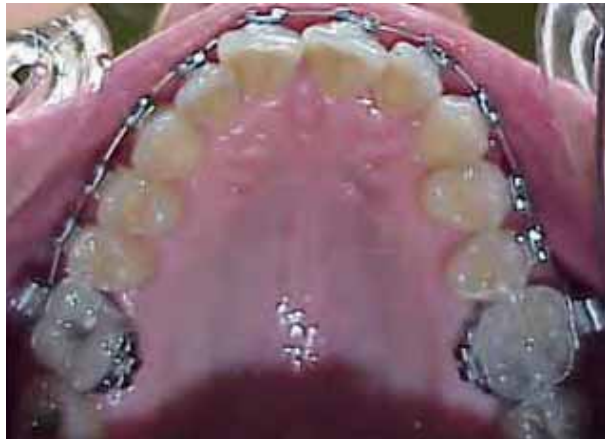Weingardt Pliers: used to place and remove the wires.



Use the **Distal-End Cutter pliers** to cut off the “distal end” of the wire after the wire is tied-in. The pliers are made to hold onto the cut off piece so it doesn't fall into the throat.



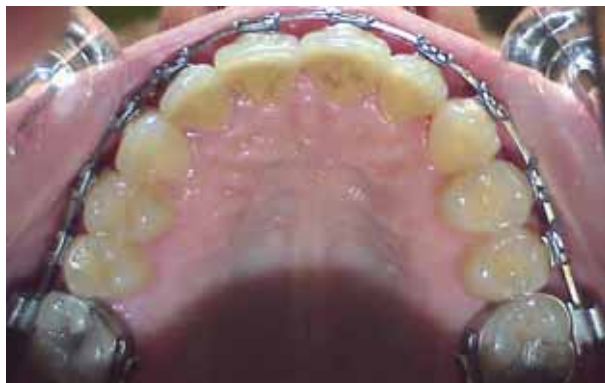16 HA NiTi wires are used as the first wires. These photos show them after they are just tied into the brackets.

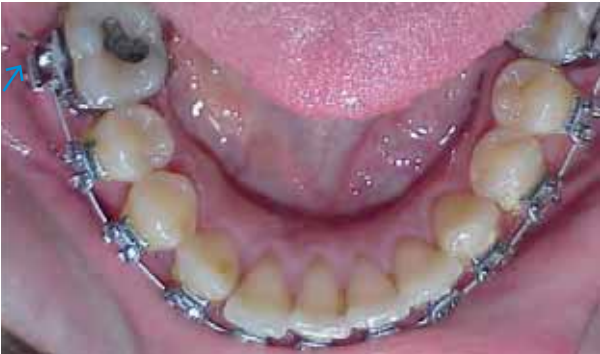

After 3 months of leveling. ♥

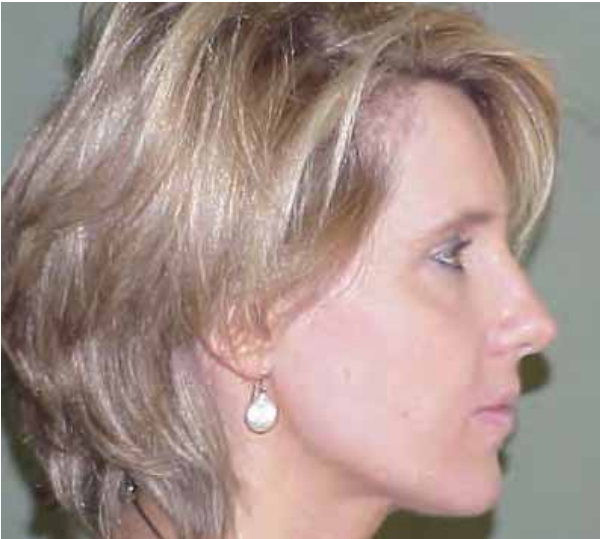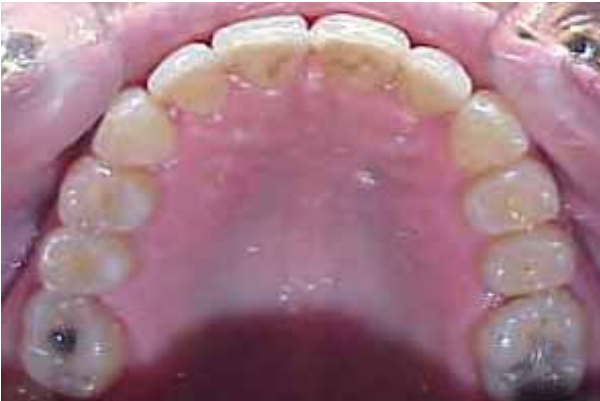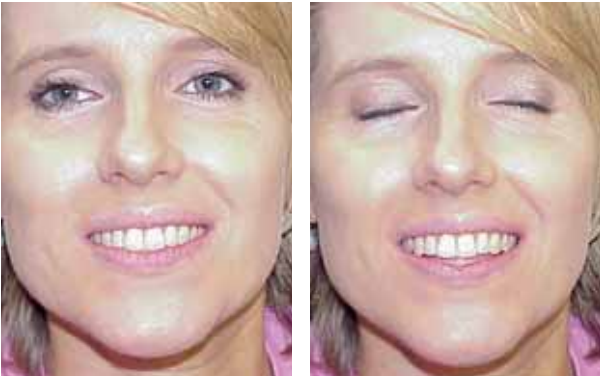MAX: N. 19x25 posted steel.

MAND: 19x25 NiTi, BBs.





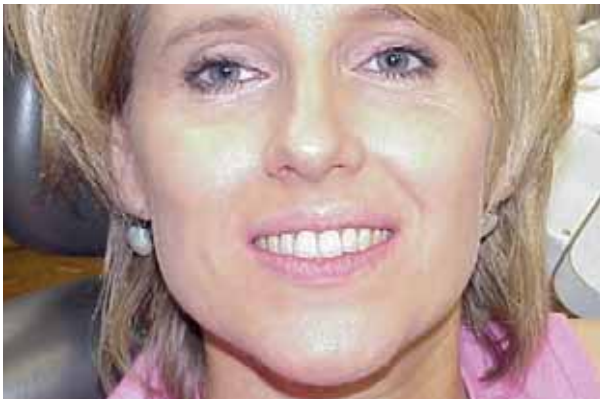Final after 12 months: a non-extraction treatment using slicing and stripping. ♡



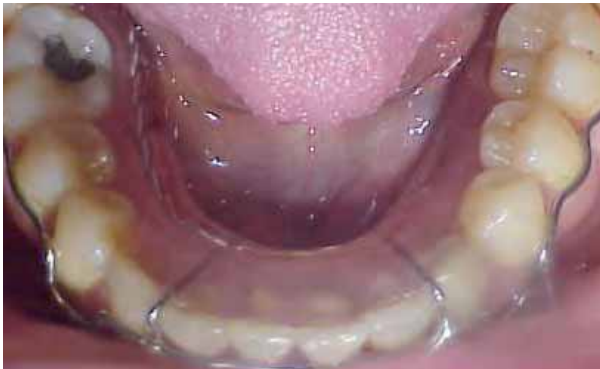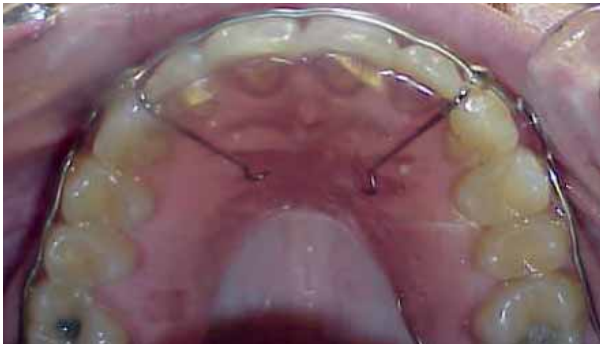Beginning



Final



Hawley Wrap-around removable retainers.

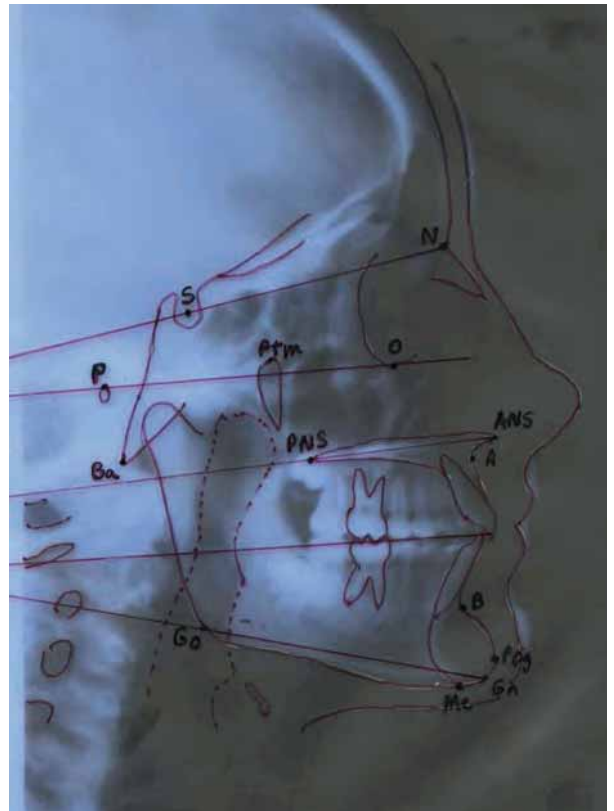
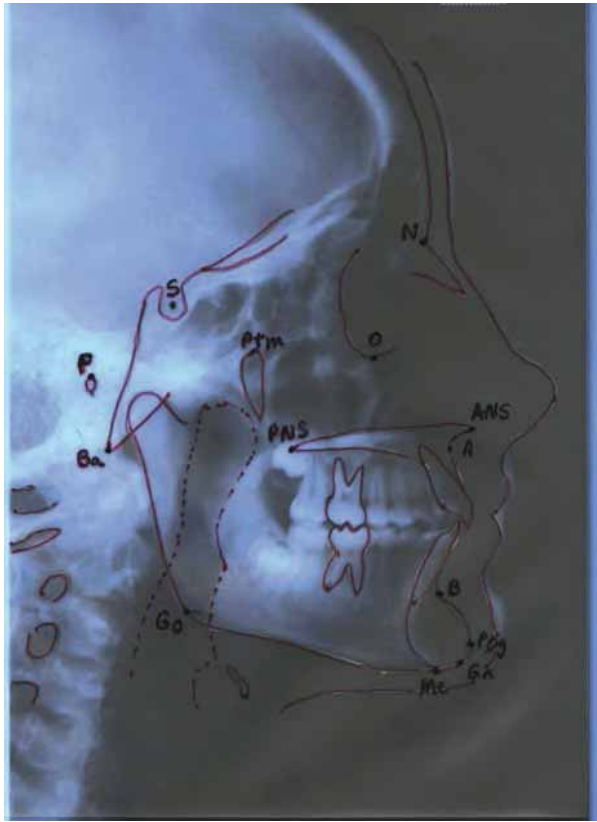


Vertical Lines:	
N-B	Vertical line from N to B . This line relates the mandible to the cranium.
AO to BO (WITS)	Vertical lines drawn from A and B that are 90° to the OP . This evaluates the skeletal relationship of the mandible to the maxilla.
Line +I (MxI) — central incisor	From the tip of the upper incisal edge to the tip of the apex.
Line -I (Mdi) — central incisor	From the tip of the lower incisal edge to the tip of the apex.
Upper facial height to lower facial height:	
Na-ANS	Upper facial height. Adult = 45% to 50%; child = 50% to 50%.
ANS-Me	Lower facial height. Adult = 50% to 55%; child = 50% to 50%.
Y-axis	Draw a line from S to Gn . Measure the angle of SN to S-Gn . This angle gives the position of the mandible in space. Normal is about 64.
A-Pog line	Vertical line that relates the incisor teeth to the jaws. Ideally, the -I(Mdi) should be at +1 to +2 mm. Can be more (for example +3 or +4) in the case of skeletal CLII discrepancies.
SNV	Sub-Nasal Vertical perpendicular – Vertical line at 90° from an absolute horizontal line at the junction of the lip/nose angle. Is used to judge the esthetics of the upper and lower lips. Aids in deciding if teeth can be protruded, should stay where they are, be retracted and/or if extractions are needed. If the lips are too far in front and incompetent, then there may be too much dental and or skeletal protrusion. (See chapter “ <i>Esthetic Diagnosis</i> ”)

Other Planes and Vertical Lines:	
N to Pog	« Facial plane» Vertical line to give an idea as to the skeletal profile.
SN-Pog	The facial angle: how the chin relates to the face.
Ba-Na	Line from Ba to Na .

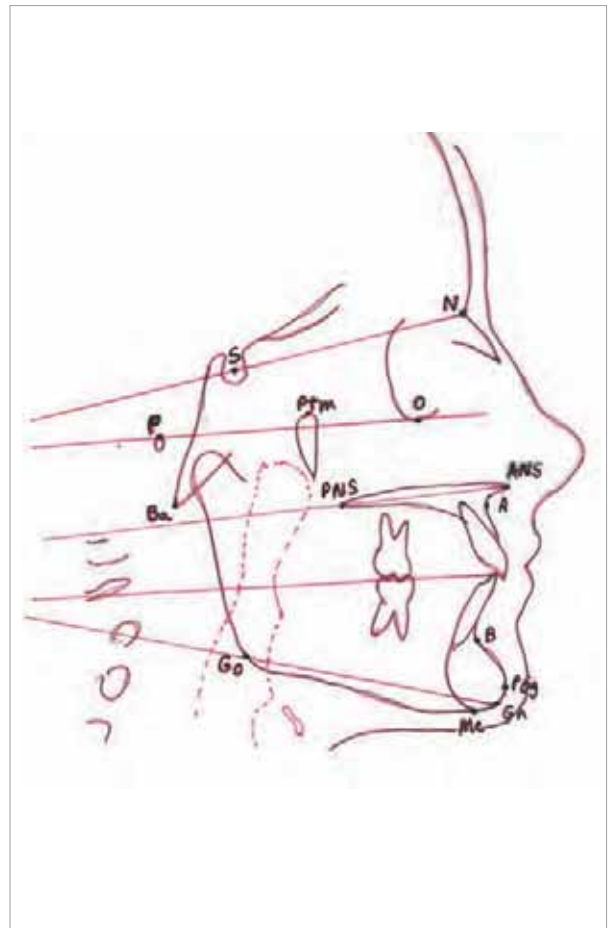
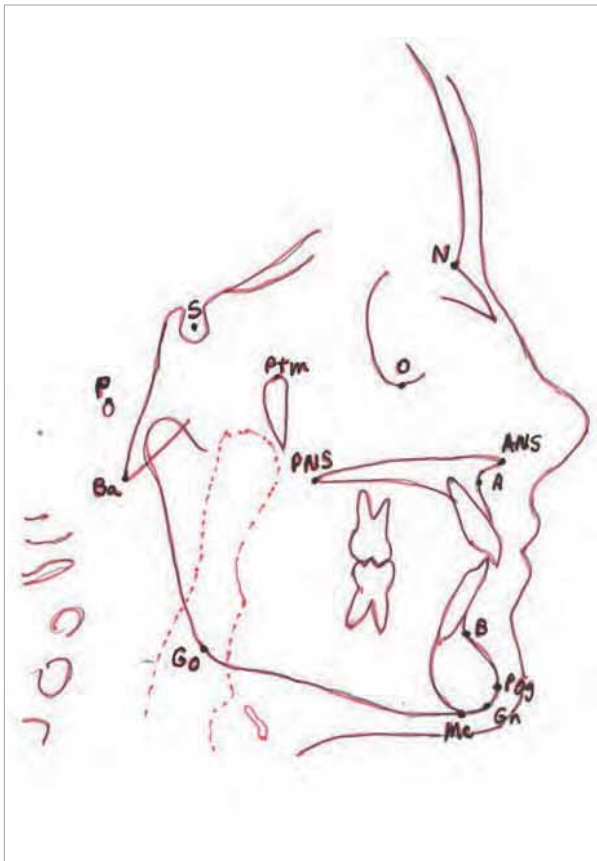
Steiner “norms”:	
	Ideal
SNA	82°
SNB	80°
ANB	2°
+I (MxI) to NA	22°
-I (Mdi) to NB	25°
+I (MxI) to NA in mm	4 mm
-I (Mdi) to NB in mm	4 mm
+I (MxI) to -I	131°
-I (Mdi) to A-Pog line	Vertical line that relates the incisors to the mandibular base. -I (Mdi) should be at +1 to +2 mm for most cases. It can be more (+3) in the case of skeletal CLII discrepancies.
NB to Pog in mm	About +2 mm
GoGN to SN	32°
Y axis	64°
WITS analysis (AO to BO in mm)	Vertical lines (AO & BO) drawn from A and B that are precisely 90° to the OP . This evaluates the skeletal relationship of the mandible to the maxilla. Measure the difference from AO to BO . Normal skeletal CLI is 0 . If the AO is anterior to BO this indicates a skeletal CLII and is given a “plus number”. If BO is anterior to AO this is given a “minus number” and indicates a skeletal CLIII. The Wits indicates the skeletal base A-P discrepancy in mm and thus how much A-P (horizontal) orthopedic correction would be necessary to arrive at Wits 0. This is a very important part of the diagnosis : if the AO, BO lines and the OP are not precisely drawn, then the Wits analysis will be incorrect, resulting in an incorrect diagnosis and treatment plan.

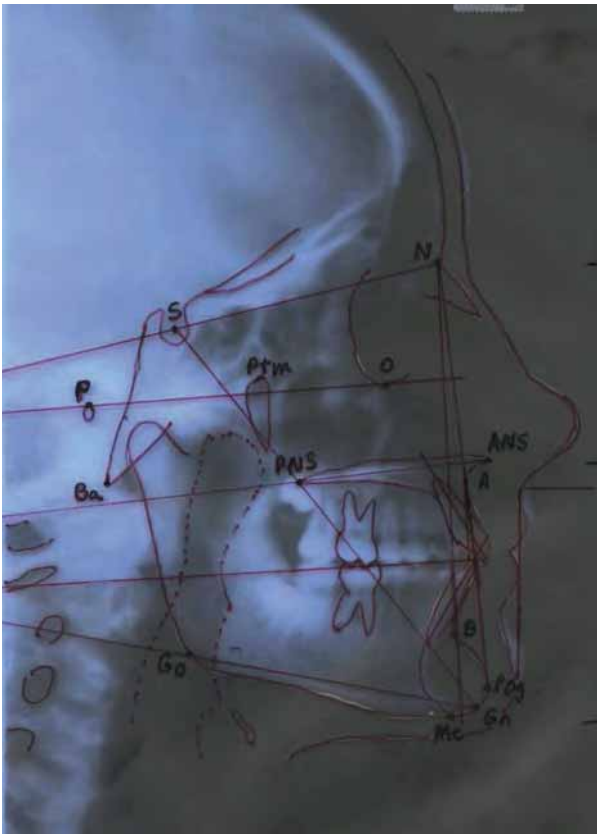
CEPHALOMETRIC TRACING AND ANALYSIS



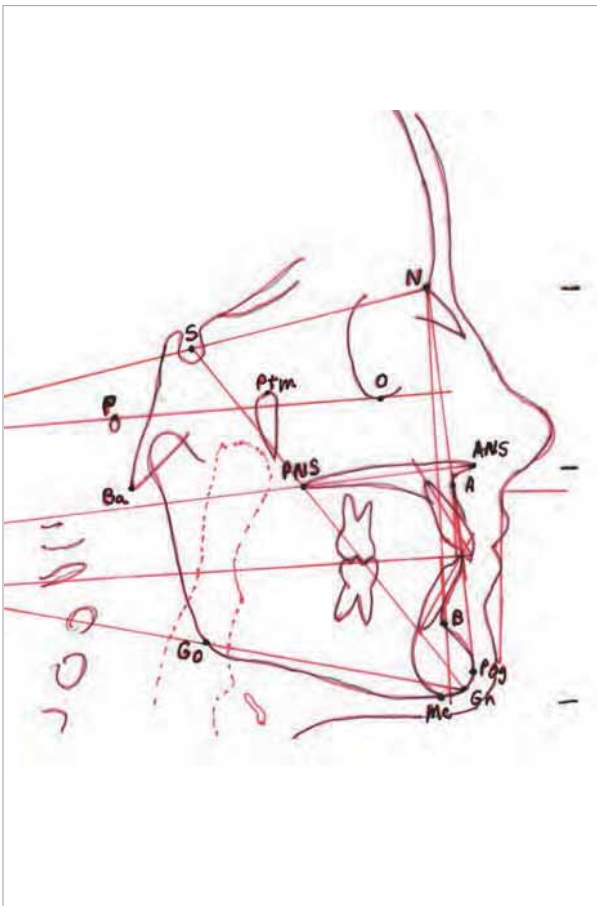
Horizontal Planes ▼

Points ▼

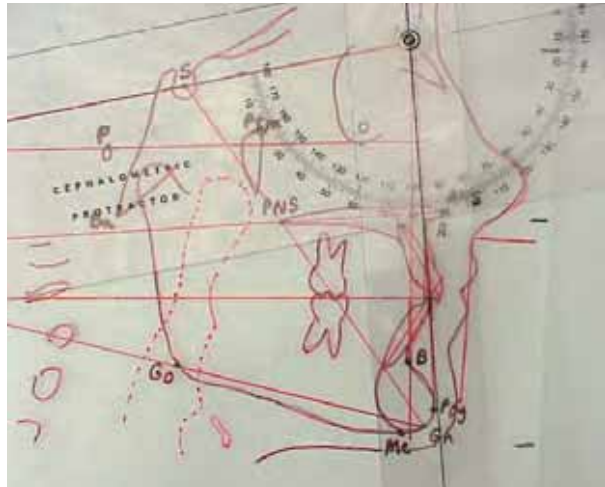



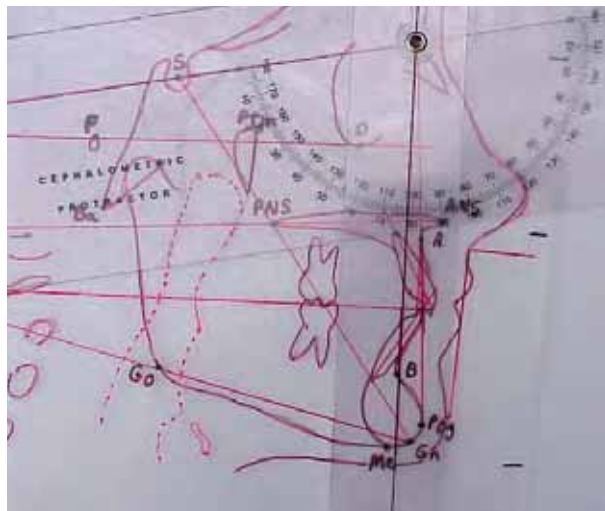
Vertical lines ▼



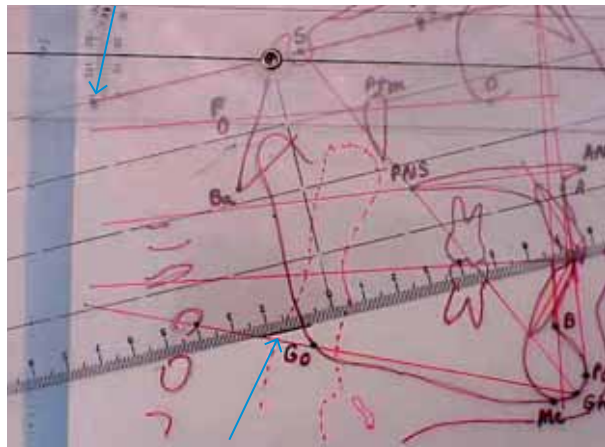
SNA ▼



SNB ▼

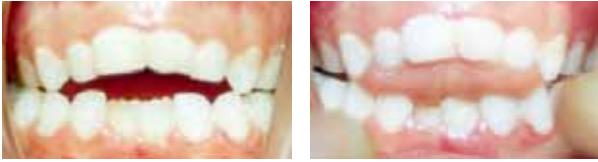

Go-Gn to SN: MPA ▼

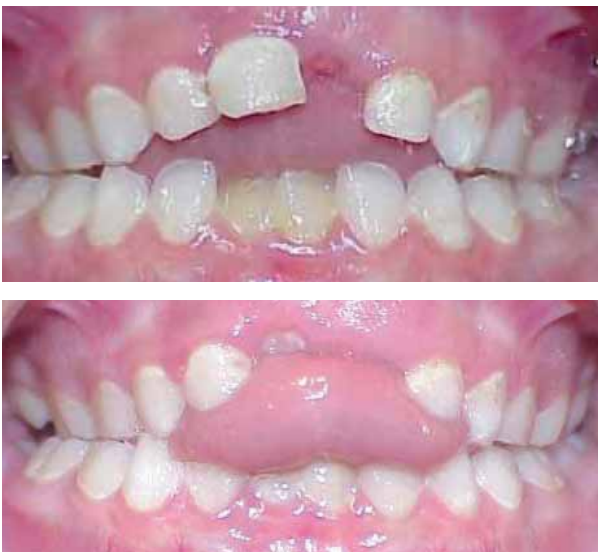

16/4. Case: Le, young girl. Age 6

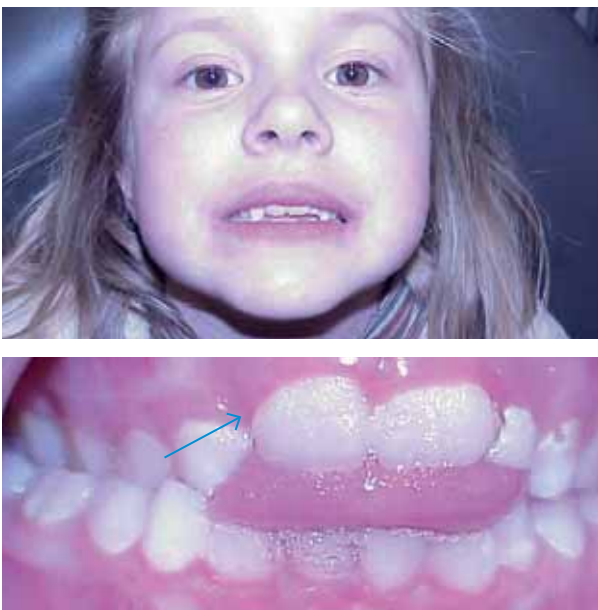Sucking habit (fingers) with tongue interposition in the open bite.



LN AGE 6.9

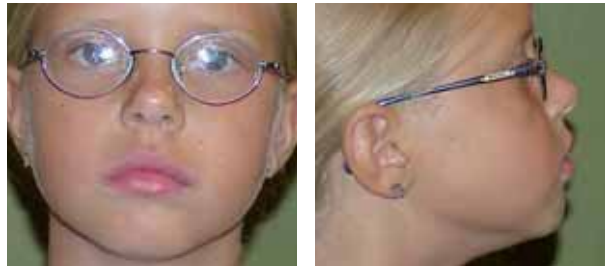


AGE 8.9

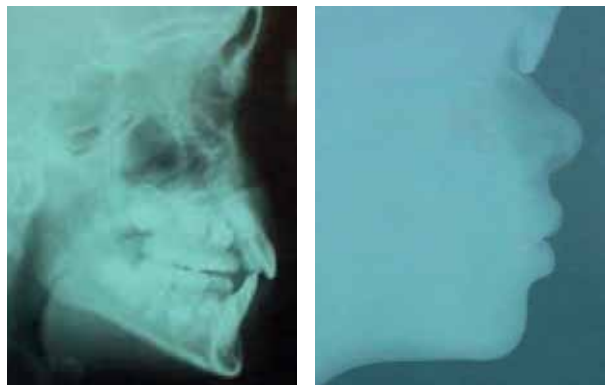
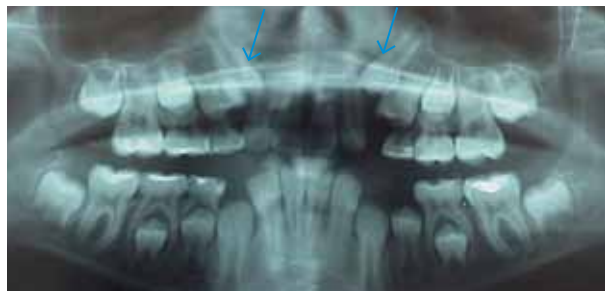

Premature loss of primary lateral (52) 

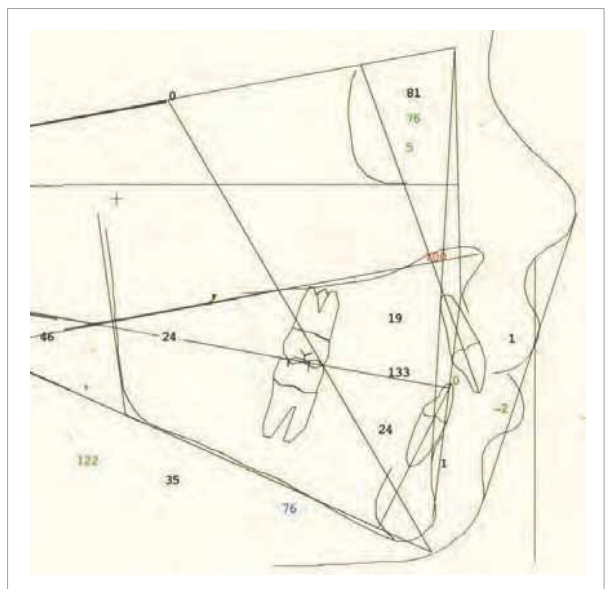
AGE 10.2



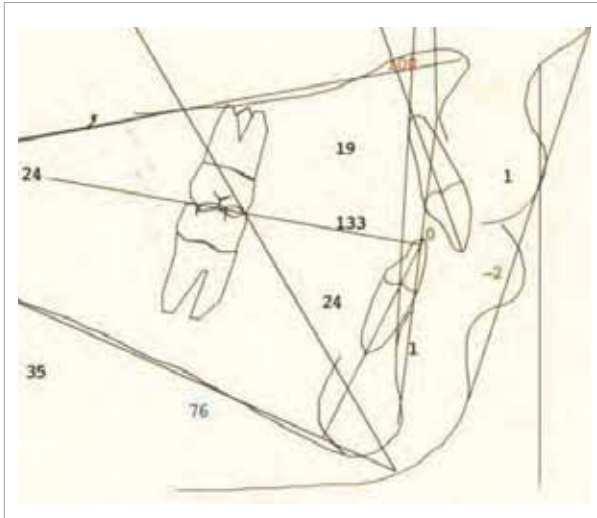
Space needed: 8 mm for I3 and 5 mm for 23. 11 years dental age. 



CLI skeletal and CLI profile with open bite tendency. 



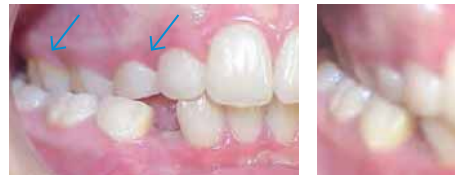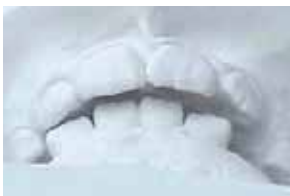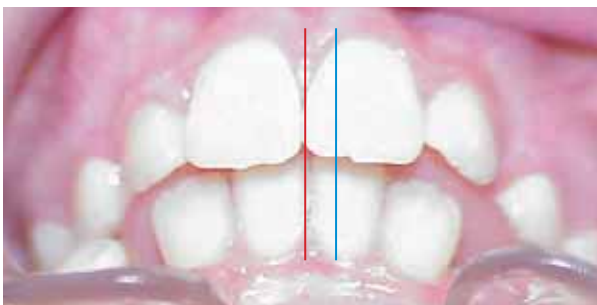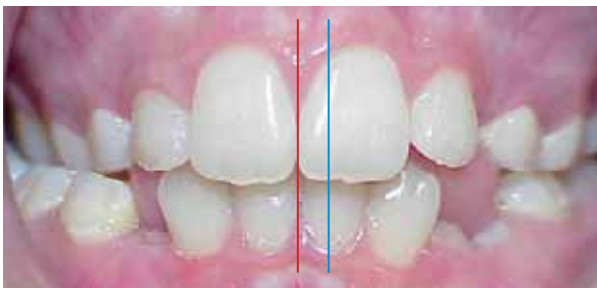SNA 81°
 SNB 76°
 ANB 5°
 +I to NA 4 mm & 19°
 -I to NB 4 mm & 24°
 -I to A-pog 0 mm
 Wits 0
 MPA 35°



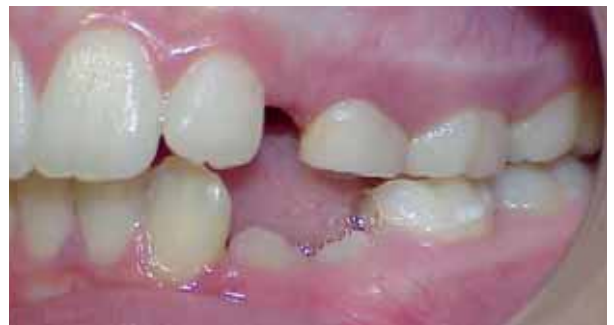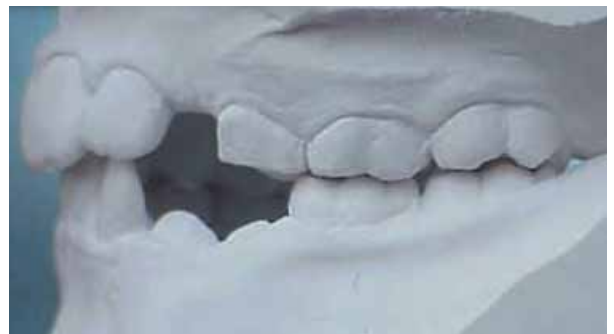Open bite tendency. Patient still has a dysfunctional tongue action.

MAX and MAND M-Ls are shifted to the right side (Red). Blue line is skeletal M-L.

Dental CLII div I with a dental open bite tendency. X-bite right side with a lateral (right) mandibular shift.

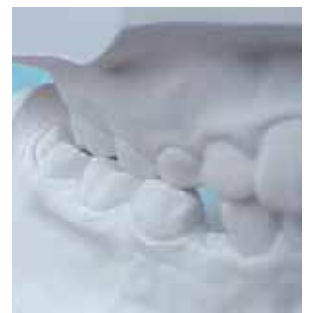
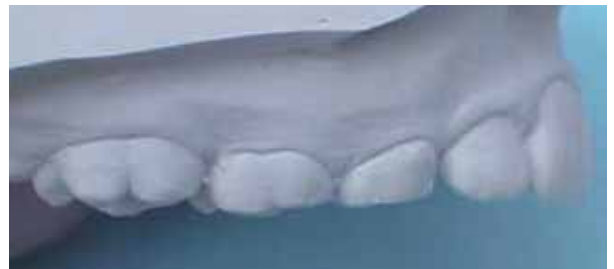
No space for 13.
 X-bite w/ MAND slide to the right.
 MAX: M1 and primary molar are full CLII.

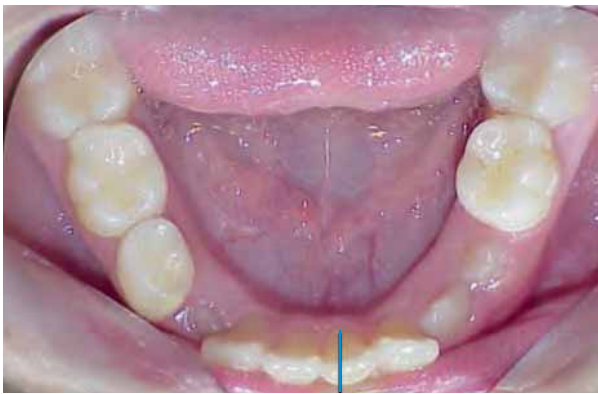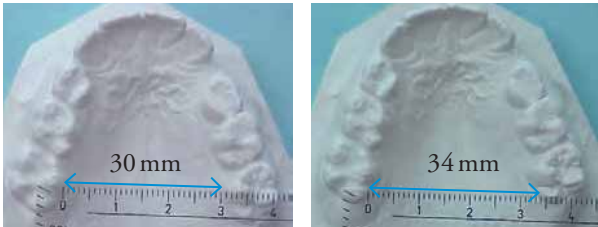

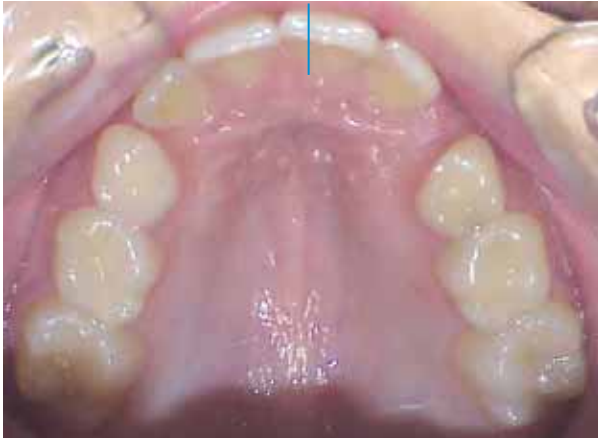
Left side: 1/2 CLII.

Missing 5 mm of space for 23.



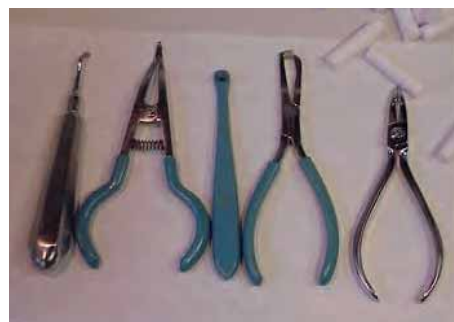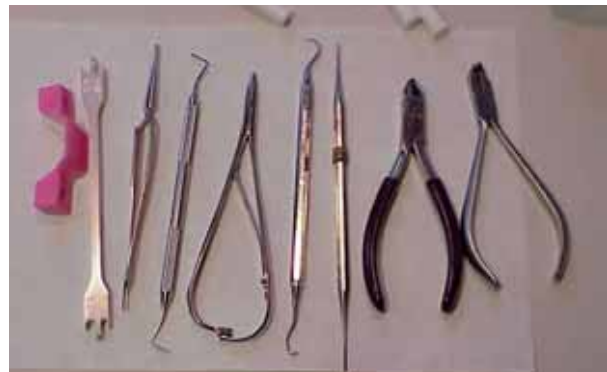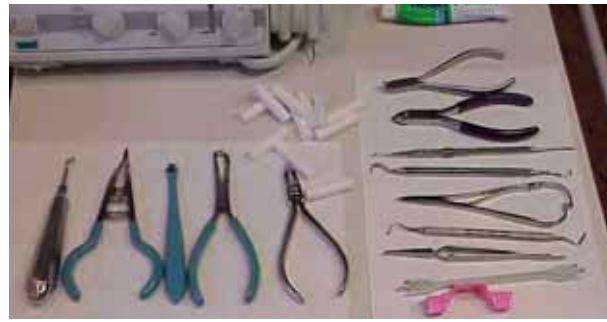V shaped MAX with ML rotated molars.
 Actual lack of space = ~13 mm.
 M-L deviated 2 mm to the right.



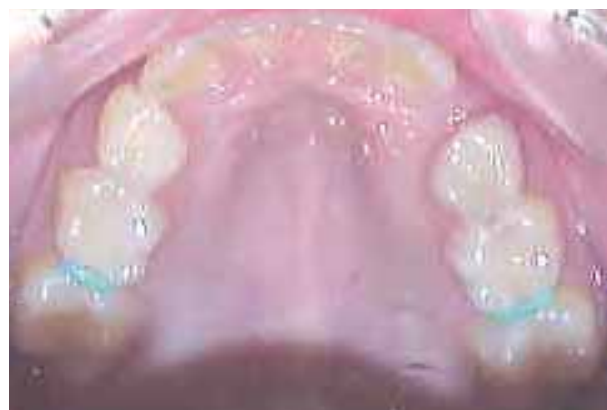MAND M-L is shifted to the right due to a mandibular slide to the right caused by dental interferences.

10.3 YEARS OLD

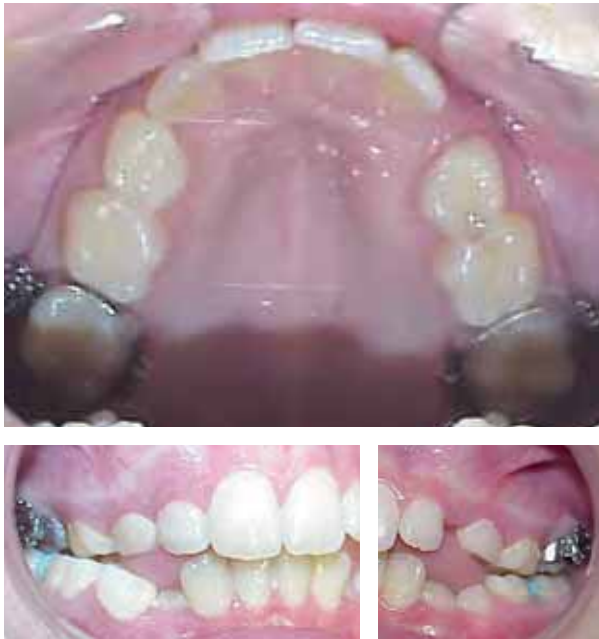Start treatment.



i. Separators placed 5 days before. ▼



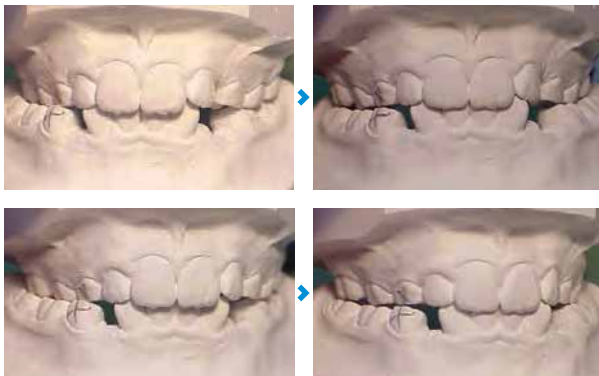
2. Fit MAX bands. ▼



Case Ln: The use of the HA NiTi transpalatal Expander / Rotator is indicated because:

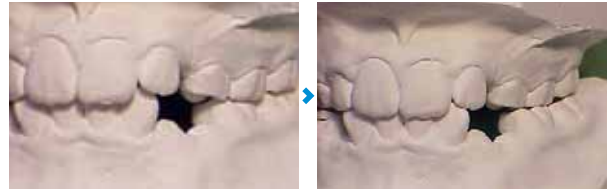1. There is a CLII situation where the molars are in $\frac{3}{4}$ to Full CLII relationship. The molars have shifted forward and need to be pushed back into a CLI position.
2. The palate is narrowed, V-shaped and with a ML rotation of the MIs.
3. The “regaining” of significant space is indicated.
4. There is a significant dental X-bite, caused by a unilateral mandibular slide, that needs to be corrected. The MAND needs to be able to re-center in a neutral condylar position with the M-L on the skeletal M-L.

How to choose a “size” for a NiTi Transpalatal Expander for a case such as this:



Actual Bite ▲

The “bite” when the X-bite is “divided-up on both sides”. ▲

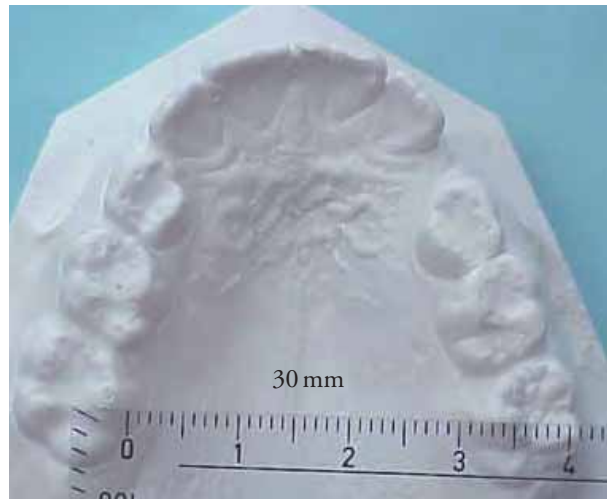


Actual Bite ▲

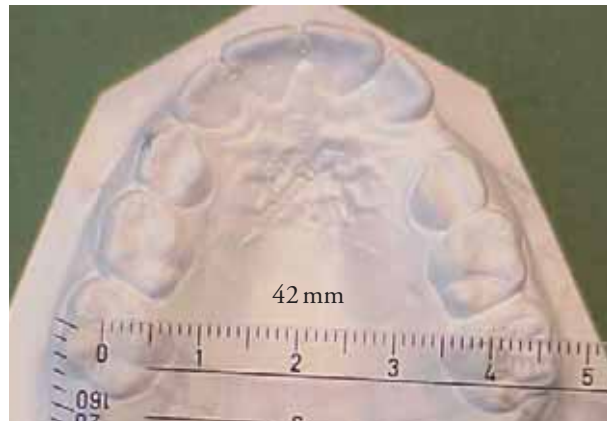
The “bite” when the X-bite is “divided-up on both sides”. ▲

When holding the models as shown, one can visually estimate how much total expansion would be needed to have a normal MAX posterior, bilateral buccal OJ. In this case only about 2 mm expansion per side is needed which could be accomplished using wires only. However, when using only wires, the molars cannot be distalized into a CLI position as can be done using the HA NiTi Expander.

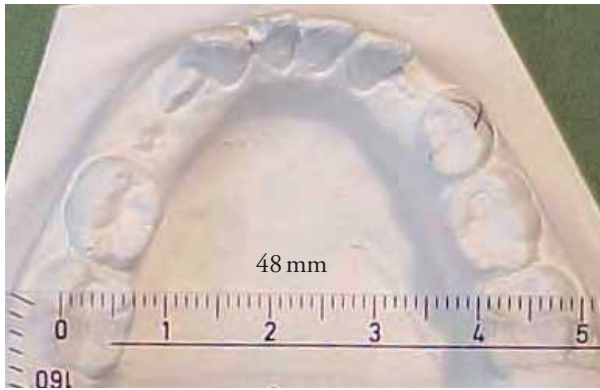1. Measure the “inter-molar distance” between the MAX 1st molars, $\frac{1}{2}$ way up the lingual walls in the area of the Cup of Carabelli (30 mm). ▼



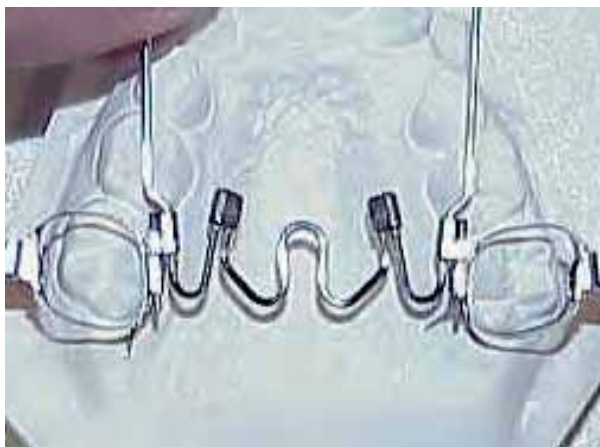
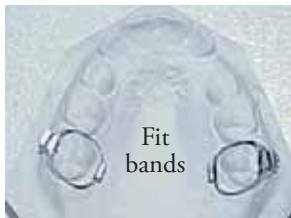2. Measure the distance between central fossae of MAX 1st molars (42 mm). ▼



3. Measure the distance between the distal-buccal cusps of the MAND 1st molars (48 mm).
4. The buccal cusps of the MAND molars have to occlude in the central fossae of the MAX molars. Subtract the difference $48\text{ mm} - 42\text{ mm} = 6\text{ mm}$ of expansion needed.



If 6 mm of expansion is needed, then an Expander with a “size” 2 mm larger than the “inter-molar distance” is chosen. Add the thickness of the bands and lingual sheaths (2 mm per side = 4 mm) to the 2 mm larger Expander “size” and that gives the total of 6 mm. If in doubt, take a larger size. Ex: if 7 mm is needed, then choose a “size” 4 mm larger.

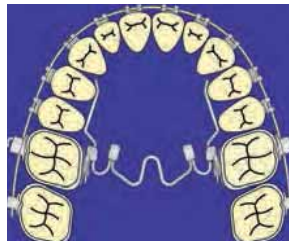
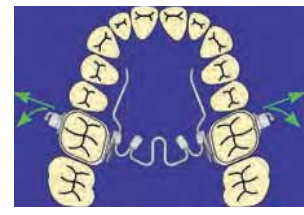
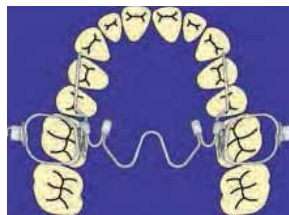About 6 mm total expansion with DB rotation ▶



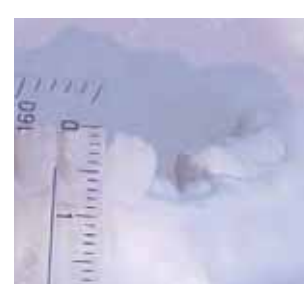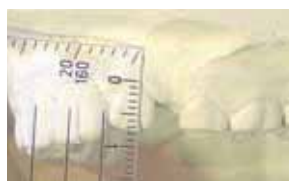Cut length of lingual arms ▶

Tie-in using metal ligature ties ▶

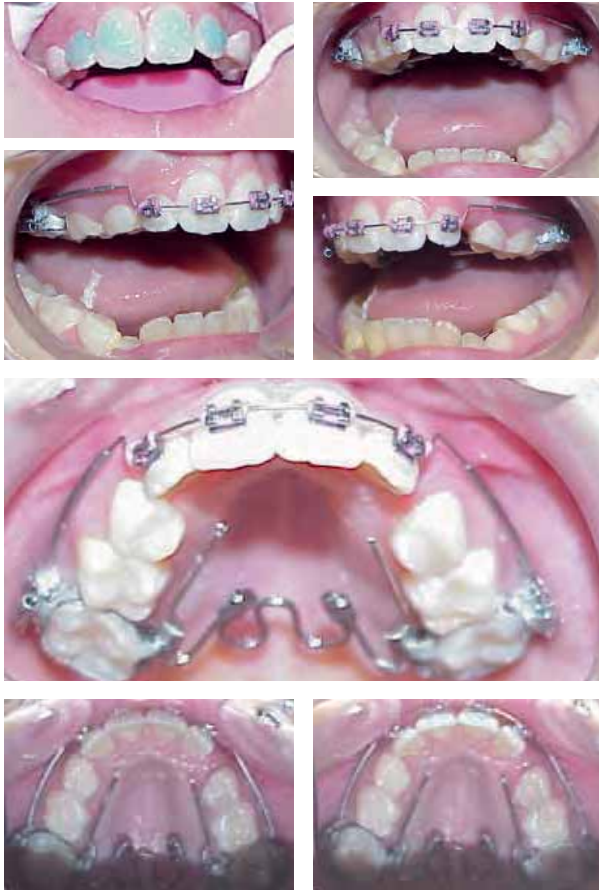

Above: Passive appliance ready to place. It is compressed 6 mm when cemented, thus it expands 6 mm.

The HA NiTi part of the Expander is “cold sprayed” and then cemented in place using light-cure, dual-cure or chemical cure cements.



Open-bite tendency: use bracketing scheme 2. 2x4 set-up with a passive UAW.

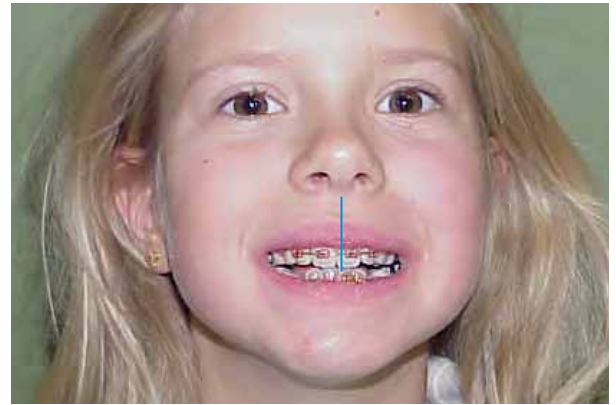
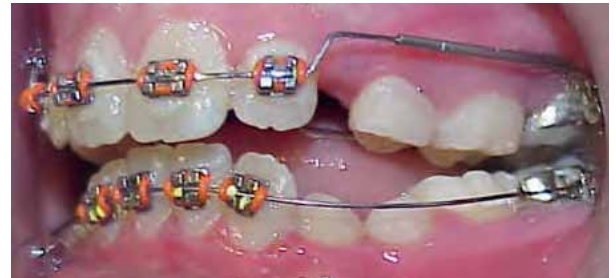
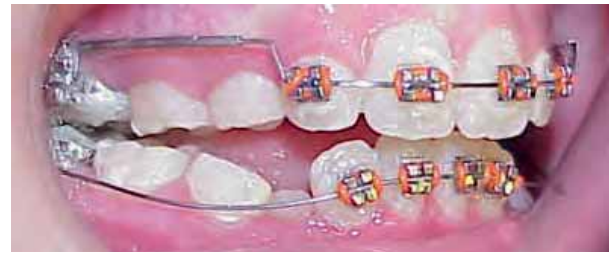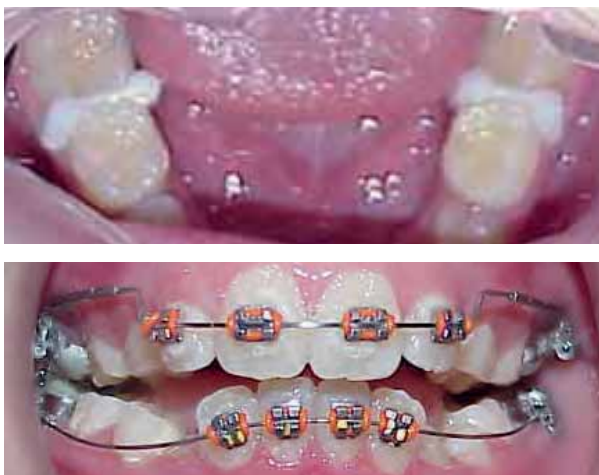...1 WEEK LATER

Dumbbell separators are placed at this time and they will separate the molars during the 30 minutes it takes to bracket the MAND incisors.

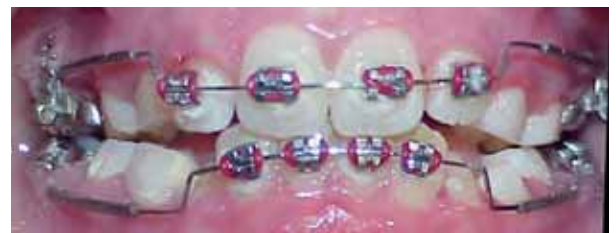MAX: 2x4, 16x16 passive UAW (passive = no adjustments).

MAND: bracketing 2x4 set-up, 16 HA NiTi with BBs to control the incisor position.

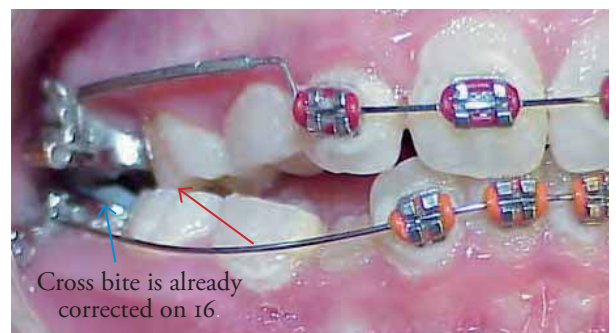


3RD MONTH

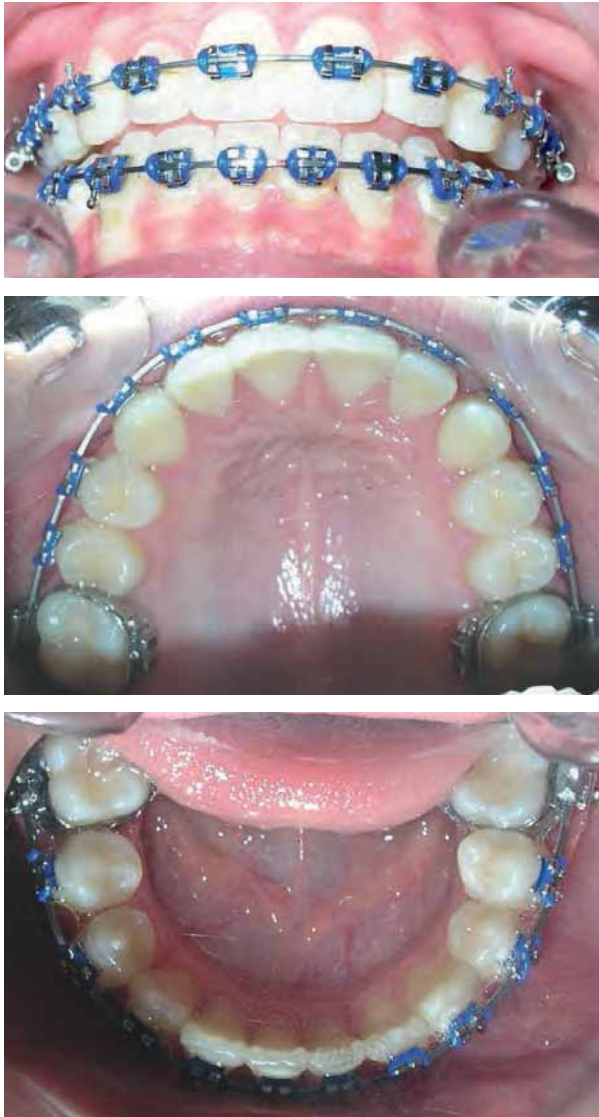MAND: 16x16 UAW, passive with BBs.



Cusps are ground down flat (red arrow) on the primary molars to remove the x-bite and any other interferences.



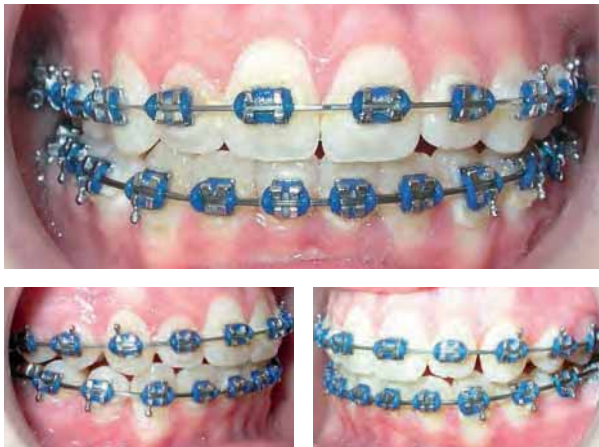Cross bite is already corrected on 16.



22ND MONTH

MAX: same 21x25 HA NiTi.

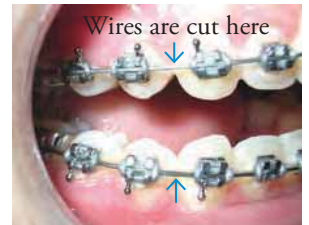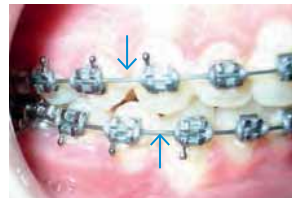
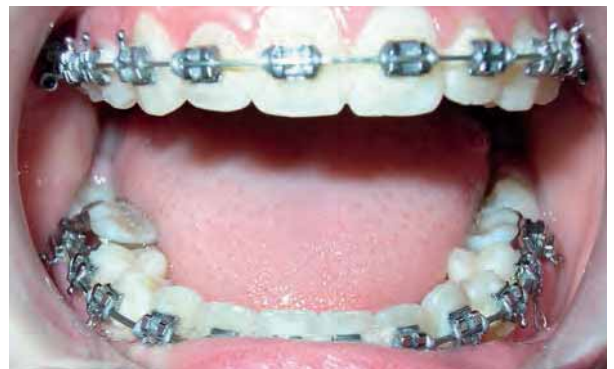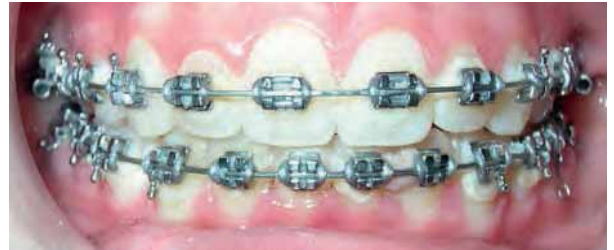MAND: same 21x25 HA NiTi. Bite is settling-in.



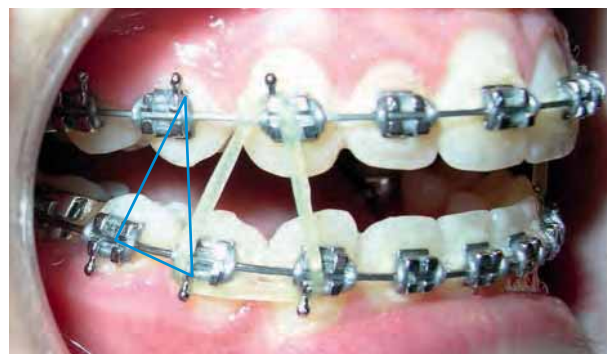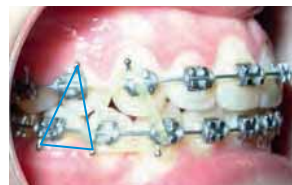2 MONTHS LATER... 24TH MONTH

After 4 months of 21x25 HA NiTi.

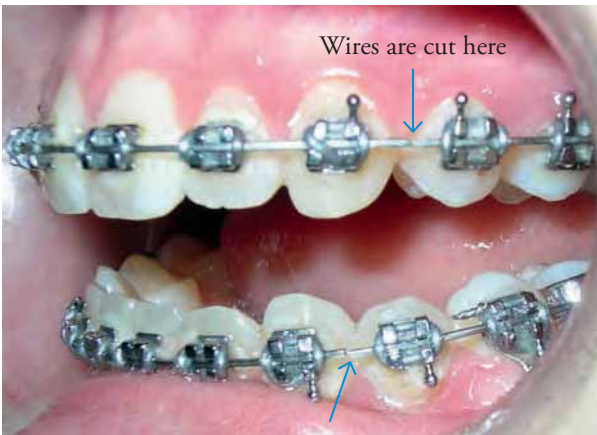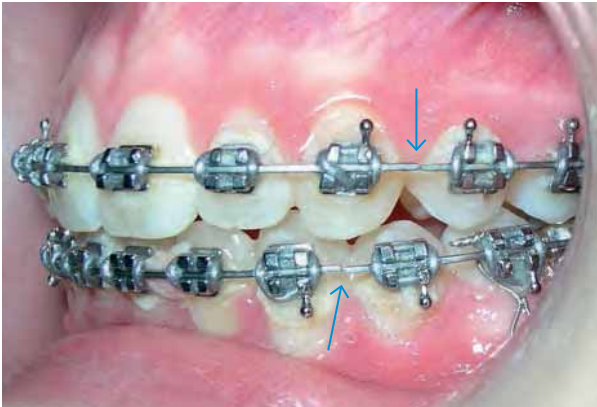MAX & MAND: removed 21x25 HA NiTi and placed previous 19x25 HA NiTi for final finishing.



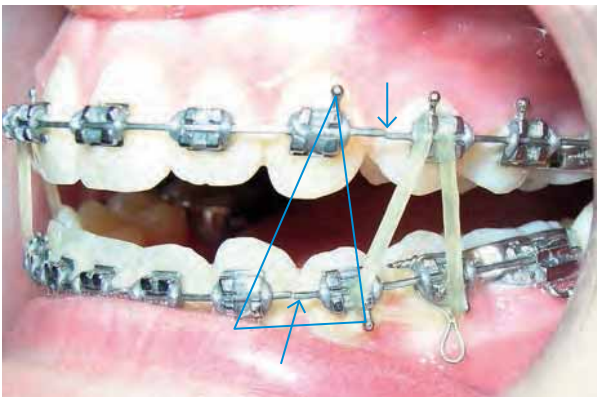
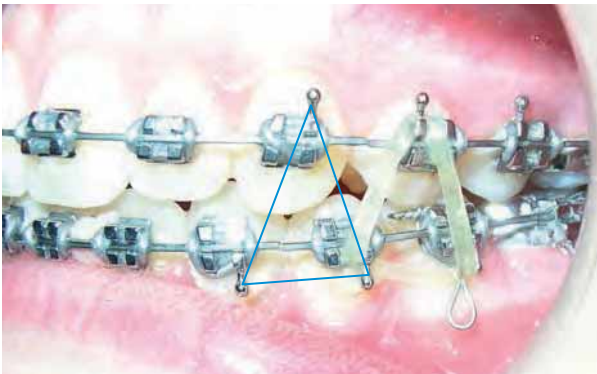
Need to settle-in premolars and cuspids. Wires are cut / segmented to allow the segments to settle-in separately. Delta elastics are used to close down the bite.



4mm delta elastics worn full-time. Check in 2 weeks.



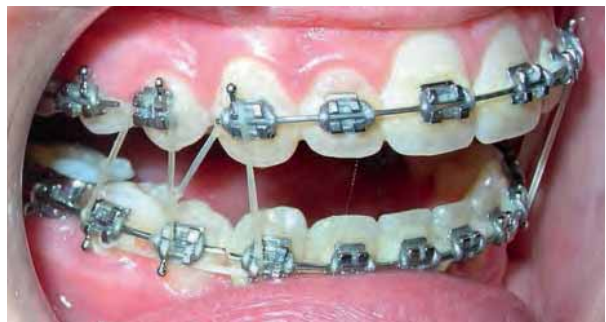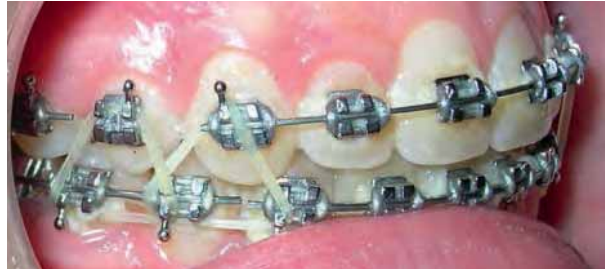Need to settle-in the premolars and cuspids.



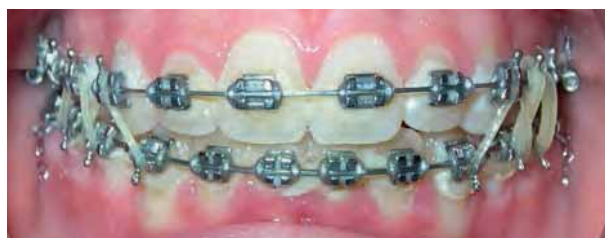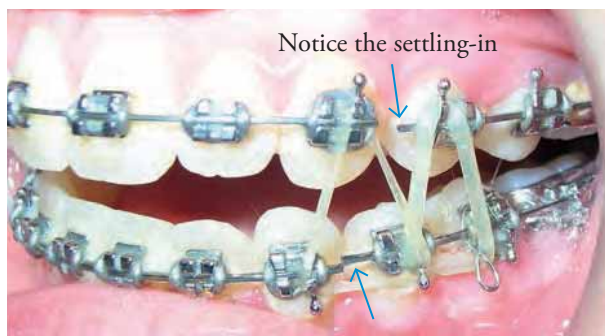
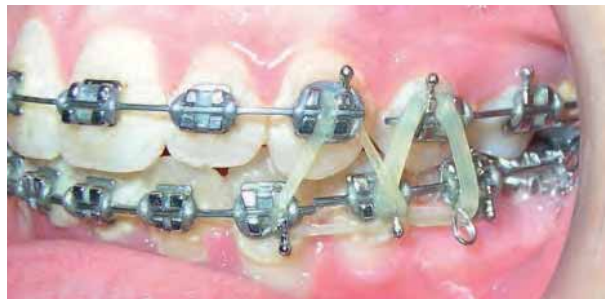4 mm delta elastics worn full-time. Check in 2 weeks.

2 WEEKS LATER...

4 mm delta combination: **Right side:** Continue, but to be worn only 8/24 (night). Check in **one week**.

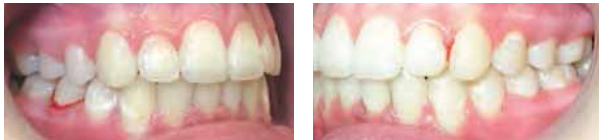
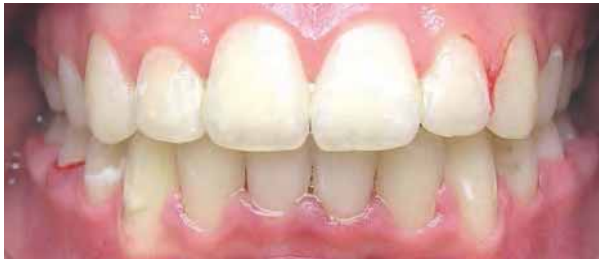
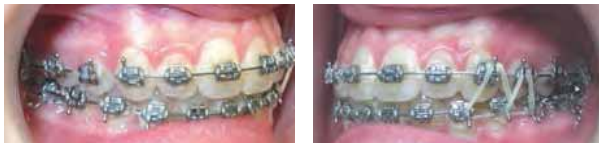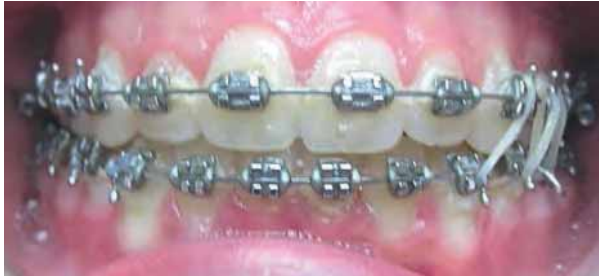Left side: same elastics 24/24. Check in **one week**.

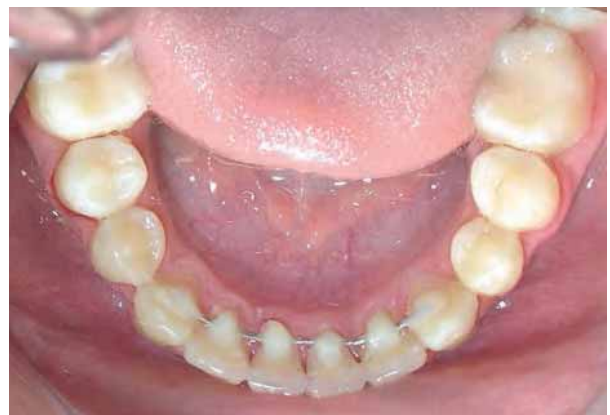
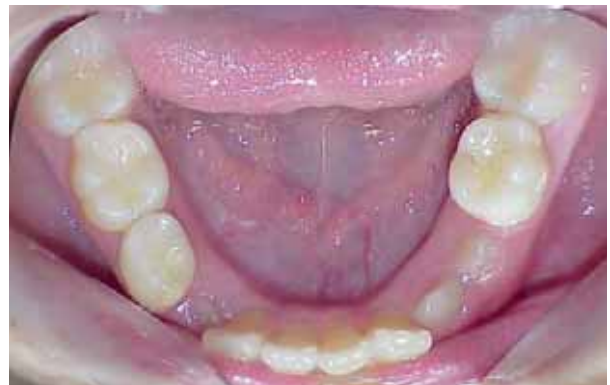
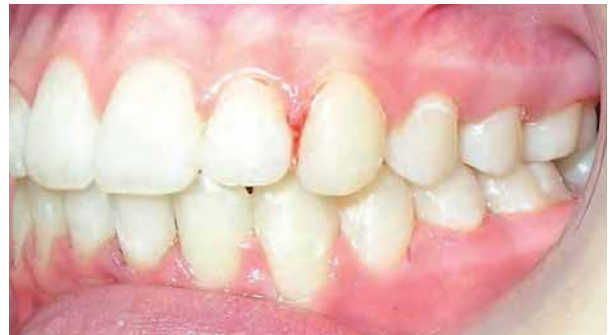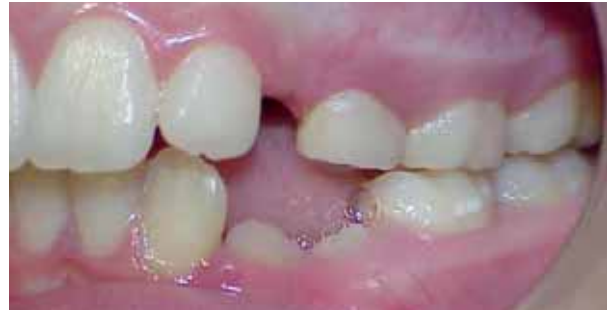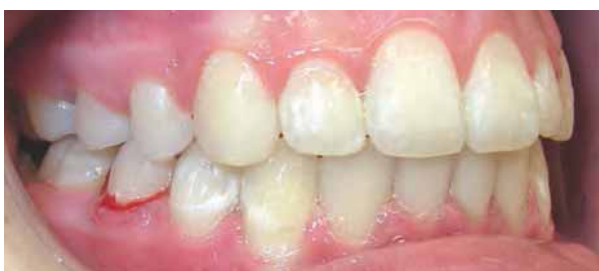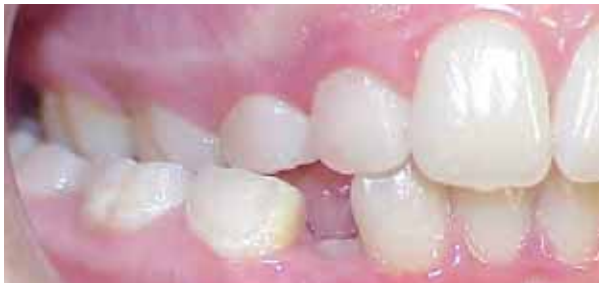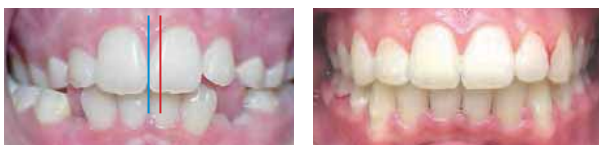1 WEEK LATER...

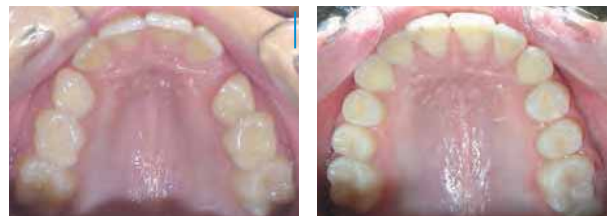Patient came in like this with all premolars and cuspids settled-in.

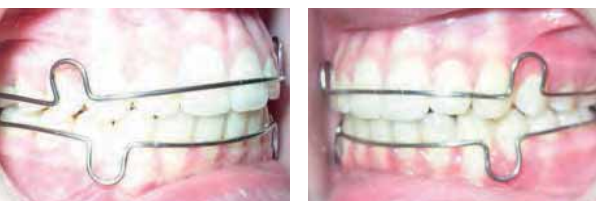
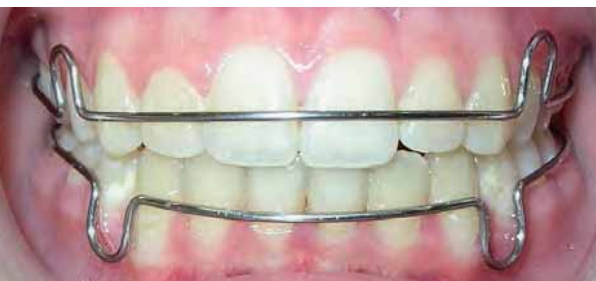
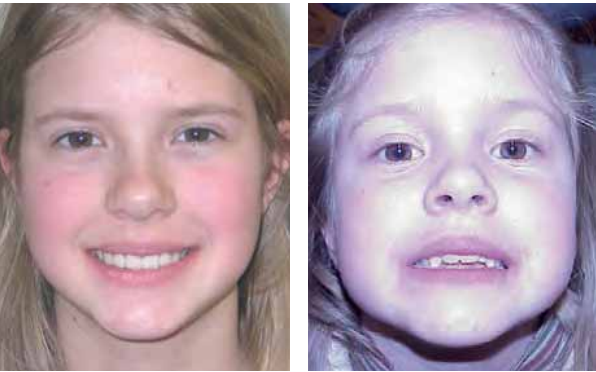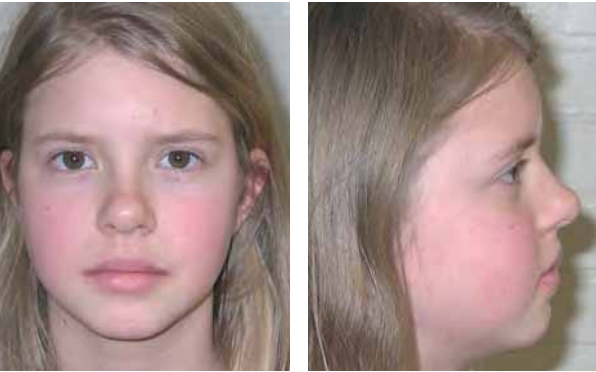Remove braces

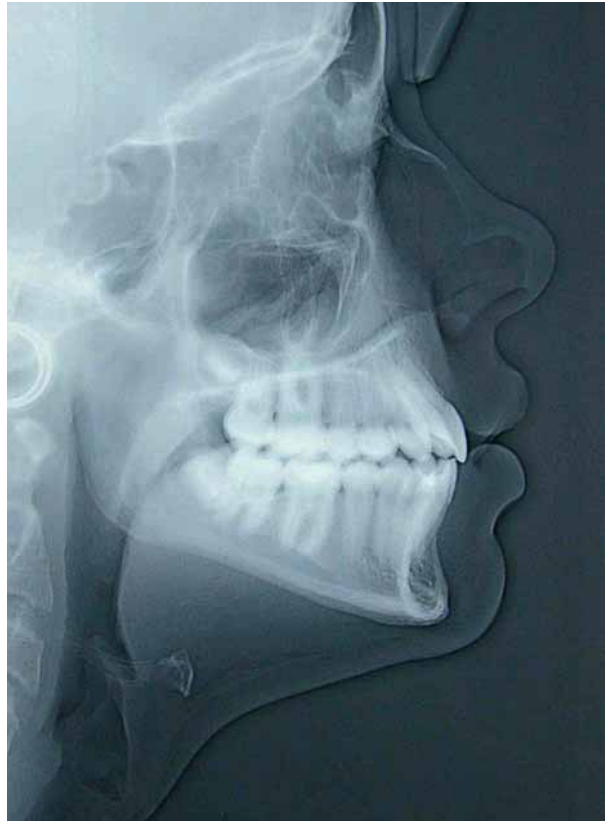

Lower lingual retention wire from 33 to 43 is fixed/bonded with permanent composite.



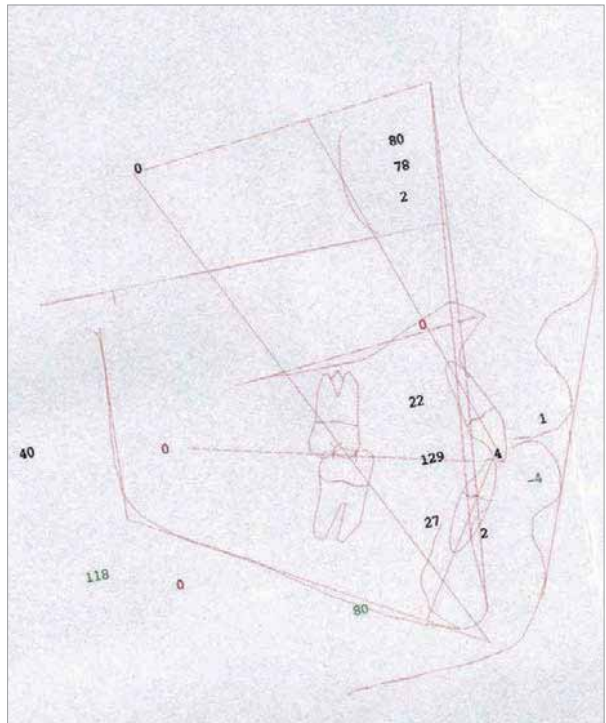


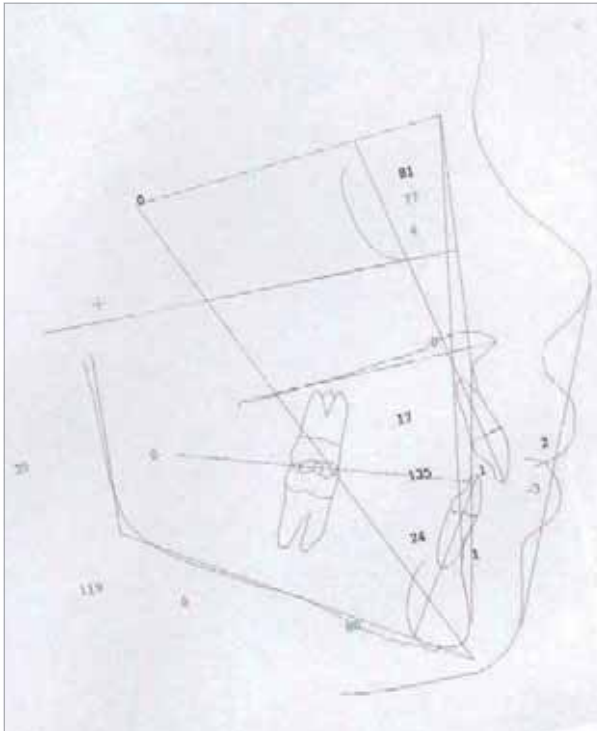
Upper & lower Hawley Wrap-around retainers.



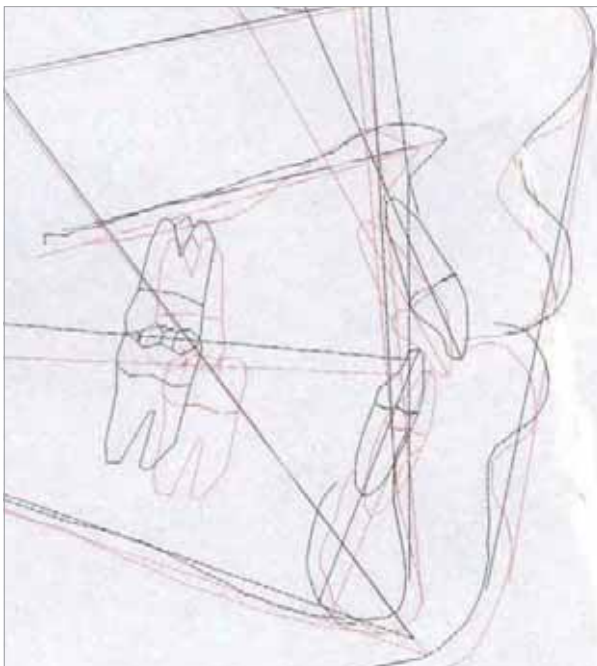
Final Ceph x-ray ◆

Final Tracing: RED ◆

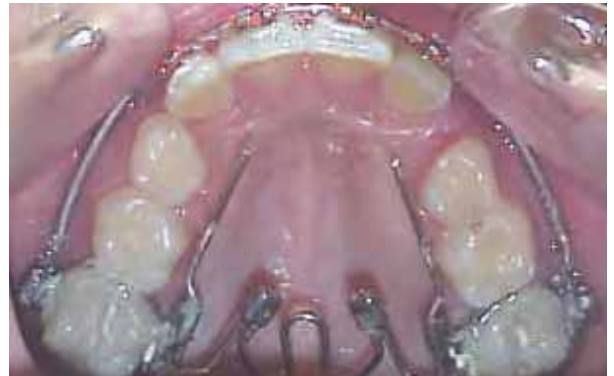



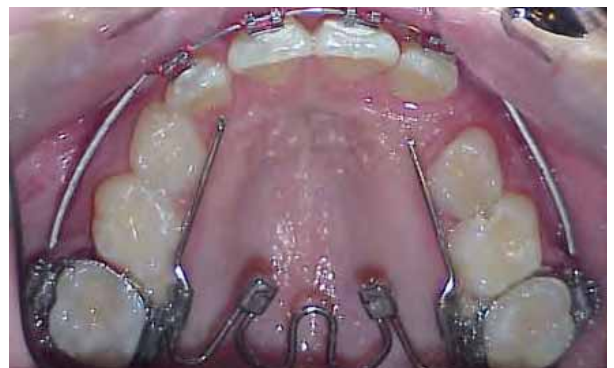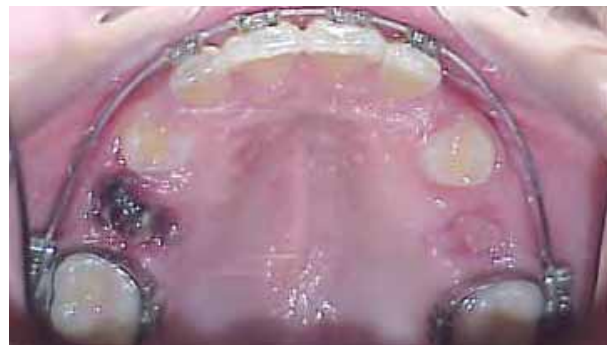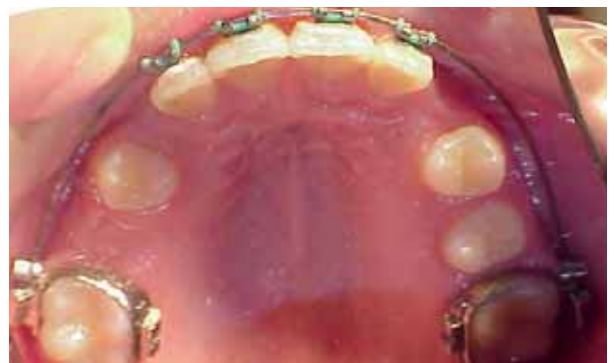Beginning Tracing: Black ▲

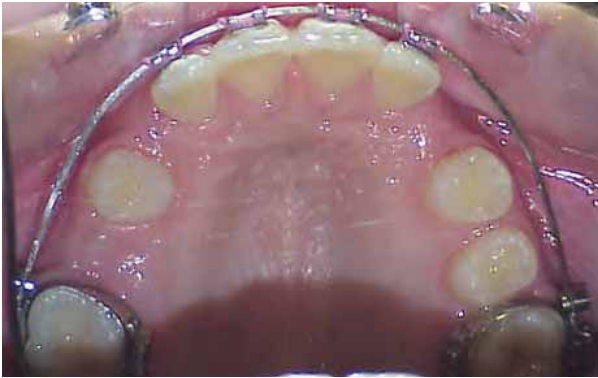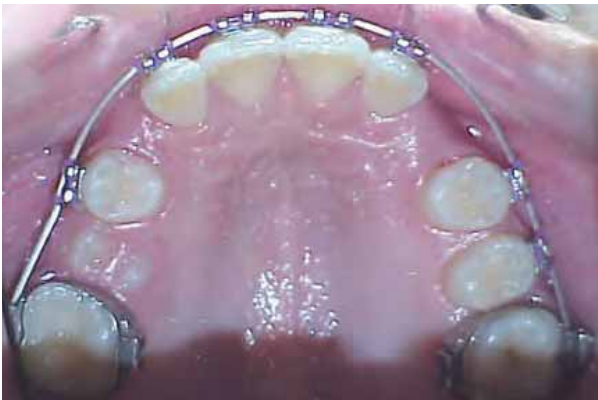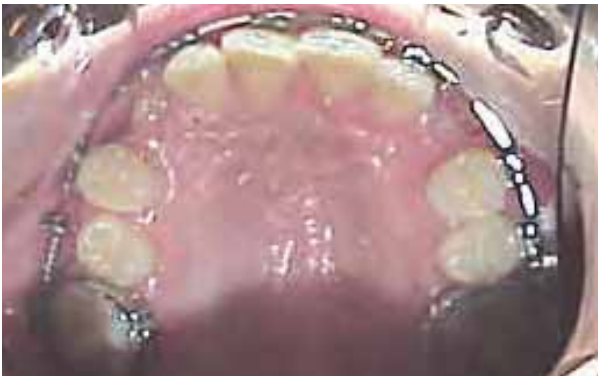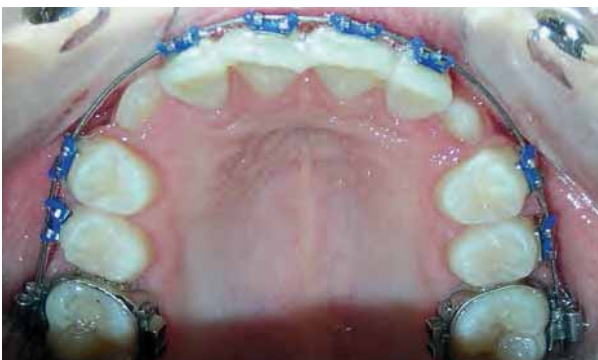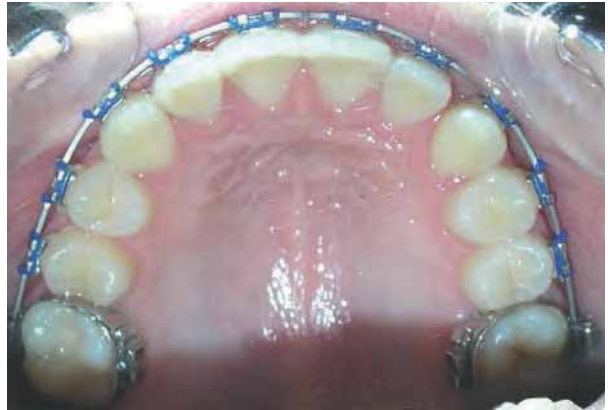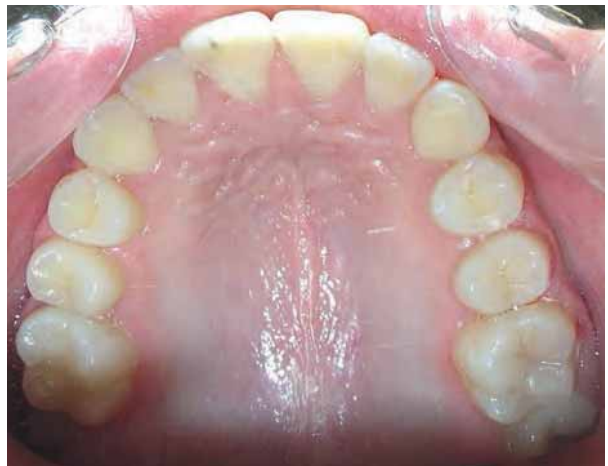**Details of the Cranial Base Superimposition:**

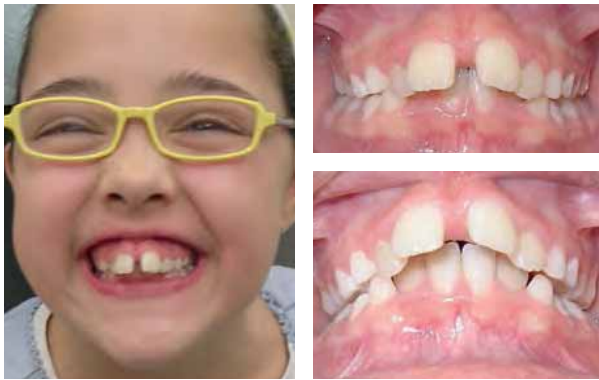- OJ and open-bite are corrected.
- Incisors started CLII, finished CLI.
- Molars started CLII, finished CLI.
- MAND horizontal growth.
- MPA remains the same.

REVIEW

Beginning ▲

3rd month ▲6.5th month ▲8.5th month ▲

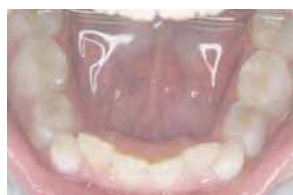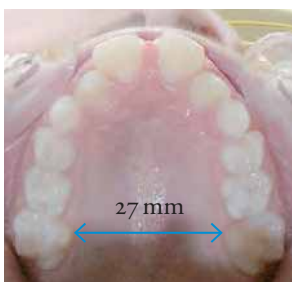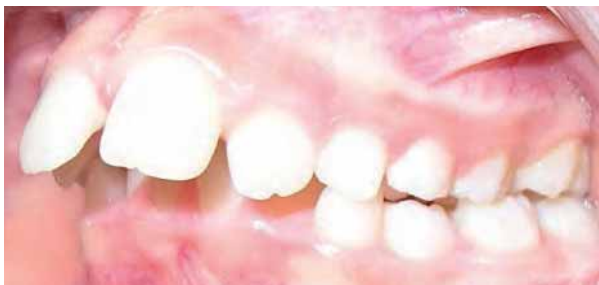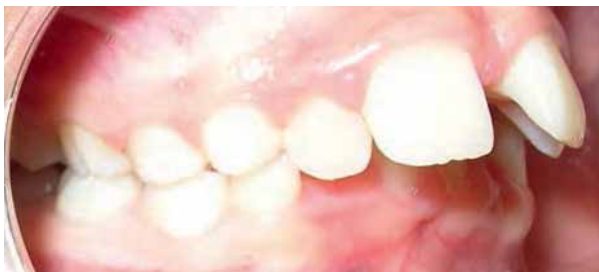10th month ▲11th month ▲15th month ▲17th month ▲22nd month ▲24th month ▲



Full CLII div I

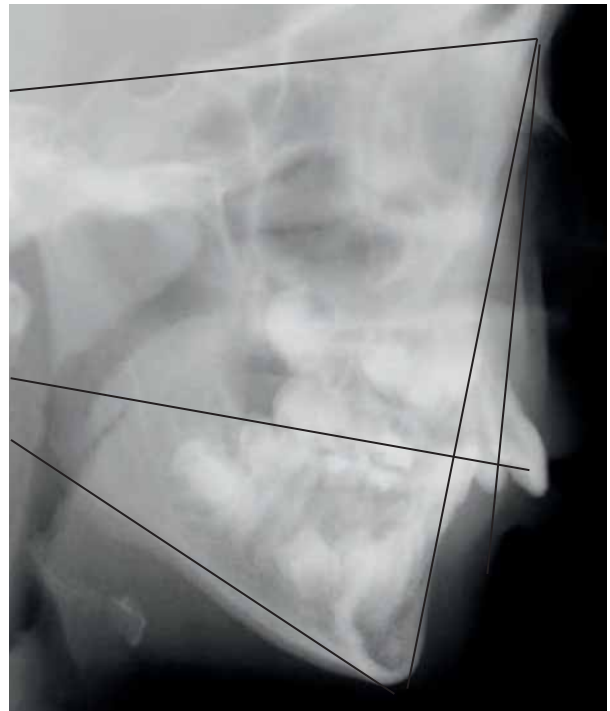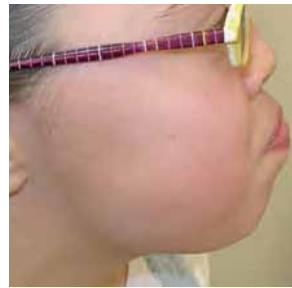OJ = 15

OB = 8



Missing 8 mm of space for 33, 43. ♦

For many cases, such as this, these types of pre-formed, removable “functional appliances” are inadequate and won’t be of benefit.



SNA = 82°

SNB = 75°

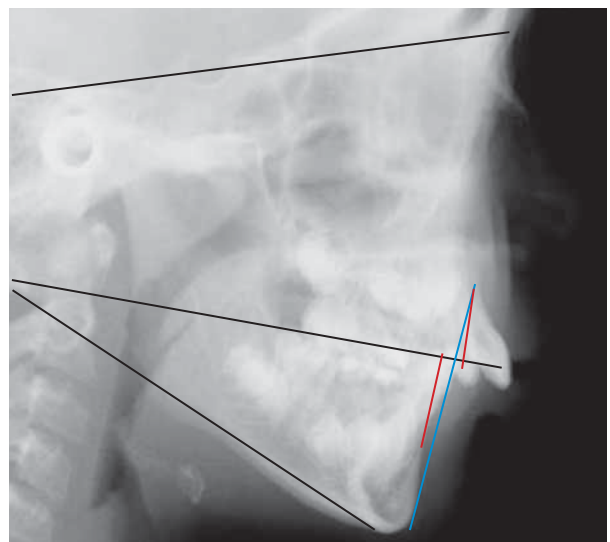
MxI to NA = 34° & 10 mm.

Mdi to NB = 21° & 3 mm.

Mdi to A-pog = -2

GO-GN to SN = 35°

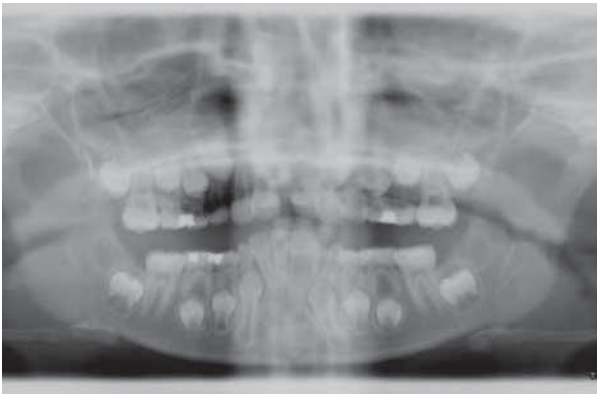Wits = +5



Wits = +5

Mdi to A-pog = -2

Dental age is 10 years.



GLOBAL TREATMENT PLAN:

Change the shape of the MAX arch from V shape to U shape by using the **HA NiTi Expander and the SWA**:

During expansion of MAX by 6 to 7 mm, the appliance will push the MIs disto-buccally (DB) and distally, and by using molar BBs during this period the incisors are automatically retracted by lingual tipping during the first 2 months, thus reducing the OJ. This permits proper lip closure. In effect the length of the MAX arch form becomes wider, U-shaped and shorter during these beginning months. The MAND is freed-up and can posture forward towards a CLI position.

Once the incisors are lingualized and uprighted into a normal position, then bite-opening wires can be placed. Never place bite-opening wires on flared incisors or they will only flare outward even more, with no intrusion.

The MAND and MAX arches are leveled, in a coordinated fashion, using bite opening 16x22 Beta-Ti intrusion wires followed by the 19x25 steel wires: the MAX wire must have an acc C of 5 mm. Slowly, as the bite opens, the mandible spontaneously and gradually moves forward to find the “new anterior bite”.

Space is gained for 33 & 43 by the advancement of the incisors: Mdi to A-pog line = -2 mm and Mdi to NB = 3 mm & 21°, thus they can be tipped forward several mm if needed to gain the necessary space.

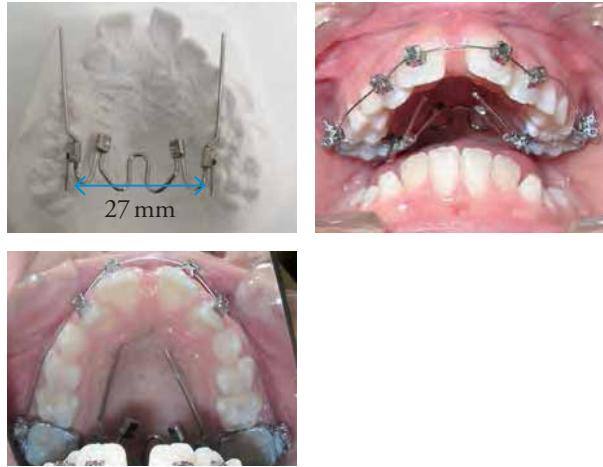
CLII elastics for final correction of the: CLII, MAND mid-line, OJ and OB. By the time all the teeth are bracketed, the OB will be opened sufficiently and all that will remain to be reduced is 2 to 3mm of OJ which is easily and quickly corrected with CLII elastics.

1ST MONTH

MAX: Bracketing (sch 1), 2x4.

NiTi Expander size 30 (will provide -7 mm expansion).

16 HA NiTi, BBs.

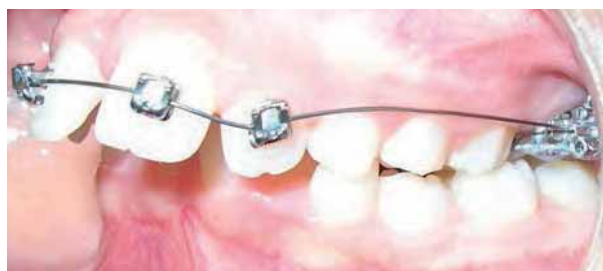
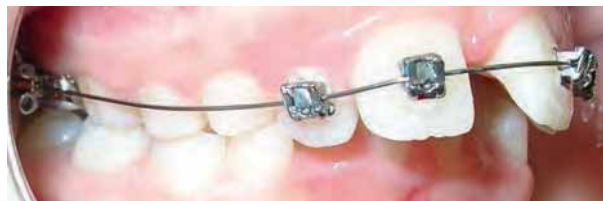
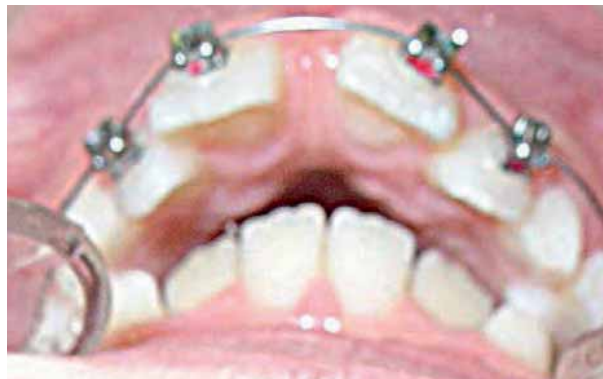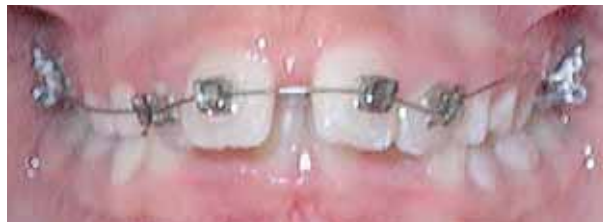Problems:

Vertical: OB = 8 mm (MAND incisors touch the palate).

Transversal: molar width = 27 mm.

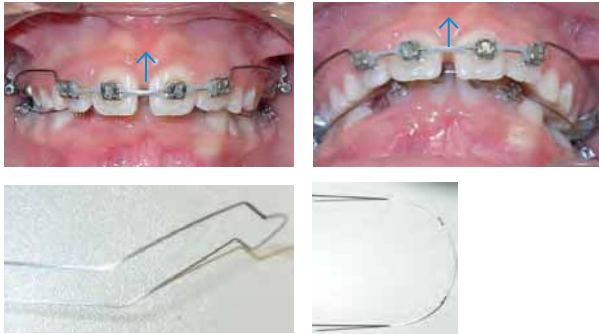
A-P: OJ = 15 mm and a Wits of +5.



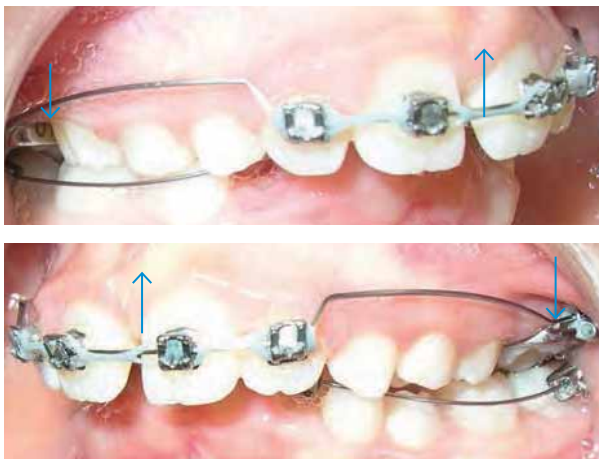
3RD MONTH

MAX: 16x22 Beta-Ti intrusion archwire w/ tip-back bends, BBs and L-L CH 12 to 22.

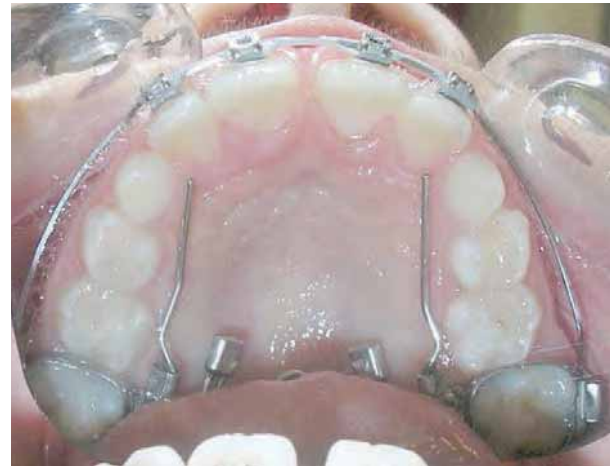MAND: Bracketing, 16 HA NiTi, no BBs.



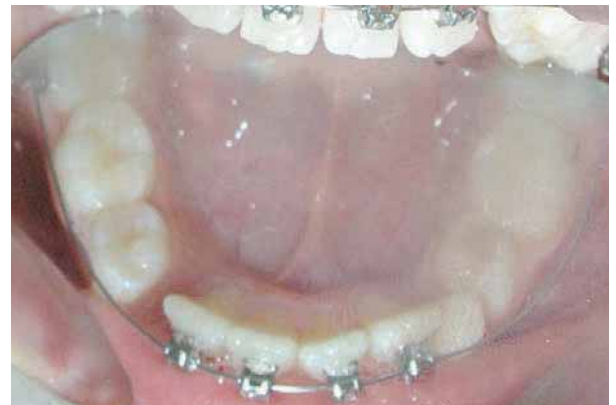MAX: N. 16x22 Beta-Ti intrusion arch with “tip-backs” for bite-opening: intrusion of the incisors and extrusion of the molars.



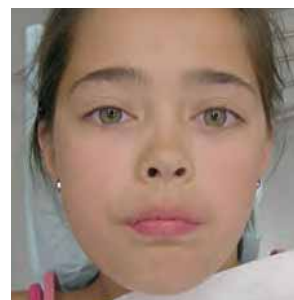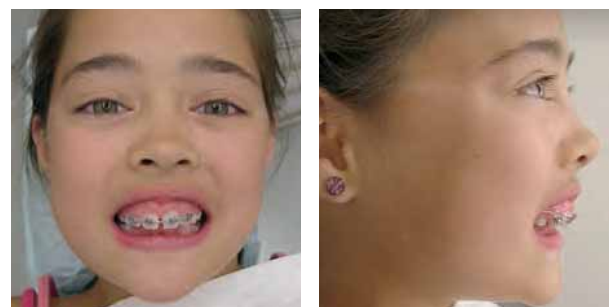
MAX: Expander is not completely opened.



MAND: Incisors are upright and lingually positioned to the A-pog line, thus they can tip forward 2 to 4 mm and still be ideal. This creates space for 33 & 43. ♥



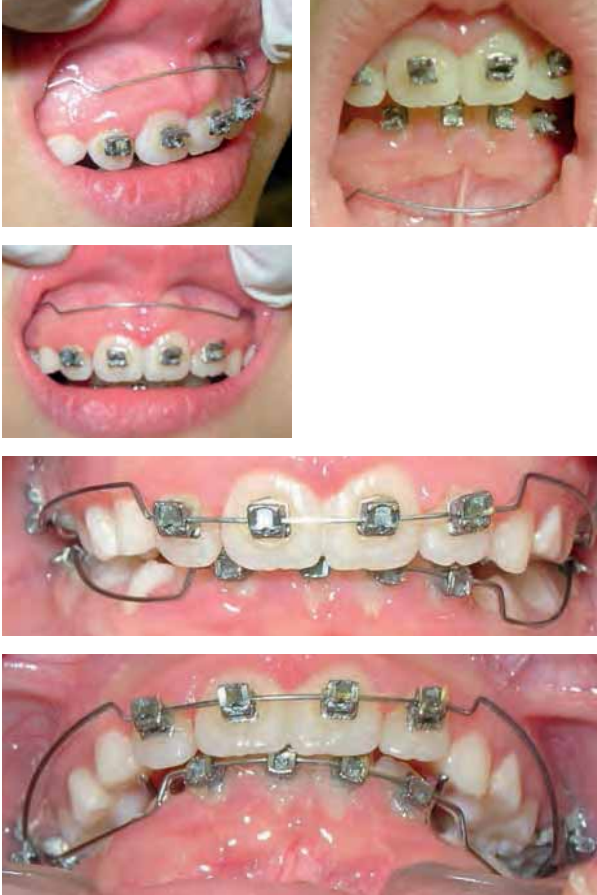4TH MONTH



5TH MONTH

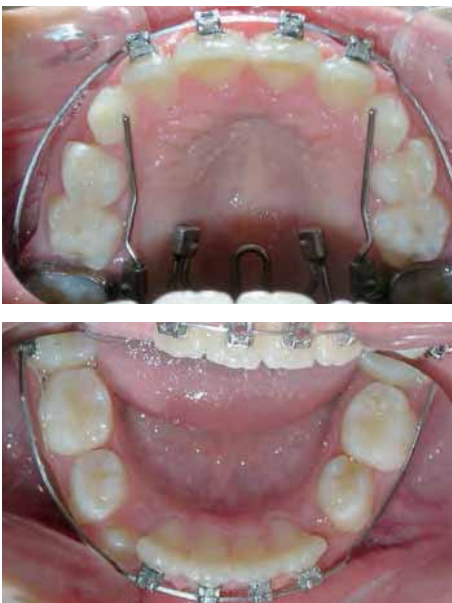MAX: Same 16x22 Beta-Ti intrusion wire w/ BBs.

MAND: N. 16x22 Beta-Ti intrusion wire.



MAX: Expander is now fully opened.

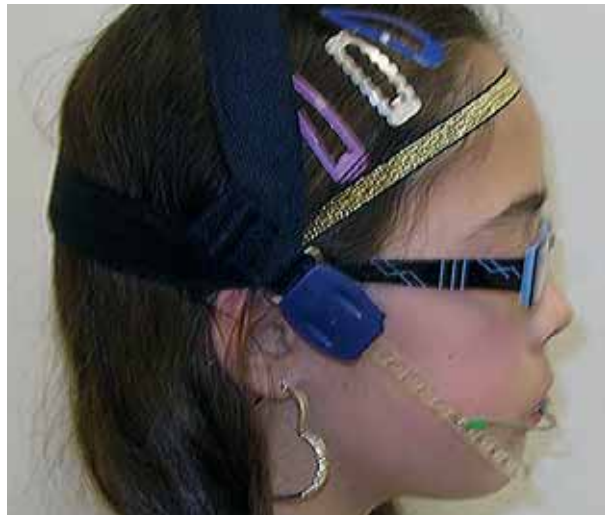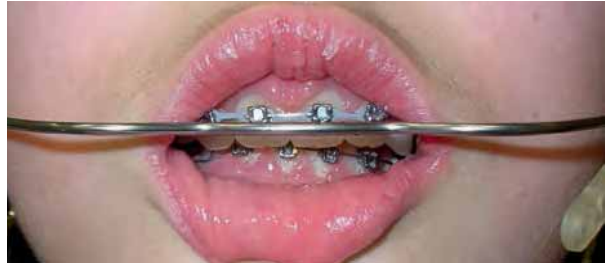MAND: 43 is erupting into the space.

2 MONTHS LATER... 7TH MONTH

Patient had surgery on the frenum to free the tension on the upper lip.

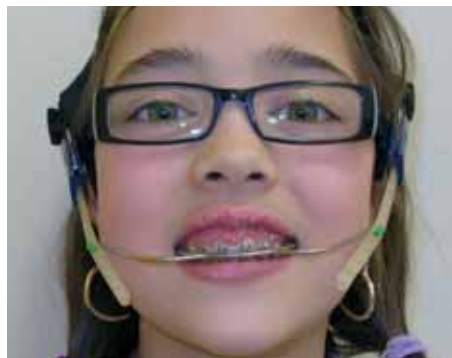MAX & MAND: same 16x22 Beta-Ti intrusion wires. Bite is opening.

Placed occipital-pull HG, 600gr per side, 16/24 (home hours).




The idea of using mini-screws to intrude the MAX was refused by parents and patient.

Thus, placed Hi-pull Head Gear with 600gr/side occipital force to be worn 16/24 (at home). This is used to modify the maxillary growth (slow it down while the MAND grows forward at a more rapid rate) and to provide vertical anchorage for the maxillary molars. With proper usage, the maxilla can be intruded or at least relatively intruded.



And because the maxillary growth has been modified and there is now spontaneous lip closure, the profile has been improved slowly and naturally.

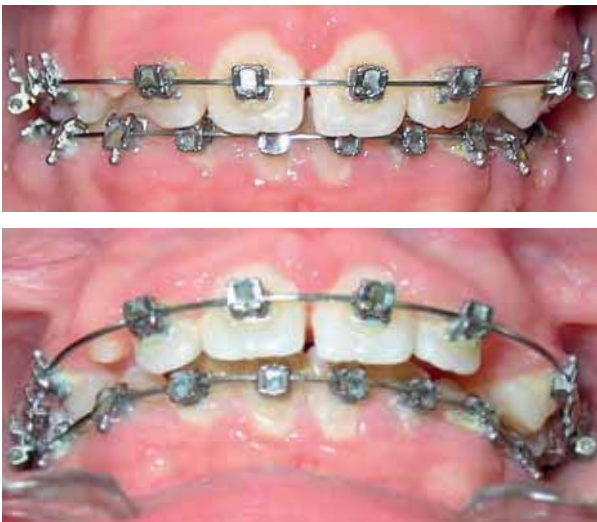

15TH MONTH

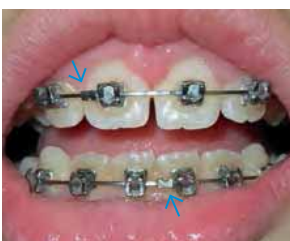Bite is opening and the mandible has advanced.

MAX: bracket 24 25 14 15; 20X20 HA NiTi.

MAND: bracket 33 34 43 44; 20X20 HA NiTi.



Stops (crimp) are needed for “self-ligating” brackets to keep wires from sliding out the distal end of molar tubes.

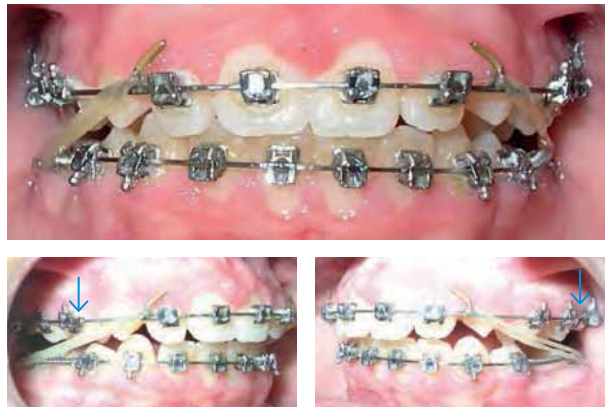

19TH MONTH

MAX: 19x25 posted steel; crimp stops (blue arrow) mesial to 14 & 26 (to keep wire from distalizing when using CLII elastics).

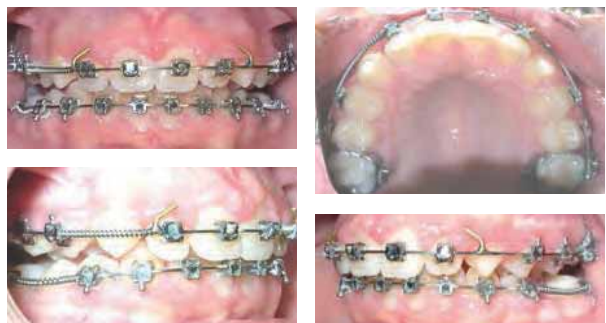MAND: 19x25 posted steel with expansion (arch shape had become too narrow). O-C spring to hold space for 45, 35.

In order to stimulate an orthopedic advancement of MAND: CLII elastics, 10 mm, night-time only (8/24).



21ST MONTH

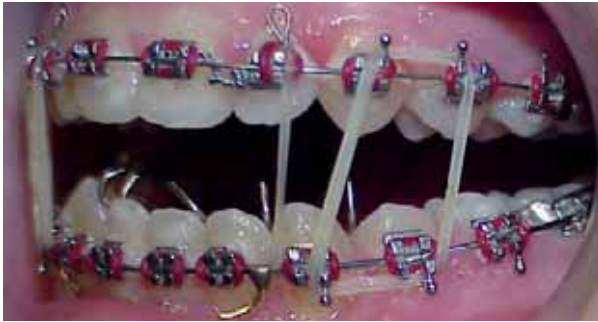
Bite is opened. The patient closes in CLI w/ improved lip posture. The spaces are being maintained for the erupting permanent teeth.



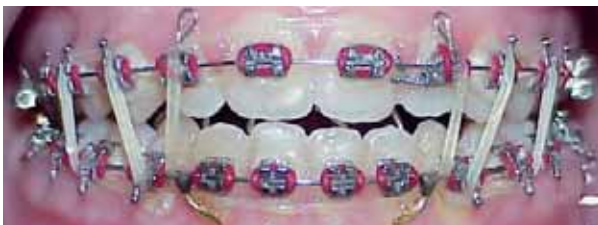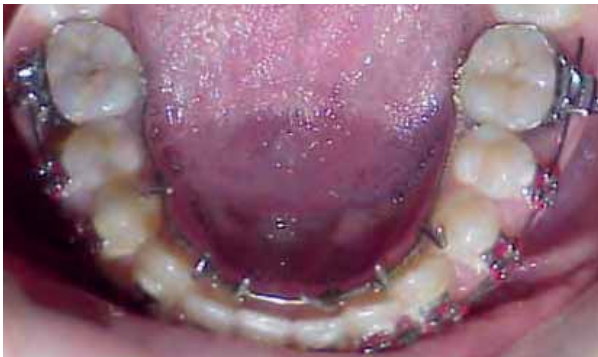Esthetic results after the levelling is completed.

Patient is 12 years old. ■

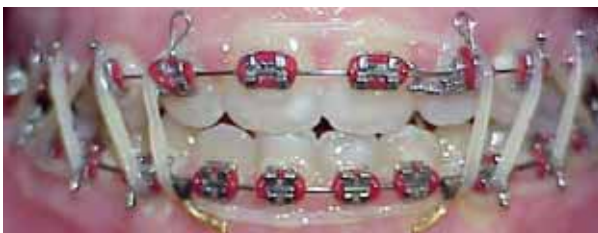



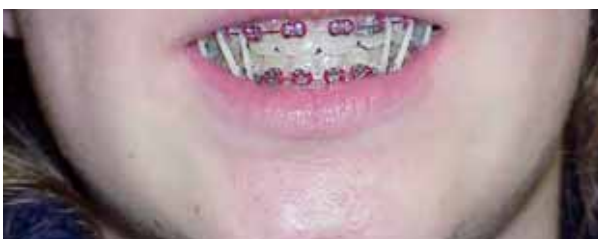From now on, if the bite doesn't close down, then the patient is not wearing the elastics 24/24 as directed. Motivation efforts were made towards the patient.



16TH MONTH

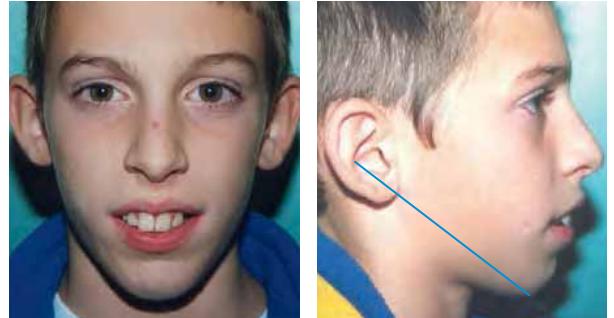

Patient will continue with this combination of bite closing elastics until the final finishing.

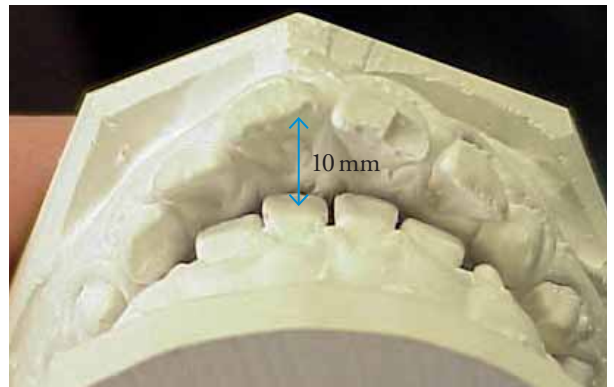
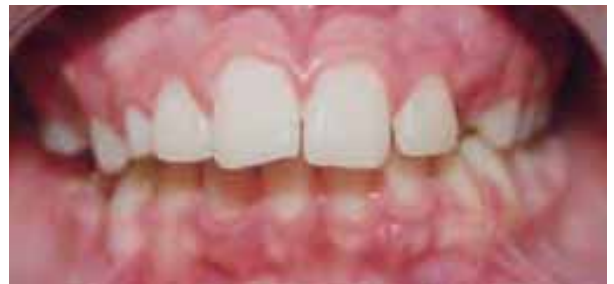

16/14. CASE: Pr, boy,
11.5 years old

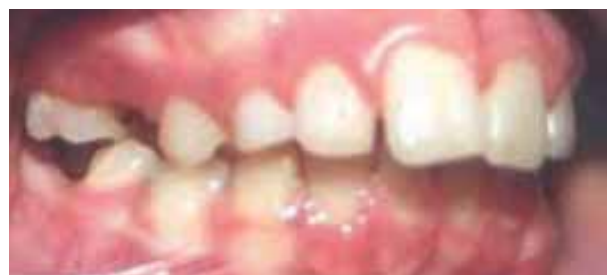TP: use of NiTi Transpalatal appliance, High-pull HG, NiTi CLII Corrector and elastics to treat: CLII div I, OJ = 10 mm, OB = 6 mm. Dolichocephalic, vertical growth pattern, convex profile. High MPA. Soft tissue dysfunctions and mouth breathing.

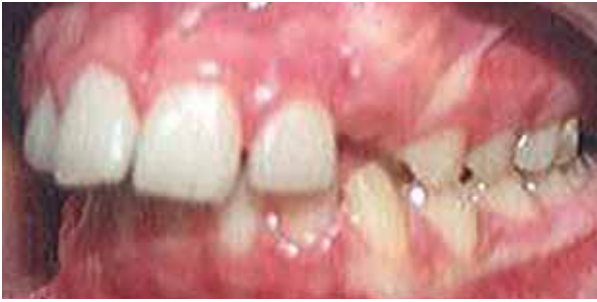

Vertical Maxillary Excess.

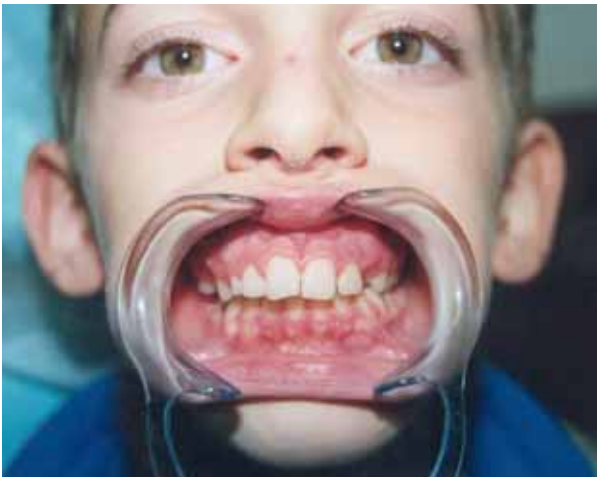

Full CLII dental and skeletal with Vertical Maxillary Excess (posterior segments are vertically lower than the anterior segment).



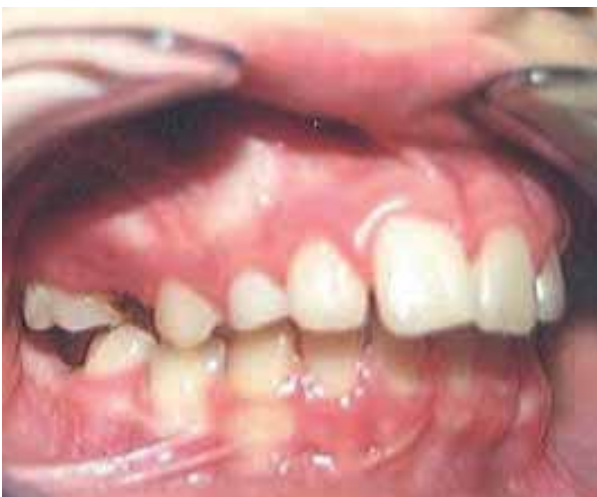

A “functional problem” case. Does not close his lips correctly when he swallows. Habitual mouth breather. He sucks in his lower lip to close the anterior space. Buccal segment collapse and posterior tooth extrusion due to hyper-active cheek and lip muscles.



Vertical Maxillary Excess

A fixed functional appliance, such as the **Nitanium CLII corrector** (NCC) can be added to the SWA and is recommended for skeletal CLII cases where the ability to correct a CLII occlusion without extrusion of the posterior teeth (such as with CLII elastics) is an advantage. NCC is used as well for non-cooperative patients who don't/won't cooperate wearing CLII elastics.

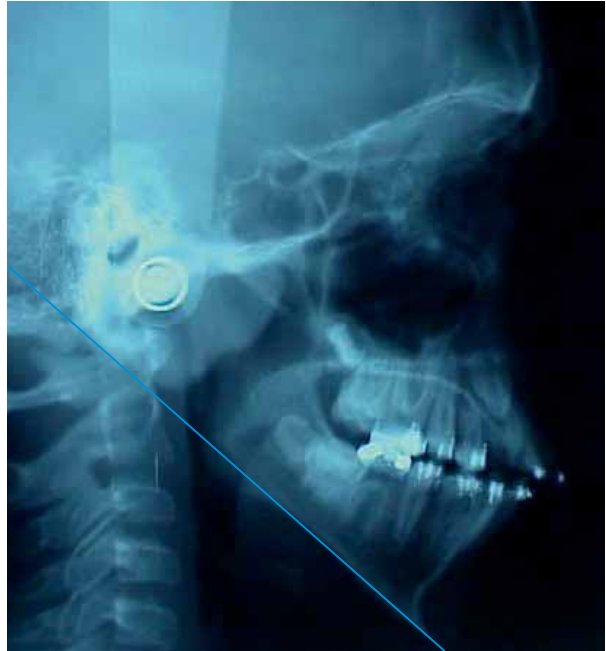

Steep MPA (46°)

Vertical growth pattern – Clockwise growing mandible.

Patient is a habitual mouth breather, and never has proper lip posture or closure.

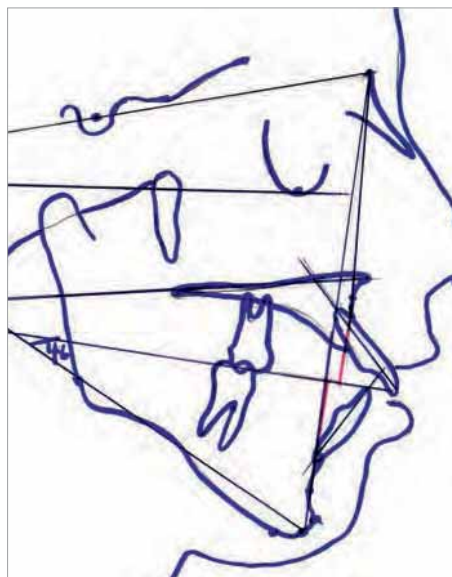
Lip closure exercises such as: close the lips on a large button, and breath through the nose. This should be done by the patient $\frac{1}{2}$ hour per day. Helps to advance the MAND.



This is more of a vertical problem than an A-P problem.

Wits = $+3$ MPA = 46

Palatal, occlusal and mandibular planes converge just behind the ramus.



SNA 76°

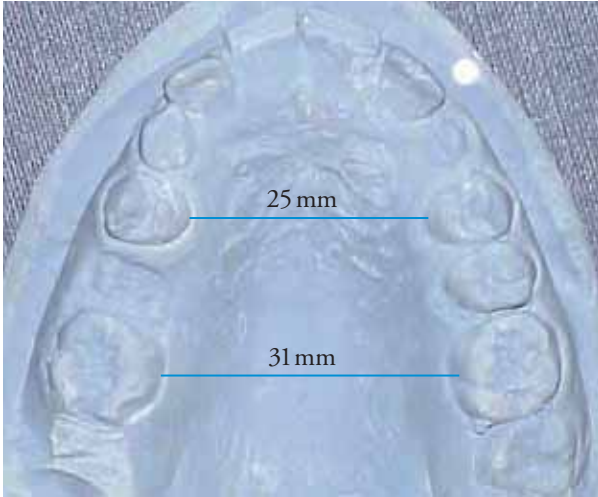
ANB 3°

MPA 46°

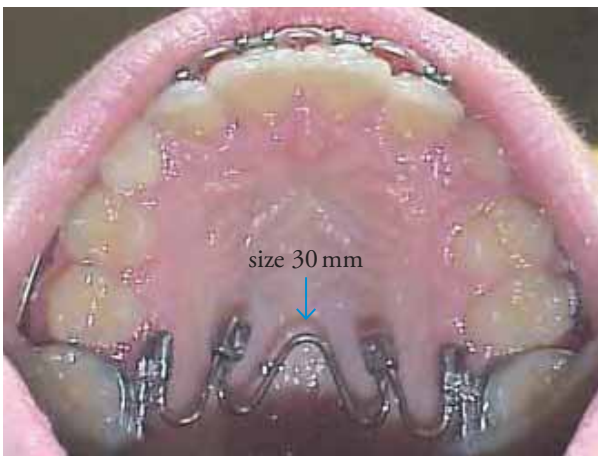
SNB 73°

Wits $+3$

Beginning model: V-shaped MAX with mesially rotated molars. Inter-Molar width = 31 mm.

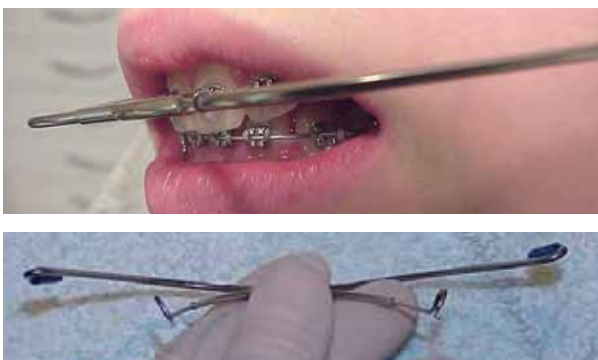


After 2 months of rotator wear: Arch is U-shaped, incisors are retracted, molars are pushed disto-vestibularly.



High-pull HG is placed and adjusted so that the pull force is disto-vertical and through the Center of Resistance (CoR) of the maxillary 1st molar.

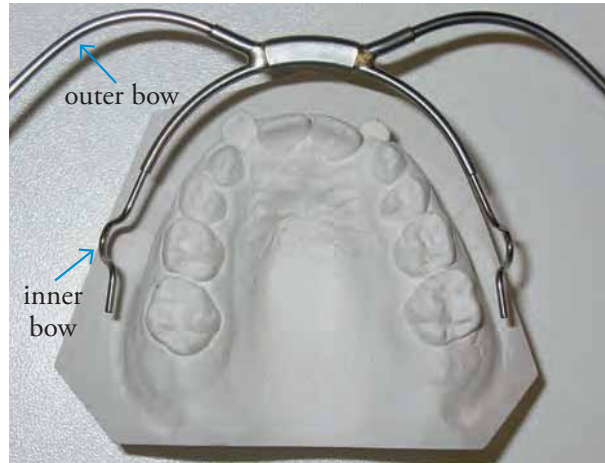
GM creates differential jaw growth: As the maxilla is restrained, the mandible can “catch up” by growing forward and upward.



HEAD GEAR

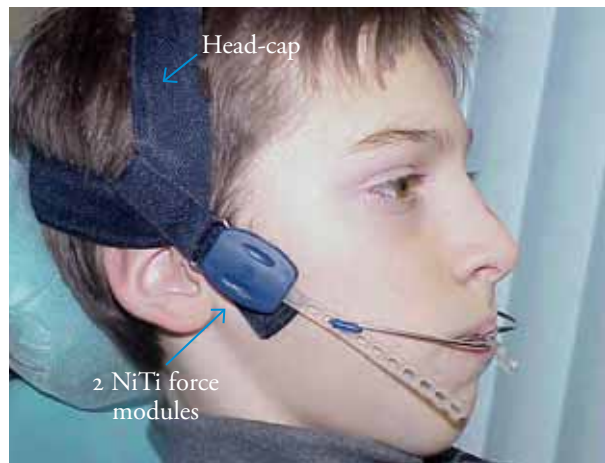Head Gear is composed of:

- A facebow with an outer bow and an inner bow.

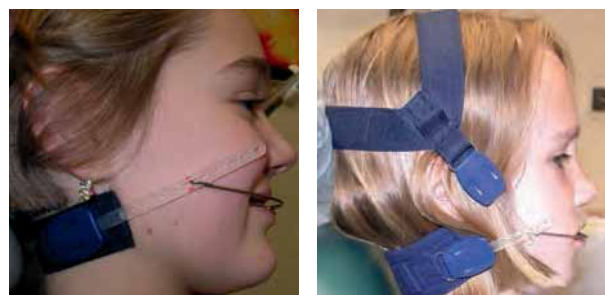

- A head cap, neck-strap to provide different directional vectors of force traction (occipital, cervical, combi).
- 2 NiTi force modules with a “measured” magnitude of force.

Occipital (or High-pull) head gear for growth modification of the maxilla and for vertical anchorage. ♡



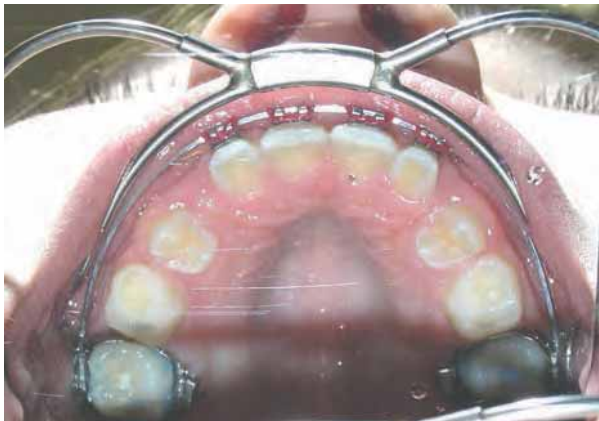Cervical and Combi HG are used for distalization of the maxillary 1st molars. ♡ ▽



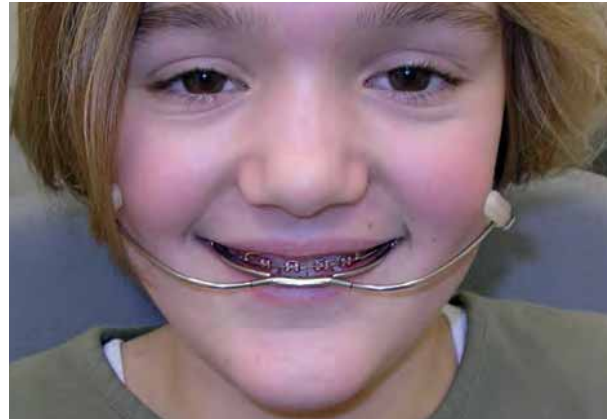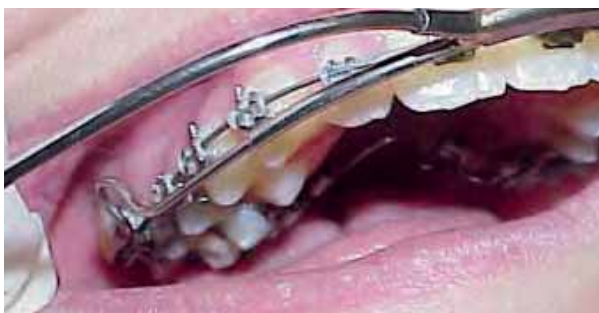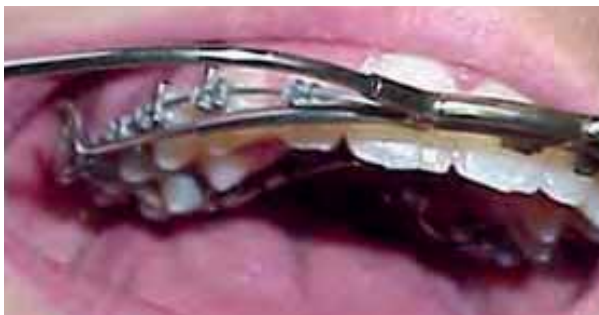FITTING THE OCCIPITAL HG

Adjust and fit the facebow's inner bow first:

- Facebows can be obtained in different sizes, 1 to 7 with the 7 having the longest and the widest arms of the inner bow.
- When choosing the size, make sure that when the distal extensions of the inner bow are placed into the molar tubes, it does not touch the brackets of the other teeth (should rest 2 to 4 mm away from these brackets). Fitting is accomplished by adjusting the inner bow: the Omega loops and the distal extensions.
- Sometimes the whole inner bow must be widened or made less wide using pliers and/or the fingers.

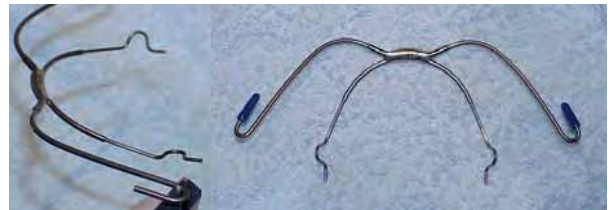


- Clinically, one side is placed in the molar tube then the second side is placed. Before placing the second side, make sure that it is adjusted so that the distal extension rests passively 1 mm more buccally than the molar tube. Thus, the inner bow must be compressed slightly when being inserted in the tube. This helps in the retention of the facebow in the tubes.

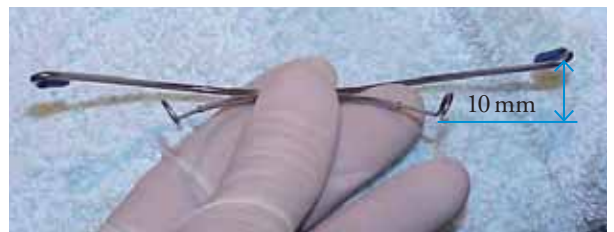

Adjustment of the outer bow of the face bow:

- The attachment hooks should be the same length as the CoR of the maxillary 1st molars.
- “Special Short Outer-bow”: it is easier to use a facebow with short outer-bow because the arms of the outer bows approximate the length of the distal extensions of the inner bow, thus the “attachment point” of the outer bow is already close to the same level as the CoR of the M1s.

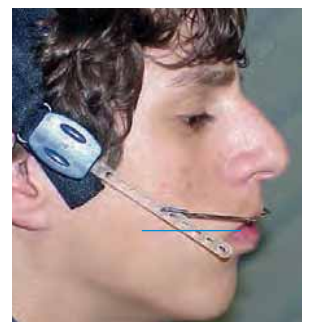
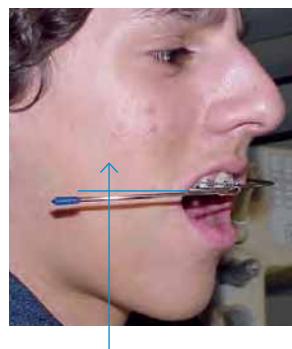
- It is necessary to bend the arms of the outer bow upwards so that the attachment hooks are ~10 mm higher than the distal extensions of the inner bow.



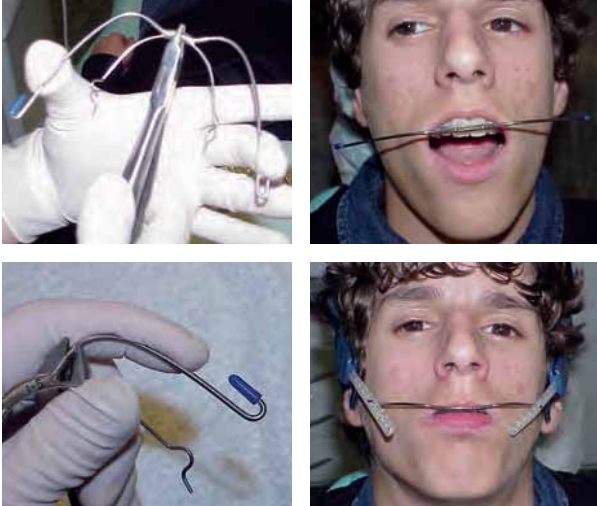Before adjustment ▼

After adjustment ▼



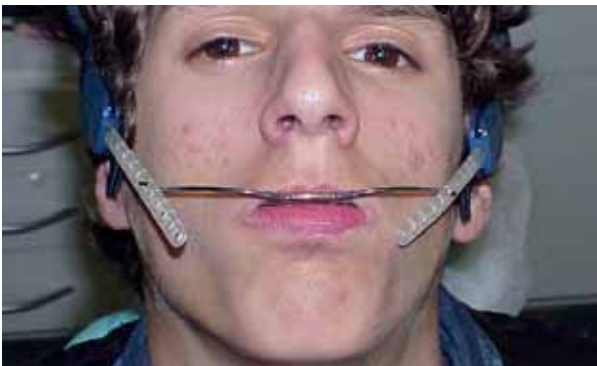Imagine the CoR of the 1st molar on the cheek.

- Bend the arms of the outer bow so that they rest close to (but not touching) the cheeks. Patient has to sleep with this.

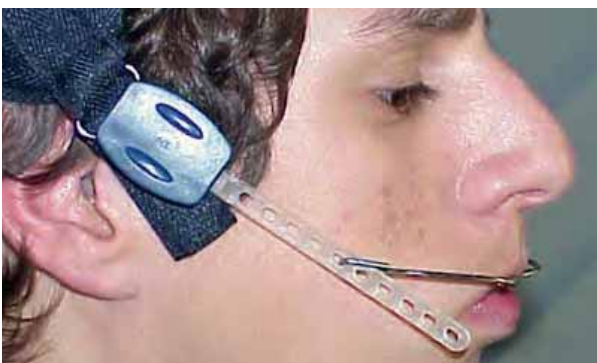

Adjusting the head cap and the NiTi force modules straps:

- Choose the force module with the desired magnitude of force needed: in this case 600gr per side.
- The modules are attached to the head cap.

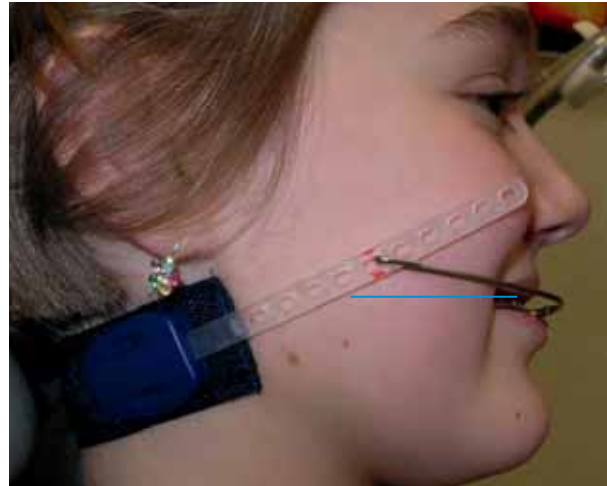


- Place the facebow in the molar tubes. The head cap with the force modules is positioned on the head. The straps of the modules are passively held next to the attachment hooks. Then pull the straps downward “2 holes” and attach the holes onto the facebow hooks. One must consult the manufacturer’s guide to regulate the force levels.



With this adjustment, the force passes through the CoR of the MAX 1st molars.

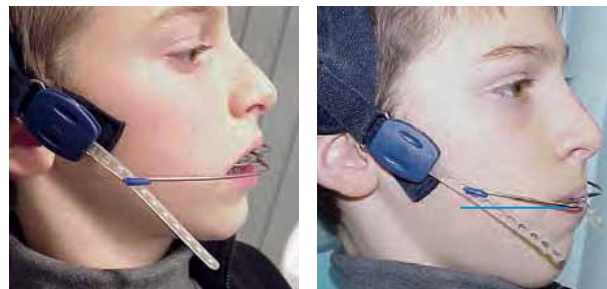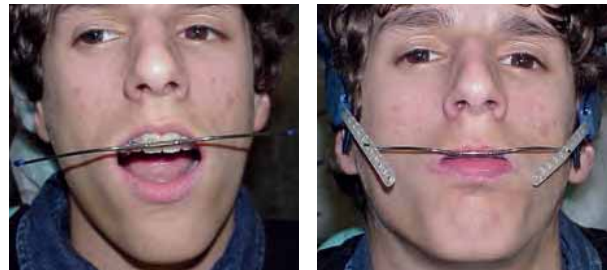Blue = occlusal plane.



- Before the patients leave the office, they must show that they understand what needs to be done and that they can place and take-off the HG. For growth modification, HG is worn 16 hours / day. Check 1 week.

Before adjustment ▼

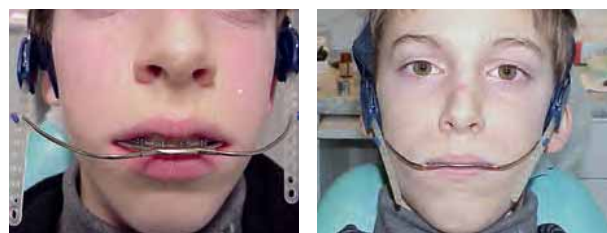
After adjustment ▼



Before facebow adjustment

After adjustment ▲▼

▲▼



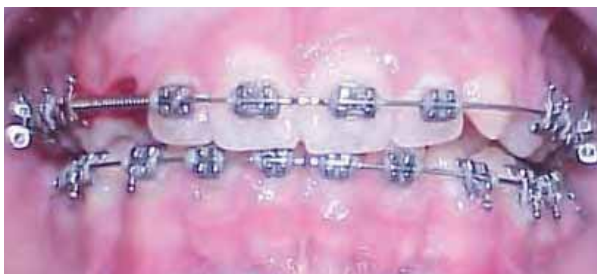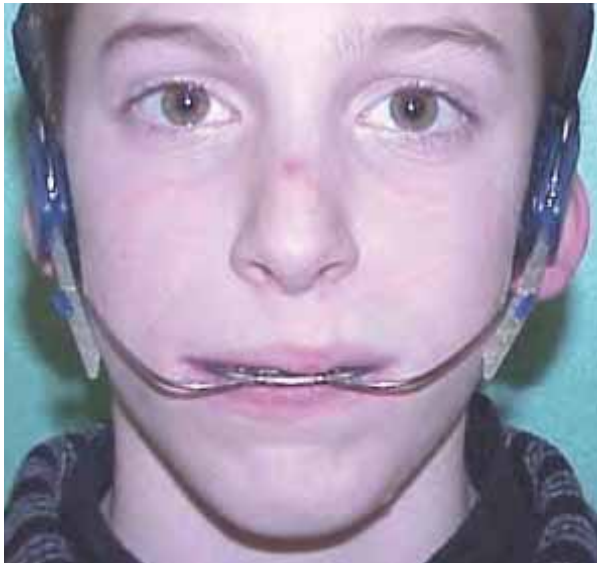6TH MONTH

High-pull HG: 600 gr force/ side NiTi, 16/24 (“at home hours”).

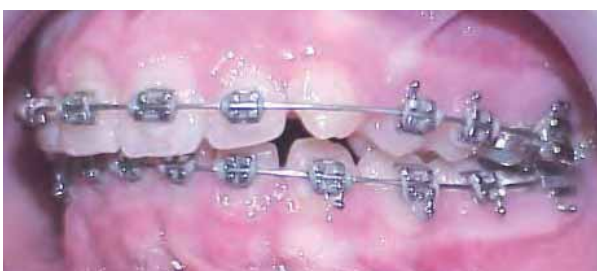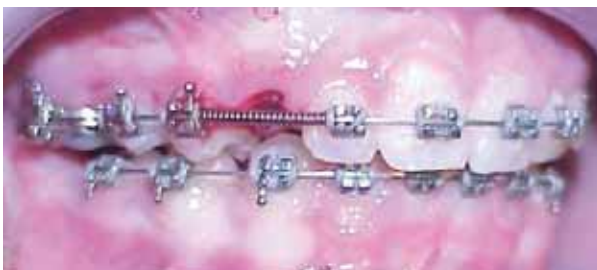MAX: Extracted 53, bracketed 25. Placed 19X25 HA NiTi.

MAND: Placed 19X25 HA NiTi.

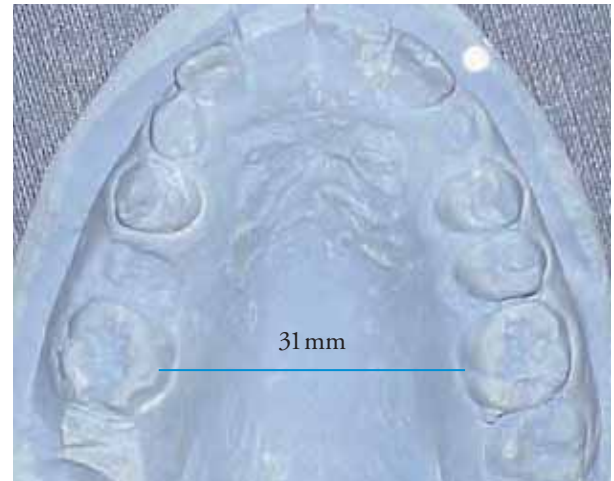
Mandible can now posture forward towards the “new CLI bite” with the mid-lines aligned.



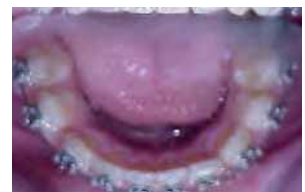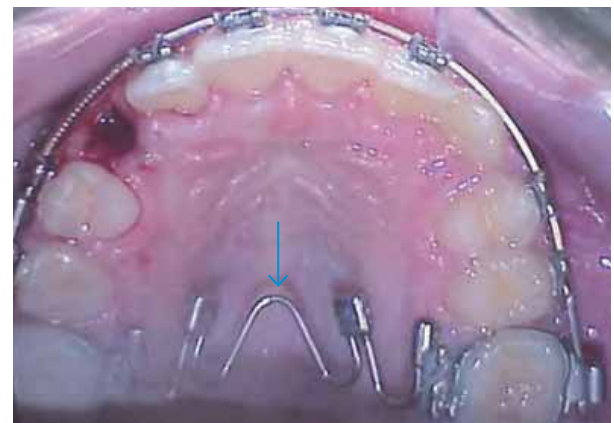Patient is posturing forward with lip closure. MAX: 010x030 O-C spring is used here for holding the space for 13.



Effect of wire BBs combined with the NiTi rotator: the V-shaped arch form becomes U shaped, wider and shorter.

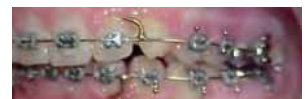
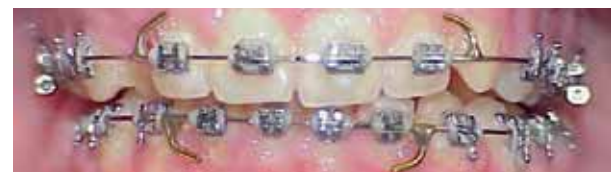
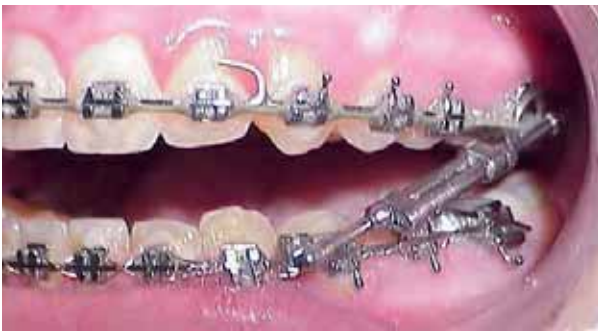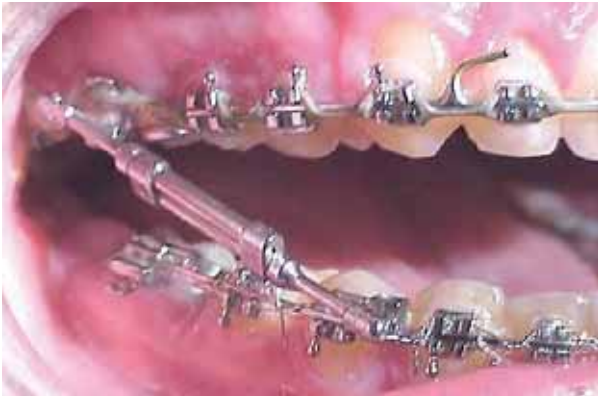Rotator (size 30 mm) ▼



7TH MONTH

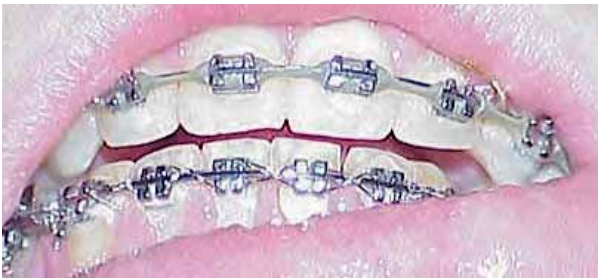MAX & MAND: N. 19x25 posted steel. These wires finish the levelling.



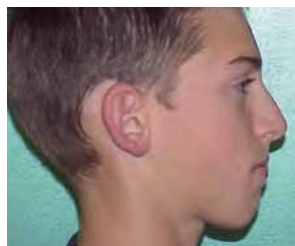
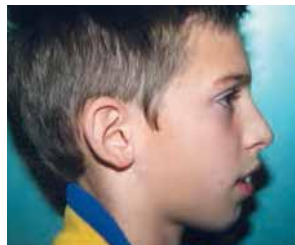
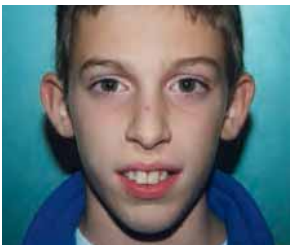21ST MONTH

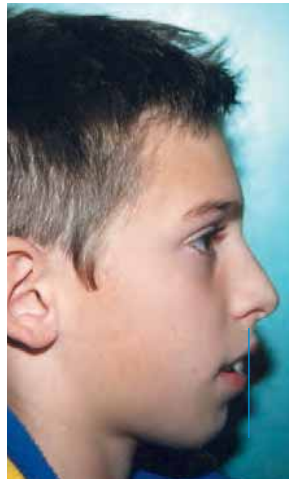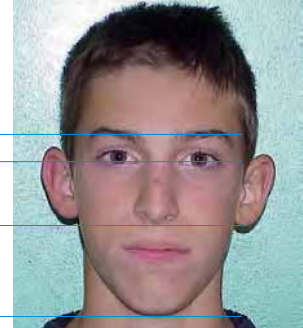
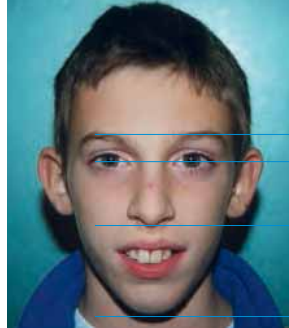Check progress at 2 months. Place mandible in CR: OJ is reduced. In relaxed position, patient is end-to-end.



Lip-closure.



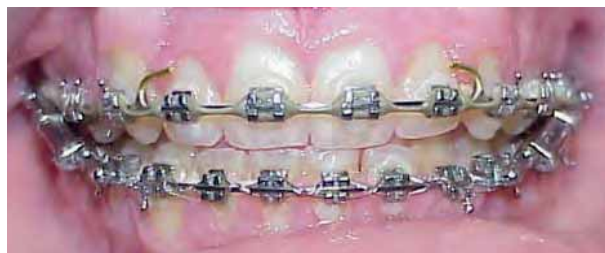In all cases of “habitual mouth breathers”, when the MAND is held forward in a CLI position by the NCC, there is Automatic Lip-closure



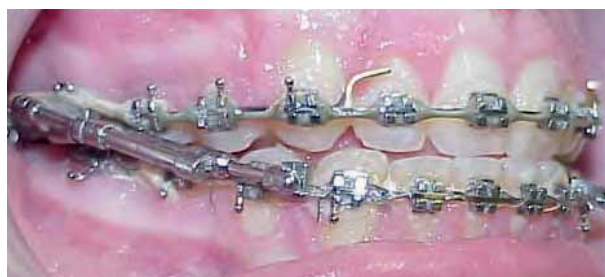23RD MONTH

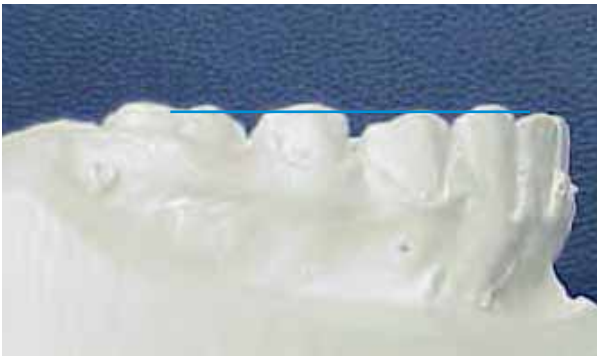
CLII malocclusion has been over-corrected into a slight CLIII.

NCC is removed after ~4 months use.

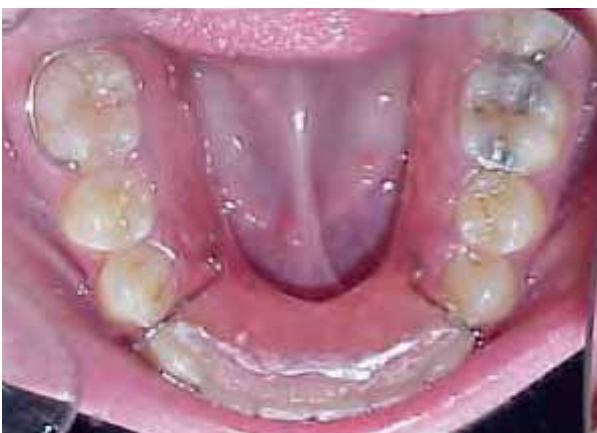
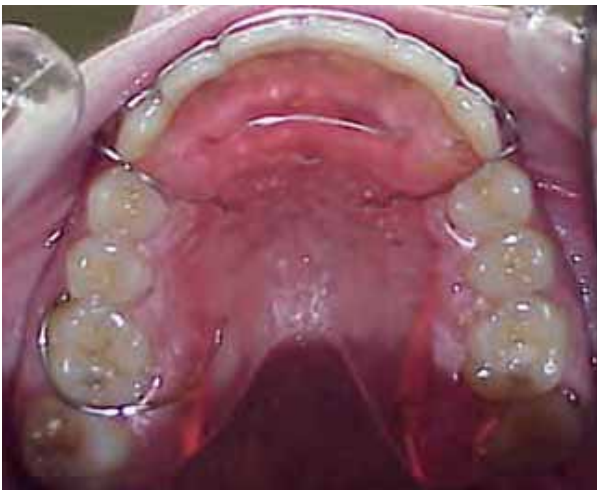
Always over-correct into a slight CLIII.



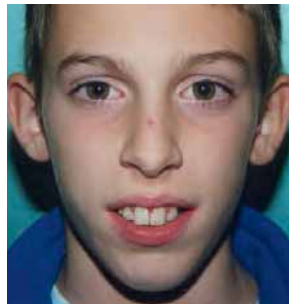


RECALL: 6 MONTHS



RECALL AT 12 MONTHS

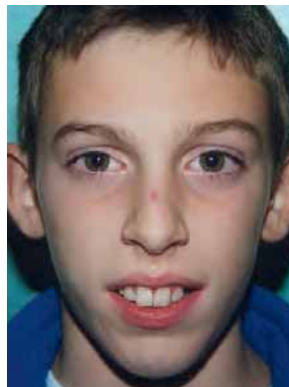Age 14.8 years

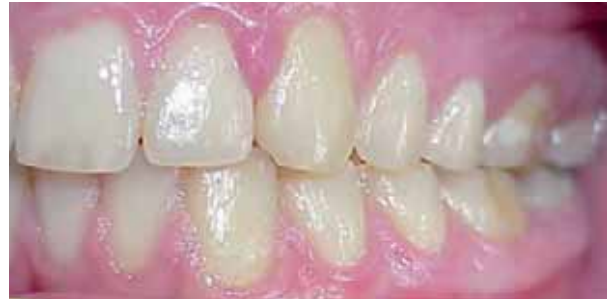

Age 11.5 years 

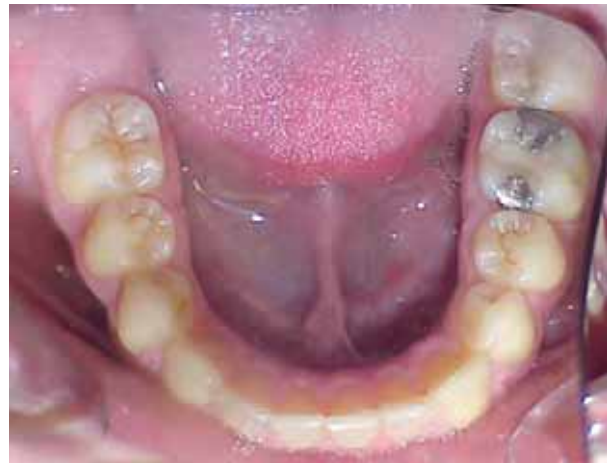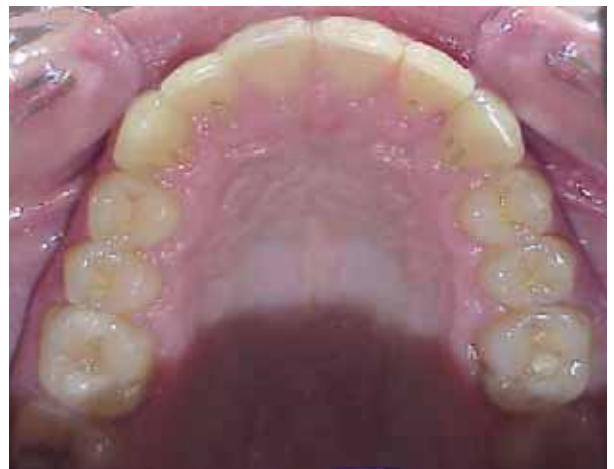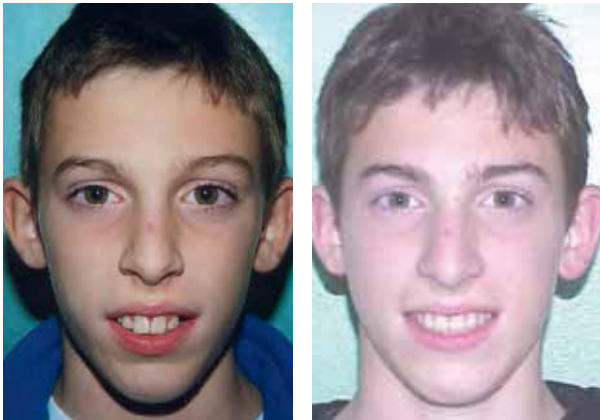RECALL: 24.5 MONTHS

Age 16.5 years

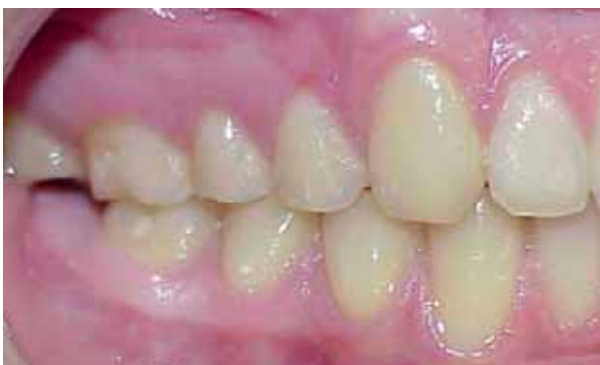


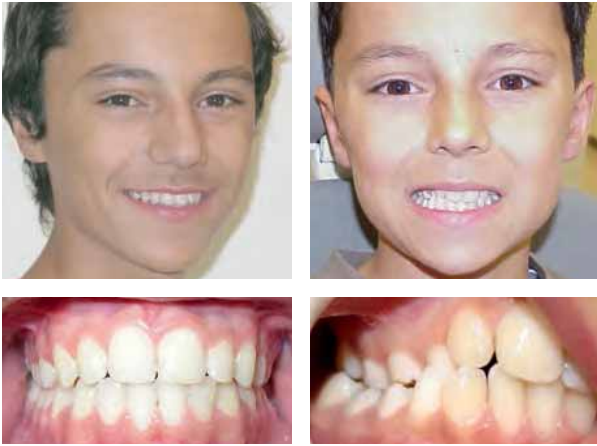
MAND: Fixed wire is no longer in place. But as the patient continues to wear the Hawley retainers at night, there is no crowding of the teeth. ▼



Good inter-digitation. Posterior teeth are “longer” as they reach the adult eruption level.





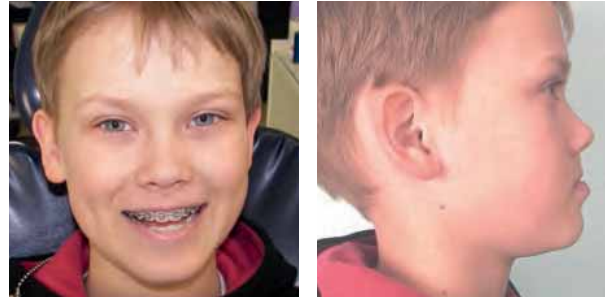15 years old

There is harmony of the lips, teeth, jaws and face. The smile fits the face. The smile is correct as the edges of the MAX incisors just touch the vermilion border of the lower lip and the gingival margin does not show. The bracketing scheme 2 is responsible for the Smile Look. Profile is CLI with good proportions.



17/3. Case: Jn, boy, age 13 years

Severe CLIII Skeletal/Dental. Bilateral posterior & anterior x-bite due to previous orthodontic treatment that was improperly done. TP: use of NiTi Expander and CLIII elastics to resolve, non-extraction, the CLIII occlusion with X-bite.

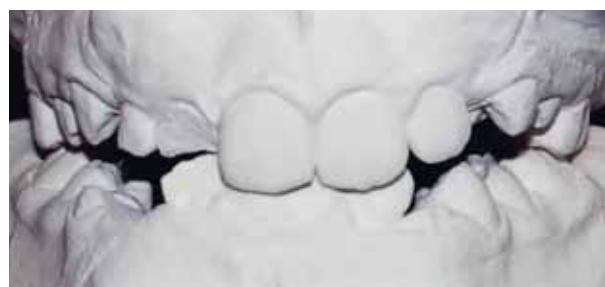

2 years previously, a practitioner tried to "gain space for the canines", but made a poor diagnosis not recognizing that at the beginning of treatment, if the MAND incisors are lingually inclined, and there is a CLIII skeletal base, one must be careful because if the lower incisors are ligatured to the wire, they will rapidly tip forward into a CLIII position with a X-bite. This creates a MAND slide, and this is what happened in this case.

Beginning study models from 2 years previous ■ ■

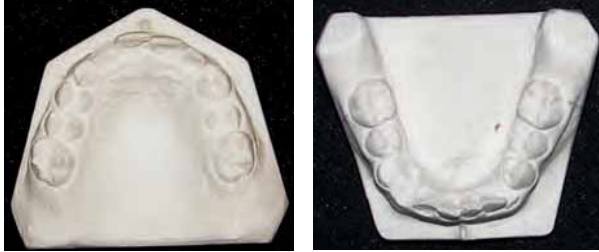

A safer strategy for cases such as this: always start on the MAX arch in order to correct posterior X-bite and generally widen and develop the arch form so that the MAX can contain the MAND in a final CLI position. This also makes room for 13 & 23 and increases the anterior OJ. After several months (depending on the case), the MAND will be freed up and can re-center in a neutral condylar position. Only now is the lower arch started and leveling should be done using BBs on the leveling wires. By following these steps, a mandibular slide is avoided. After leveling, the case is re-evaluated for further treatment protocol.



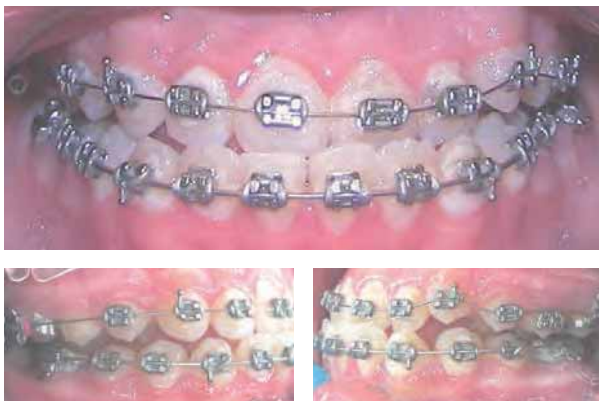Original beginning models:

Space missing for 13, 23 and 33, 43.

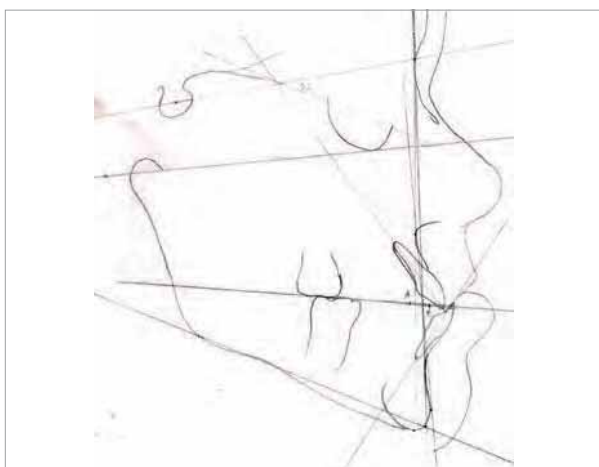


The situation when patient came into the practice. ♥

Space was gained for the canines, but a CLIII occlusion with MAND slide was created by the rapid forward/labial tipping of the MAND anterior teeth: the MAND is forced forward and this traumatic force on the anterior teeth has caused their abnormal forward tipping.

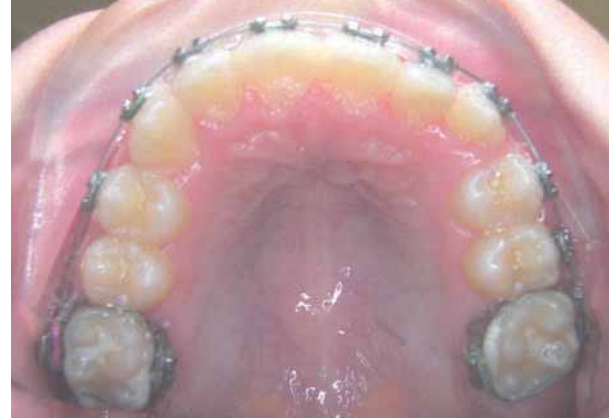

Not only is excessive growth of the mandible stimulated by the MAND slide, but maxillary growth is retarded/slowed down by the anterior X-bite. Creates the CLIII Look.

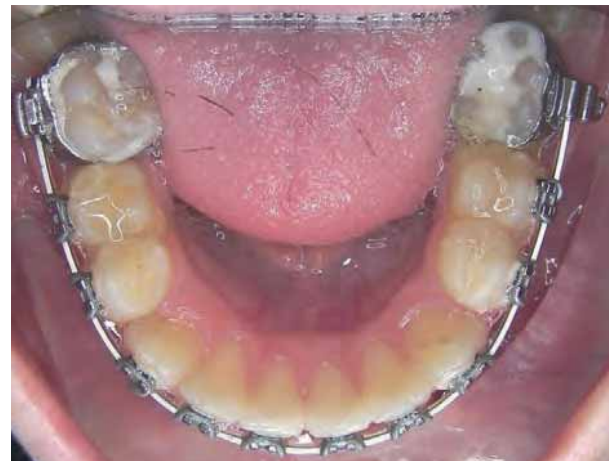

SNA 78°	Md1 - NB 9 & 36°
SNB 82°	Md1 to A-pog +9
ANB -4°	MPA 32°
Mx1 - NA 9 & 36°	Wits -5.5

{If the CLIII can't be corrected non-extraction: possibility of slicing or extraction of 2 MAND teeth to create space in order to retract the MAND anterior segment.}

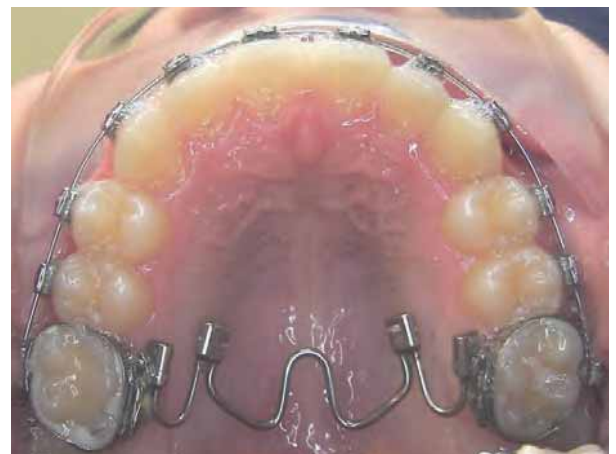

Global TP for the resolution of these problems: Expand the MAX arch so that it can contain the MAND in a final CLI occlusion. Retract by tipping/torquing the crowns of the MAND anterior segment. CLIII elastics.

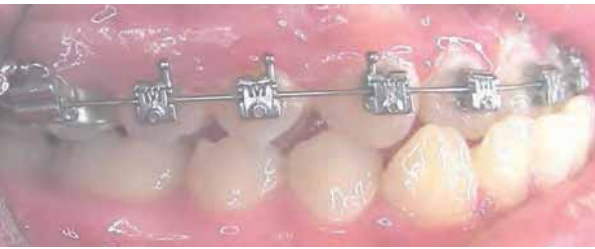
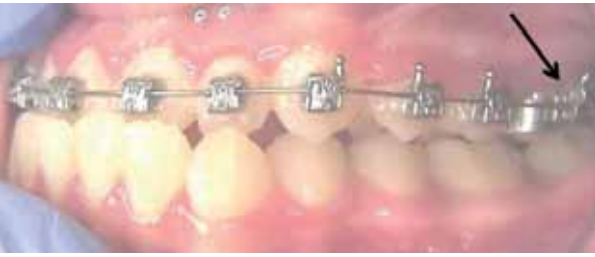
1ST MONTH

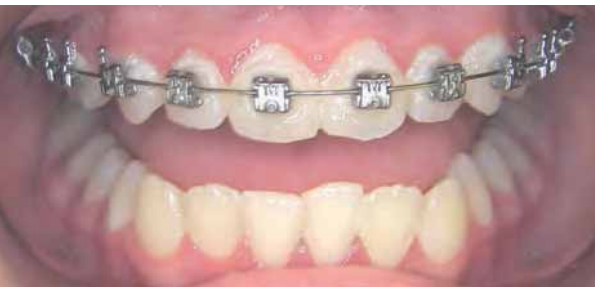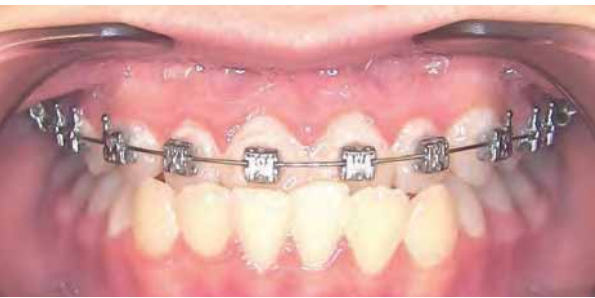MAX: NiTi Rotator 2 mm larger than the inter-molar width.



Anterior cross bite 26 & 37 (arrow) and CLL under-bite.

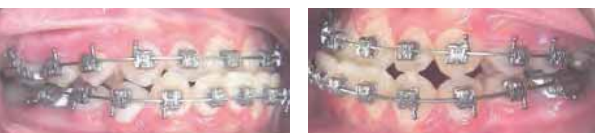
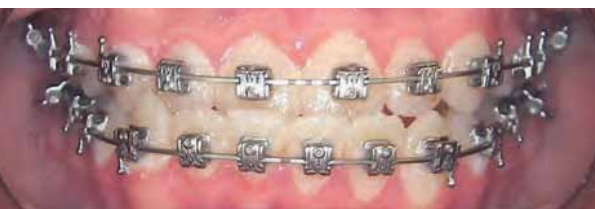
Severe CLIII under-bite. ♥



6TH MONTH

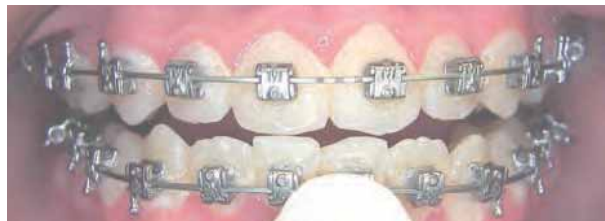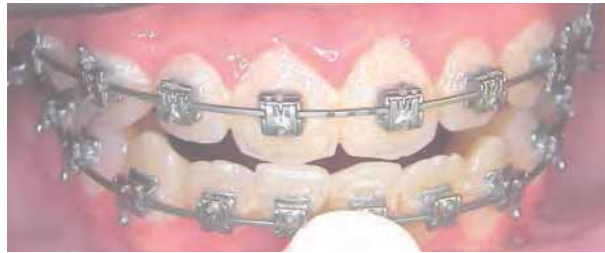MAX & MAND: 19x25 HA NiTi. Full CLIII molar and canine w/ mandibular slide to the right.



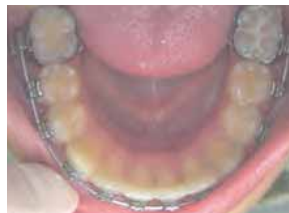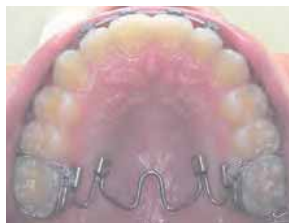MAND in CR with the M-Ls aligned: ♥

This shows that the MAX can contain the MAND in a CLI position so that the CLIII could be corrected. However, in CR, one could not obtain an end-to-end incisor position.

Prognosis: will be difficult to correct the CLIII with non-extraction therapy.



CLIII look.

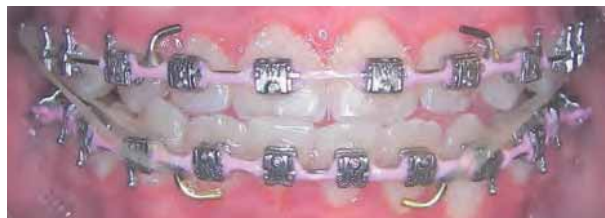

8TH MONTH

MAX: 19x25 posted steel wire, flat.

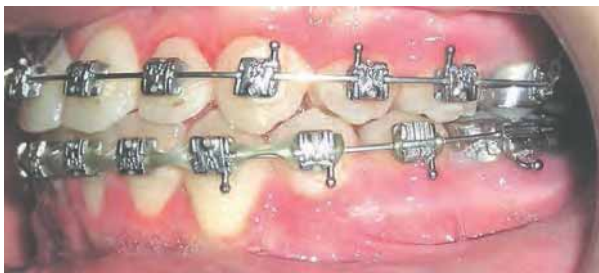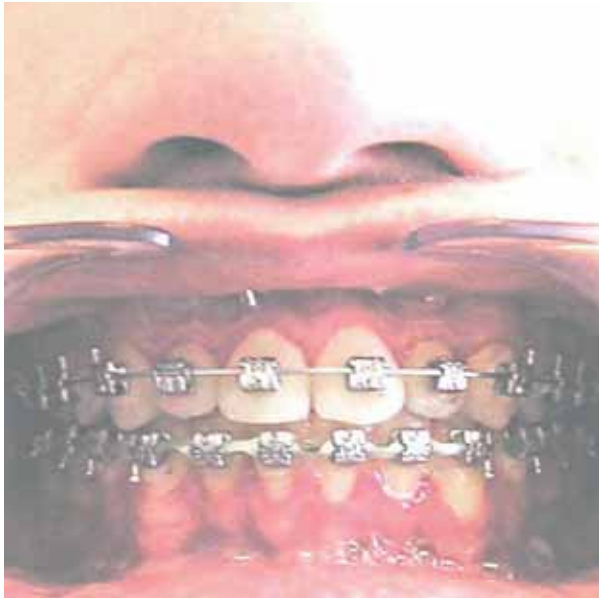
MAND: 19x25 posted steel wire, flat, LL chain 36-46. Strip-ping from 33-43.

Start CLIII elastics, 10 mm, attached from 16 & 26 to MAND posts, 24/24.



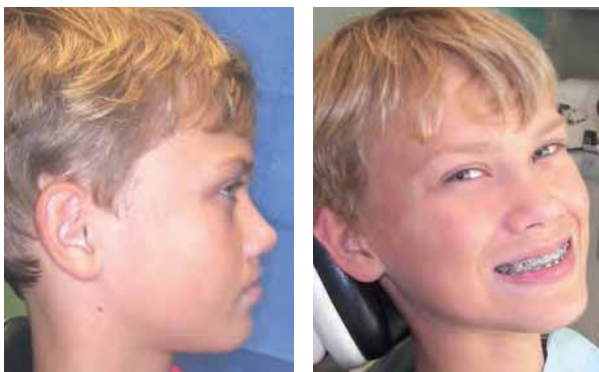MAX: M-Ls are aligned. Bite is settling-in.

MAND: light stripping 33-43 at each visit with N. L-L CH to help "upright" the incisors.



Profile has improved.

The upper lip looks more full with a CLI smile.

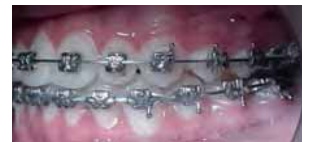
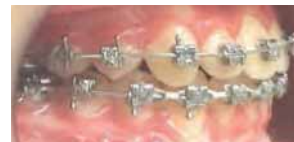
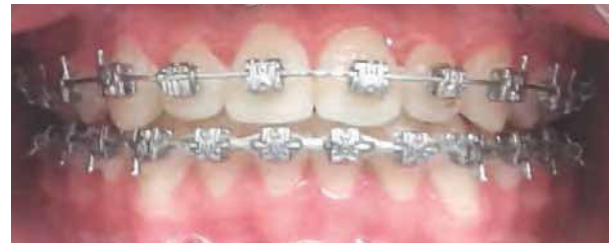15TH MONTH

M-Ls are aligned

MAX: Same. Posterior delta elastics to settle-in bite.

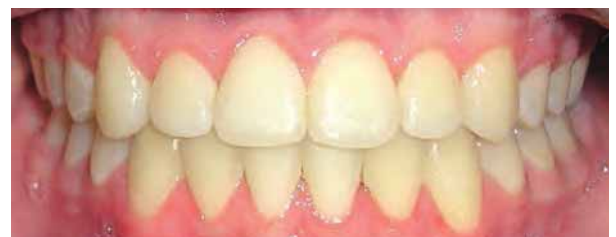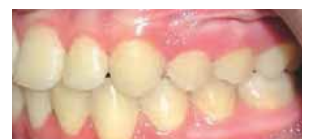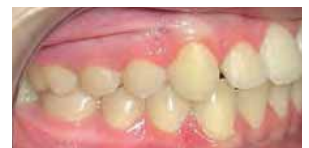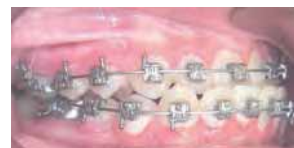MAND: same 19x25 NiTi with 20° lingual crown torque. Stripping and N. L-L CH. Wires to remain in place 3-6 more months to evaluate the stability of the occlusion.



24TH MONTH

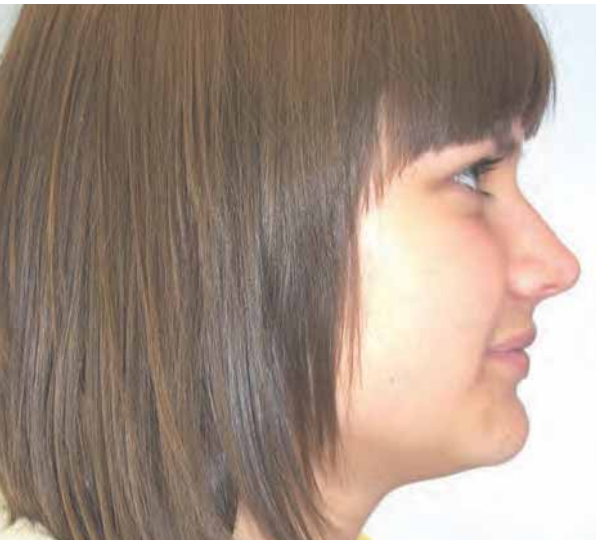Patient is 15 years old

Remove SWA. MAX & MAND: Fixed lingual retention wires. Removable Wrap-around Hawley retainers.

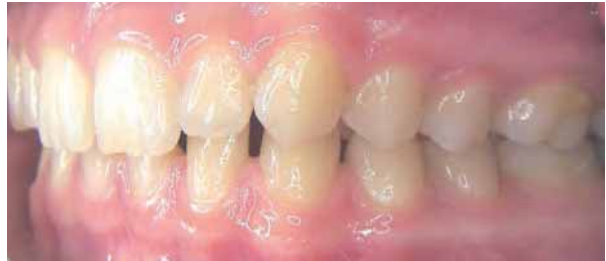
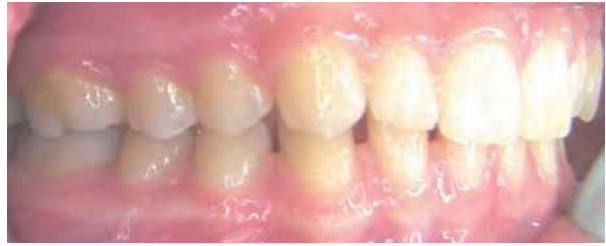
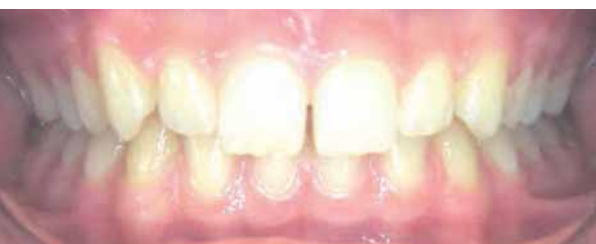**20/8. Case: Pa, adult (17.5 years).
Treatment plan: "non-extraction
camouflage CLII"**

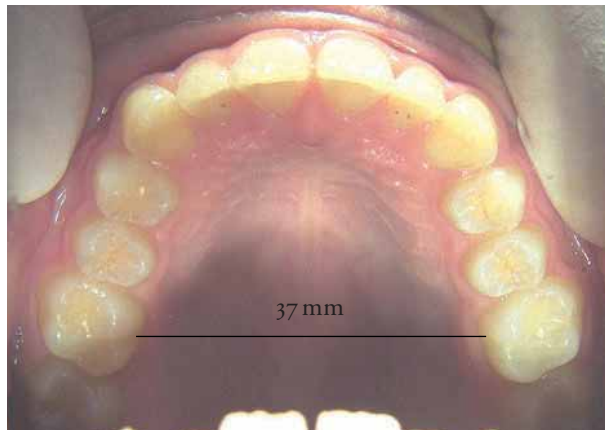
$\frac{3}{4}$ CLII div II. OB = 5 mm. Short face, MPA = 33°. Wits = +3.5. Patient doesn't like her smile.



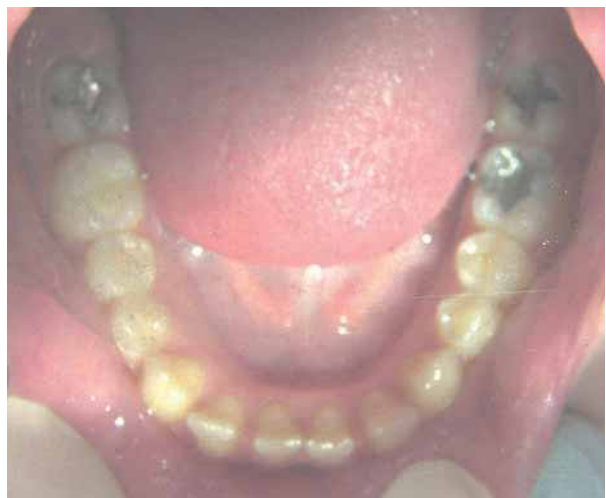Esthetic diagnosis: MAX incisors are lingually tipped and the face is concave, thus one can advance the MAX front teeth to provide a nicer smile and improve the fullness of the lips. However, the lower dental arch will then have to be advanced into a CLI position.

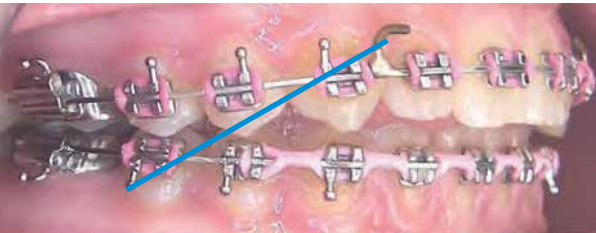
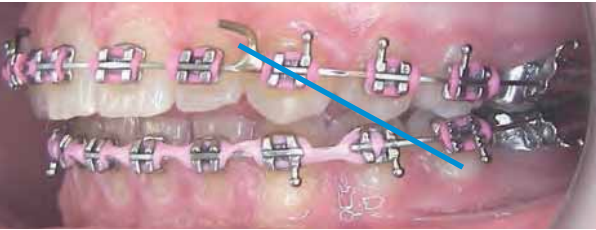
V-shaped MAX with a distal-occlusion. MAX incisors are lingually tipped. During leveling the MAX incisors will tip forward so that after leveling there will be an OJ of -4 mm.



The adding of labial-crown torque to the incisors and the widening during the leveling of the V-shaped MAX in the premolar/molar areas (molars are ML rotated) will improve the SMILE and overall Look.





There is a $\frac{3}{4}$ CLII with OJ of 5 mm. Due to the open-bite tendency: start with “Short CLII elastics”, 6 mm, 1 per side from the MAND P2s to the MAX wire posts. \blacktriangleleft

8.5TH MONTH

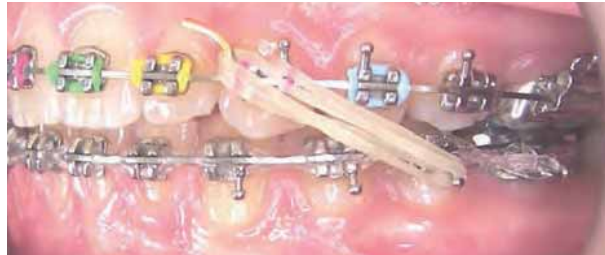
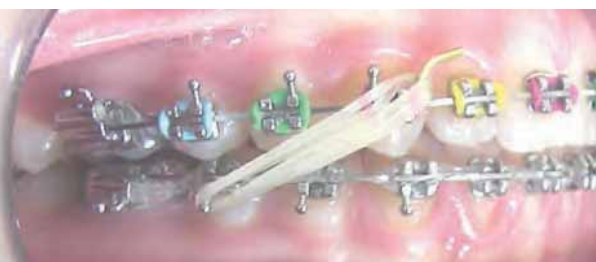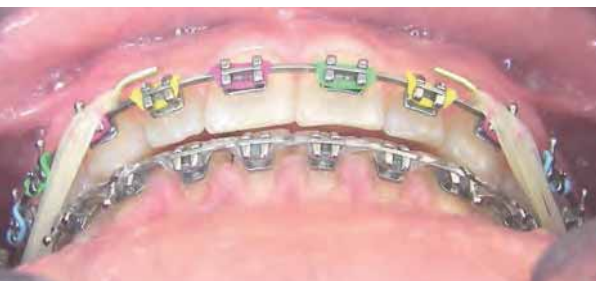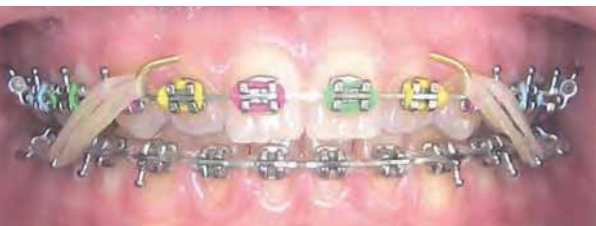OJ is reduced about 2.5mm.

After 6 weeks of Short, CLII elastics...

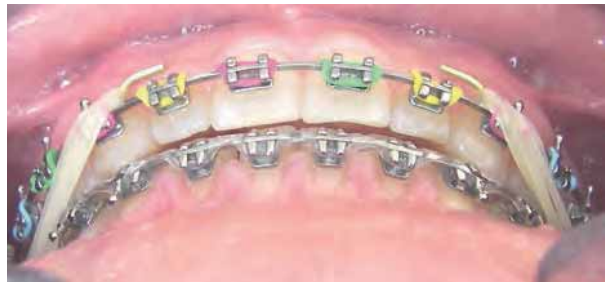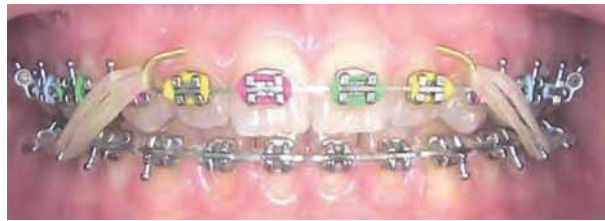MAX: molars are closer to CLI. 19x25 posted steel, flat, with 4 mm expansion.

MAND: 19x25 steel. L-L chain 46 to 36.

Continue Short CLII elastics, 6mm: change to 2 / side from 35 & 45 to posts, 24/24.



Short CLII elastics, 6mm \blacktriangleleft



10TH MONTH

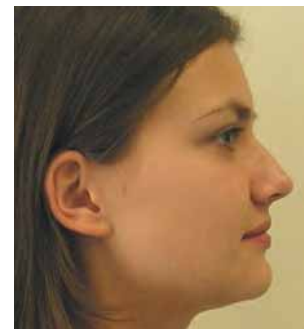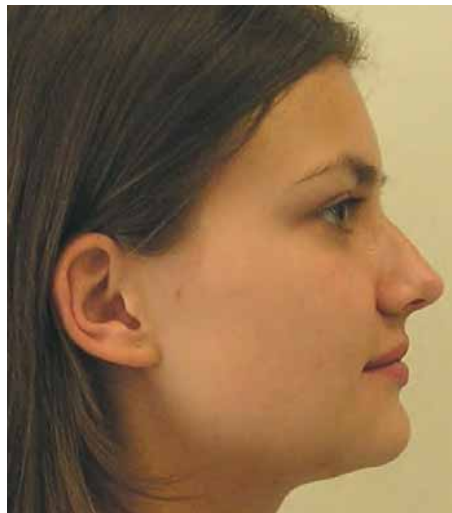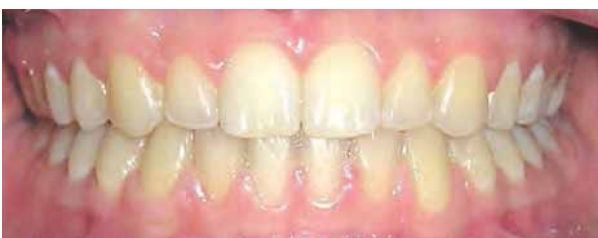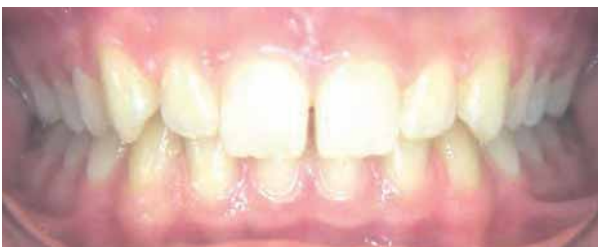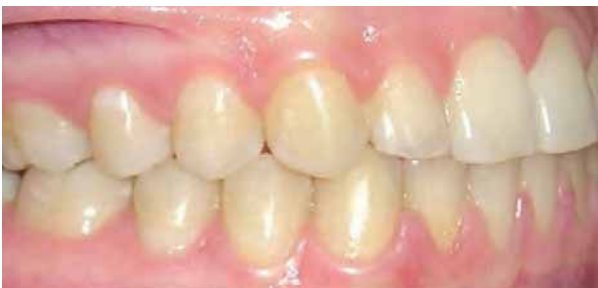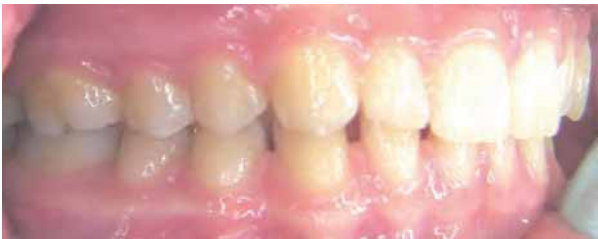MAX: Smile is nicer with the labial-crown torque and the widening of the MAX arch. IDEM: 19x25 posted steel, 4 mm expansion.

Change to normal CLII elastics, 6 mm, 2 / side, 24/24.

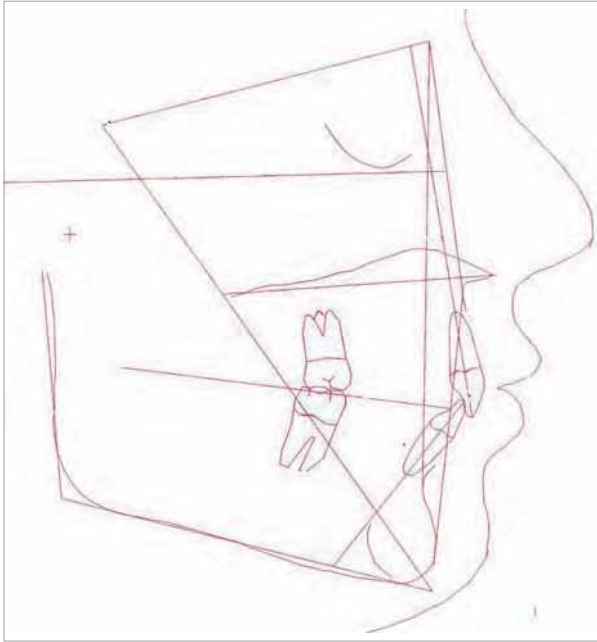




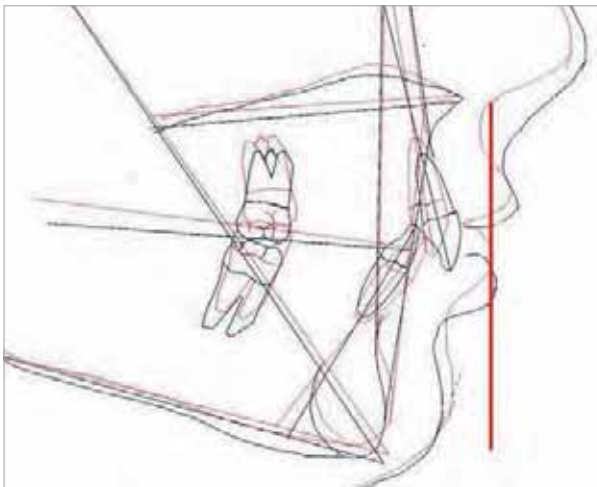
CLII has been corrected to a CLI without extractions.
The occlusion is a solid and stable CLI. ♡



The profile and lip posture are improved. ♡



Final ◆



Superimposition: Cranial Base ◆

Black – beginning ◆

Red – final ◆

■ Superimposition: Cranial Base

Mx1: intruded & distalized. OJ was reduced.

Md1: intruded; tipped forward +3mm.

MPA: no change.

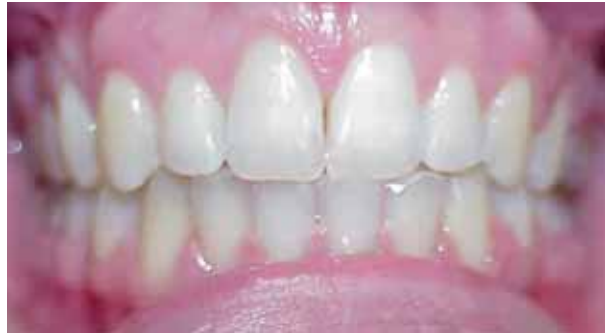
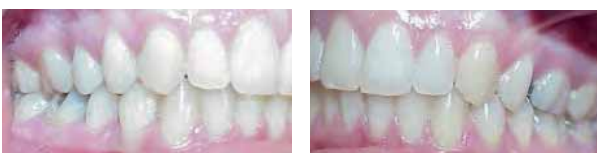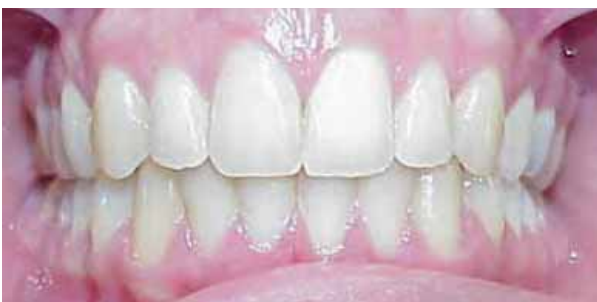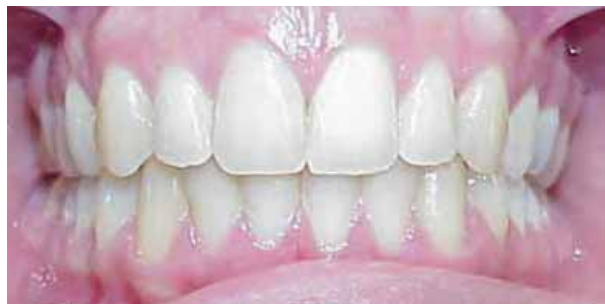There is “Lip closure”.

The upper lip is forward of SNV while lower lip touches it (ideal).

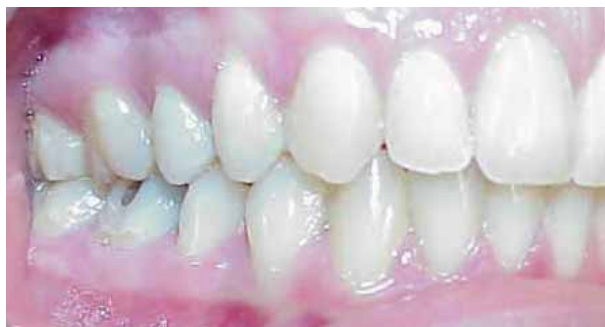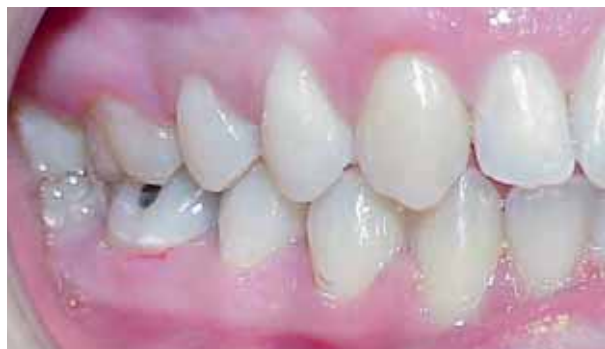+9 Wits remains the same, but it has been camouflaged.

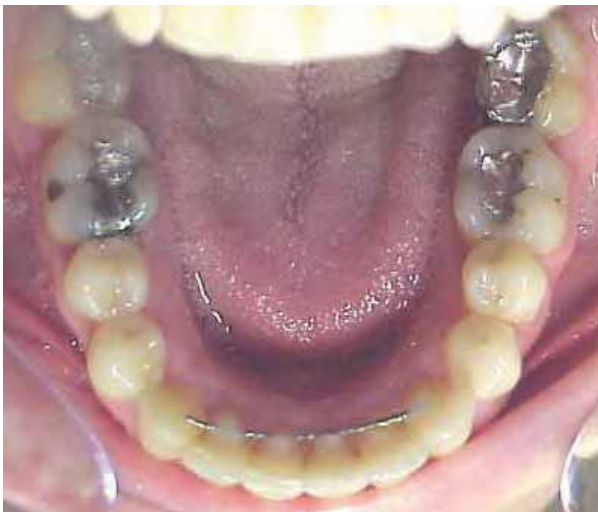
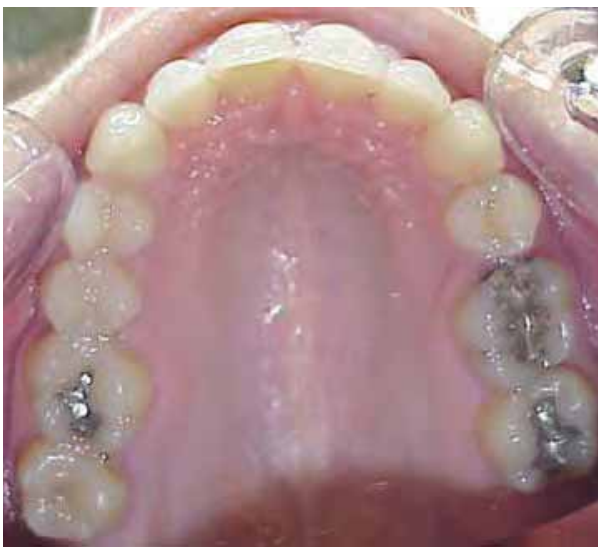
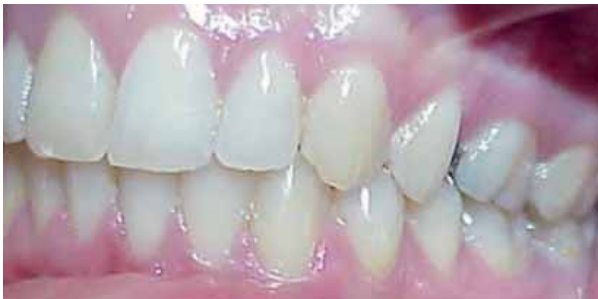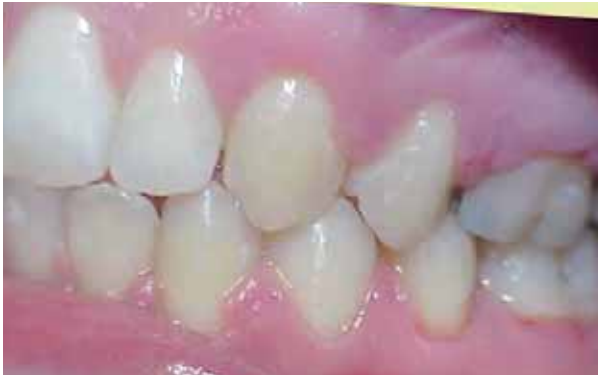Recall: 12 months ◆

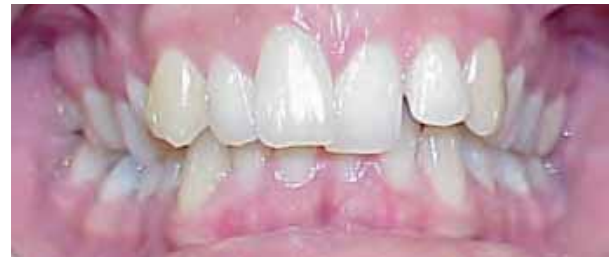End of treatment Recall: 12 months 

On severe deep-bite cases with deep CoS, bracketing scheme 1 is used to help open the bite and to allow for an over-corrected CLI position. As seen above, the incisors finished end-to-end while the posterior teeth were fully settled-in. At the end of treatment, the MAX incisors appeared too short compared to the canines & premolars. However, there is always a “rebound” of the incisors towards their original position. As can be seen here after 12 months, the incisors are now in a perfect position as this rebound was anticipated.

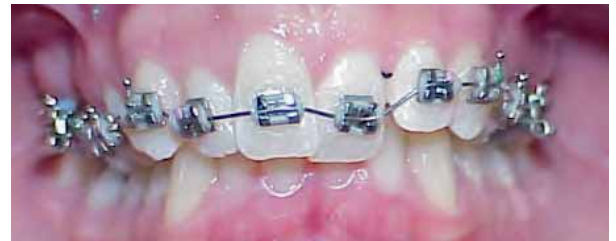



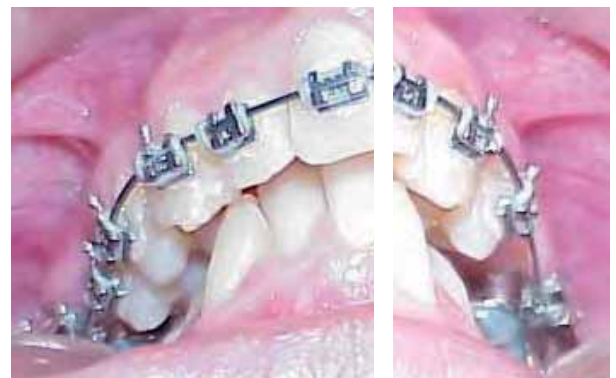REVIEW



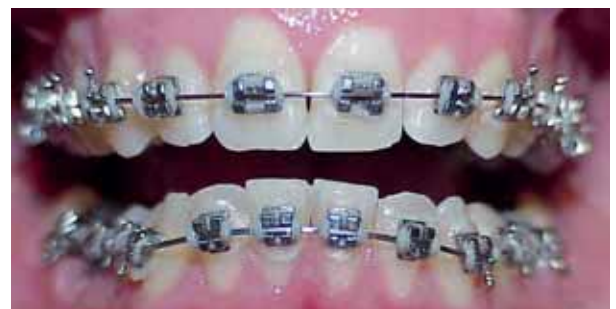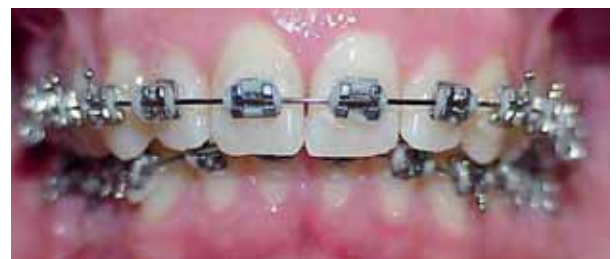Beginning ▲



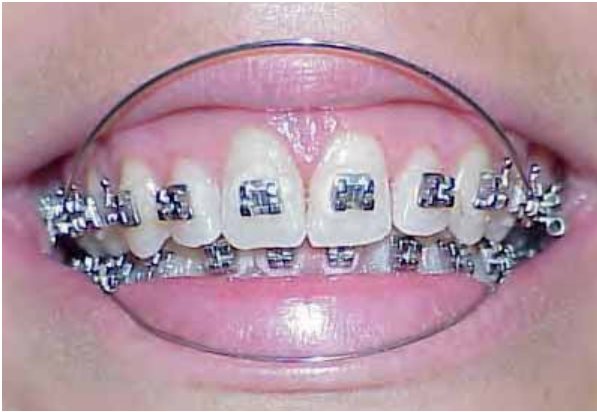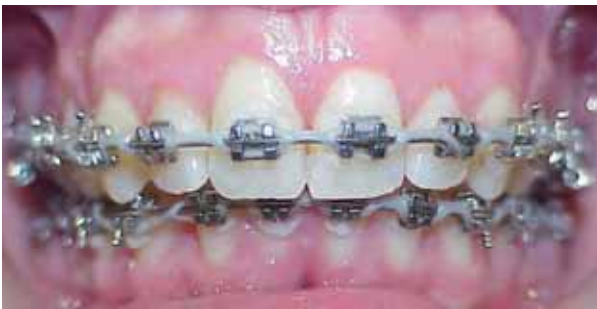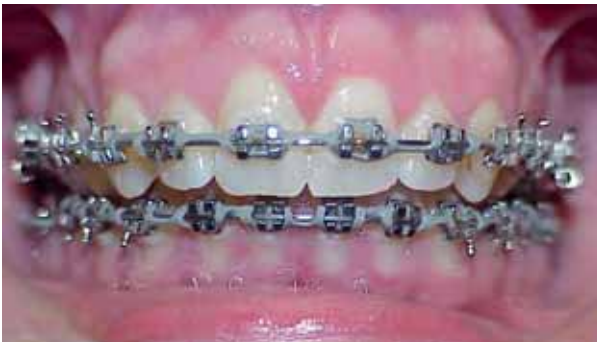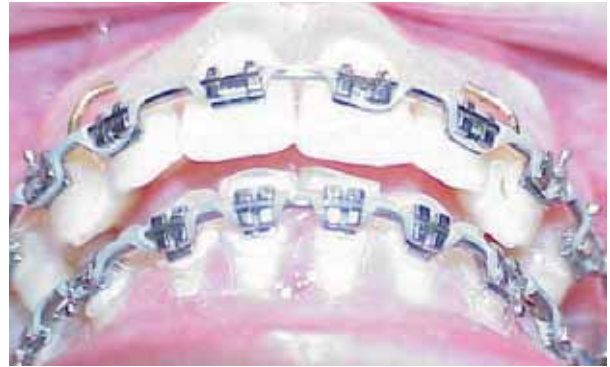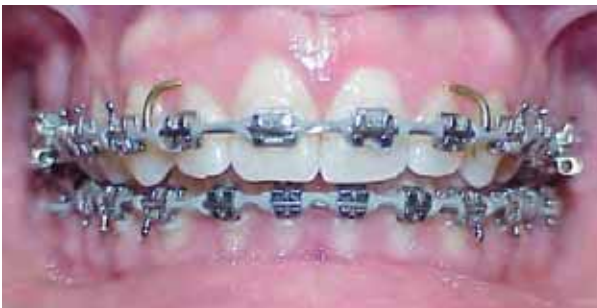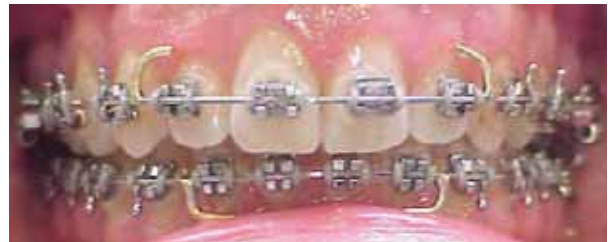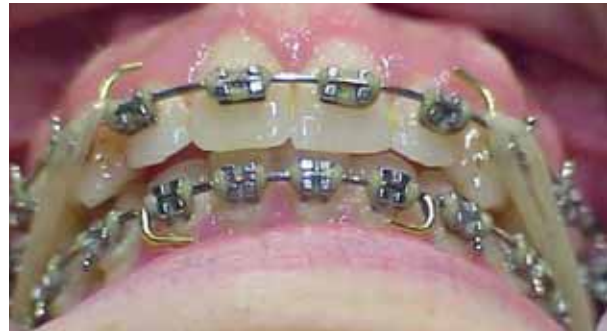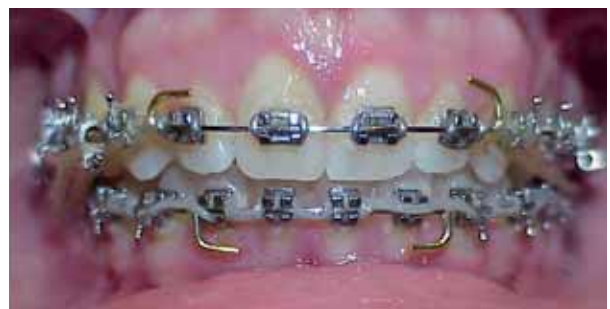1st month ▲

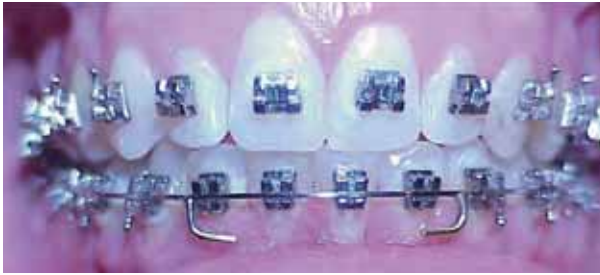

2nd month ▲

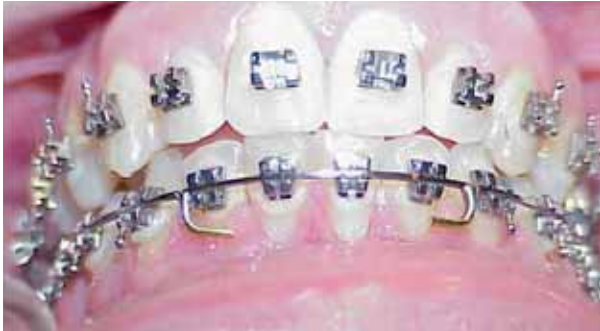

6th month ▲

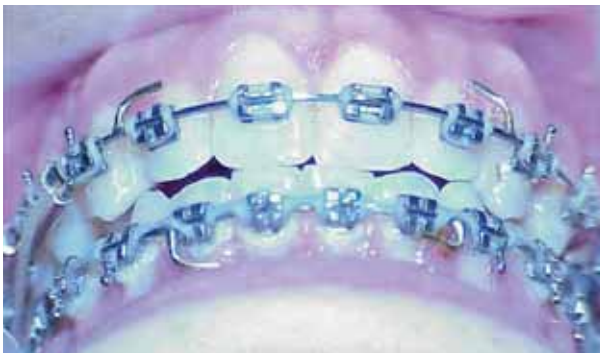7th month ▲9th month ▲10th month ▲10th month ▲12th month ▲14th month ▲15th month ▲



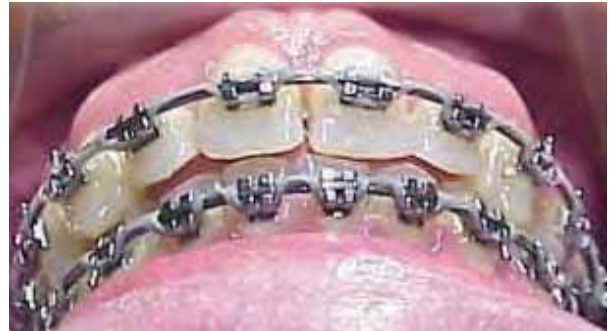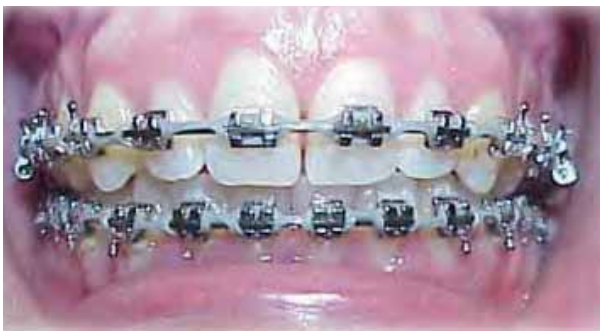16th month ▲



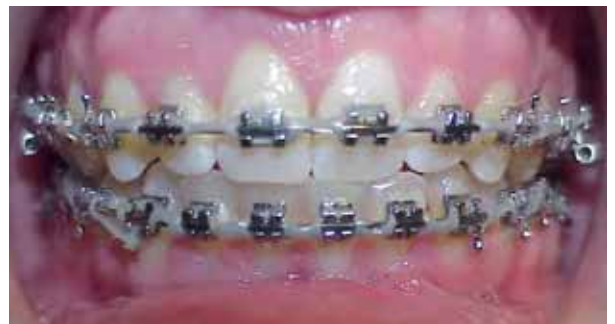17th month ▲



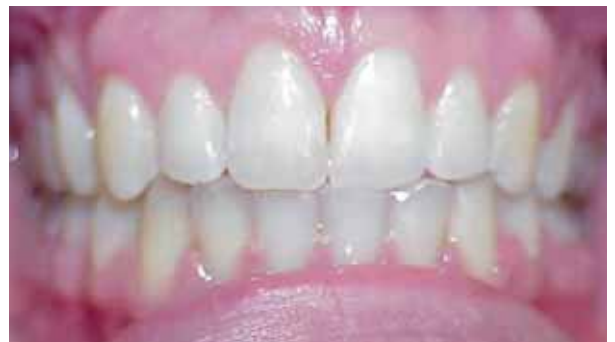22nd month ▲



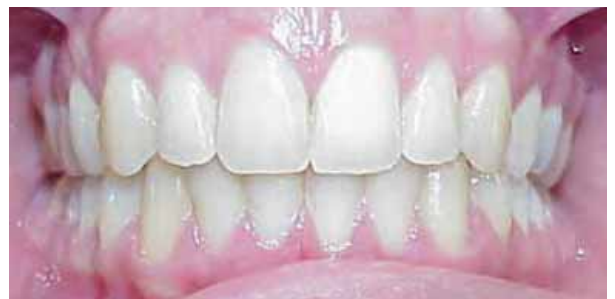22nd month ▲



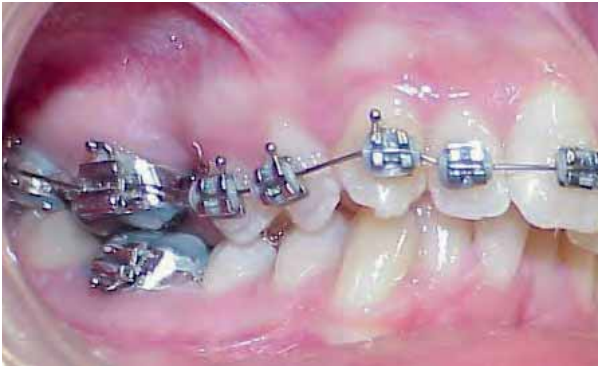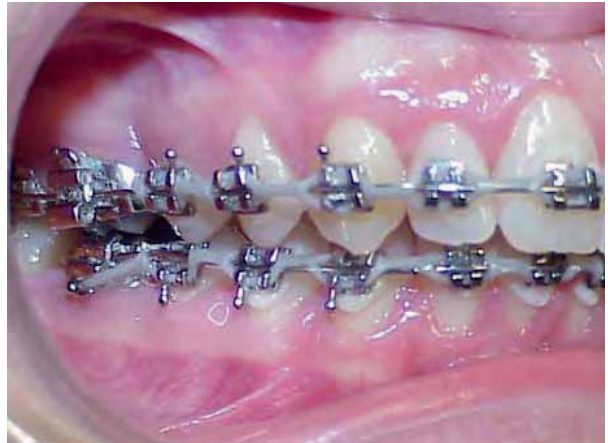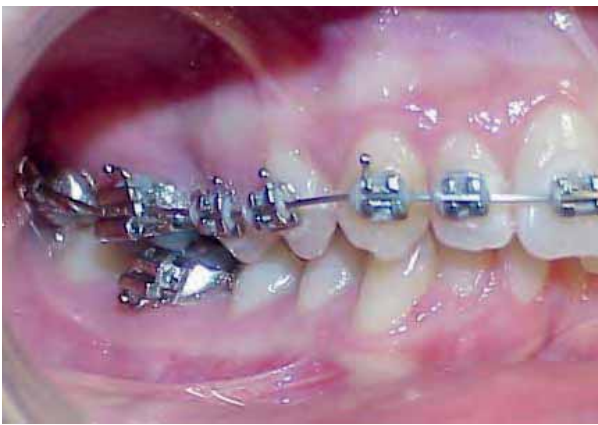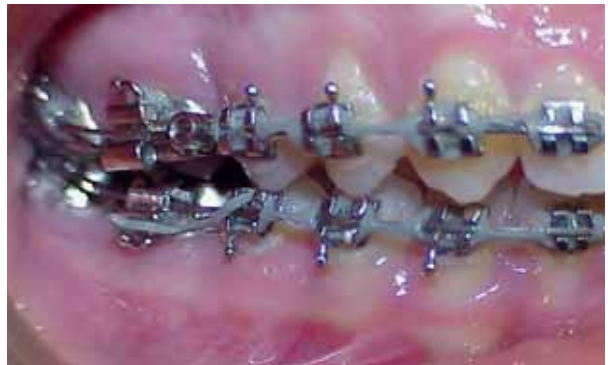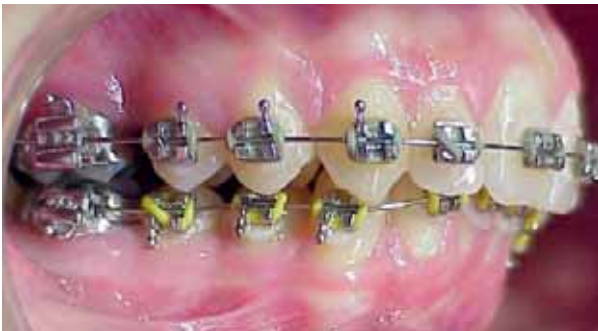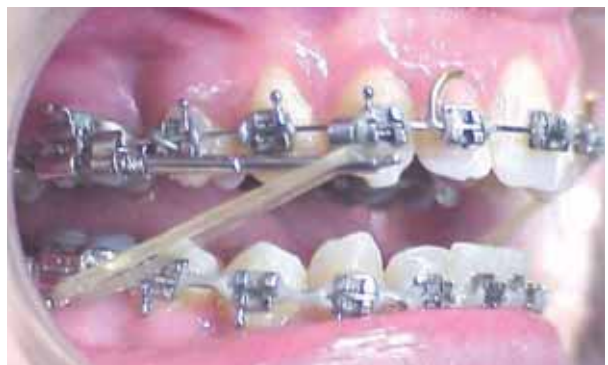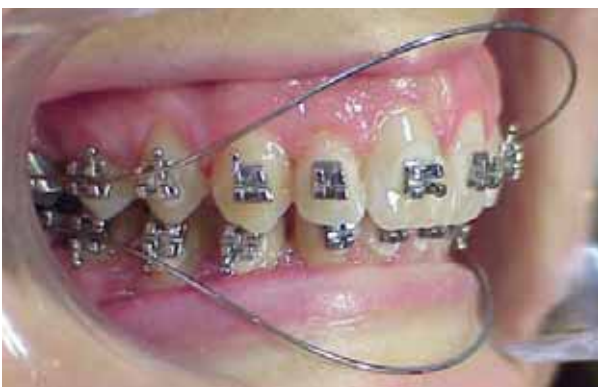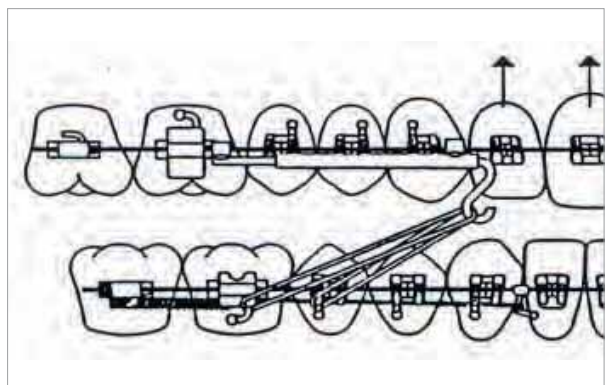
24th month ▲

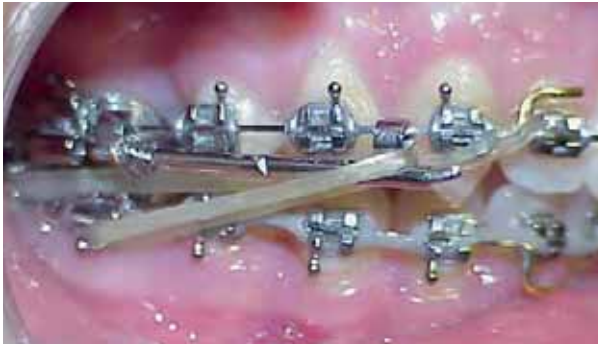


26th month ▲

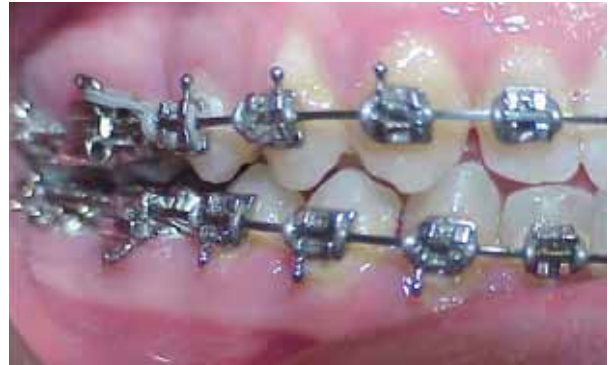

38th month ▲

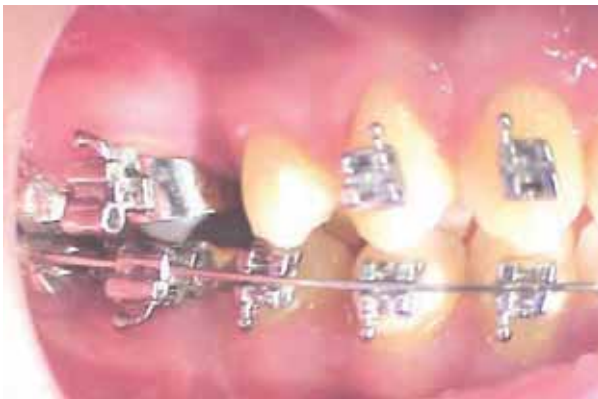1st month ▲7th month ▲2nd month ▲9th month ▲6th month ▲12th month ▲7th month ▲



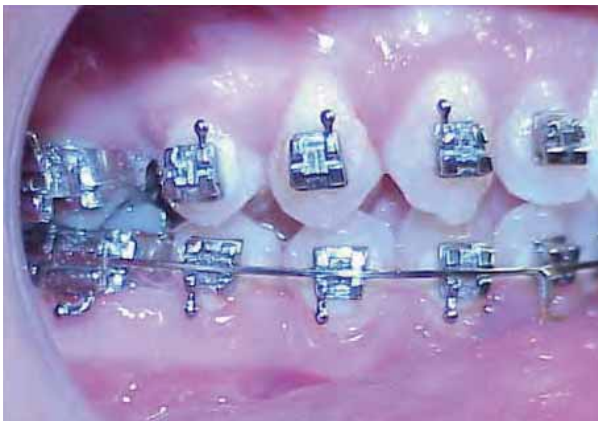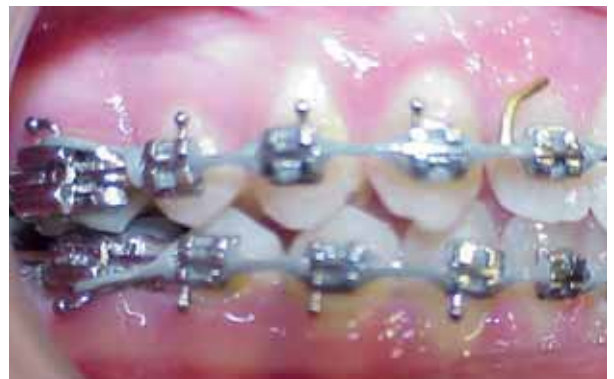13th month ▲



20th month ▲



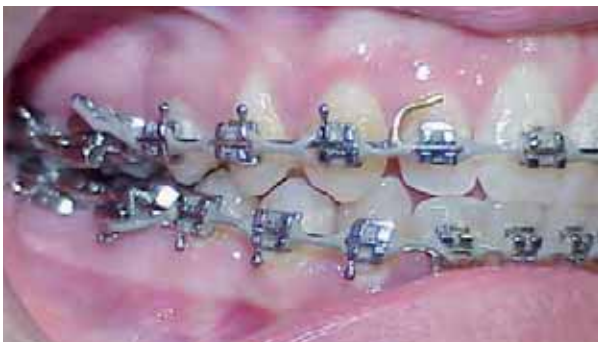15th month ▲



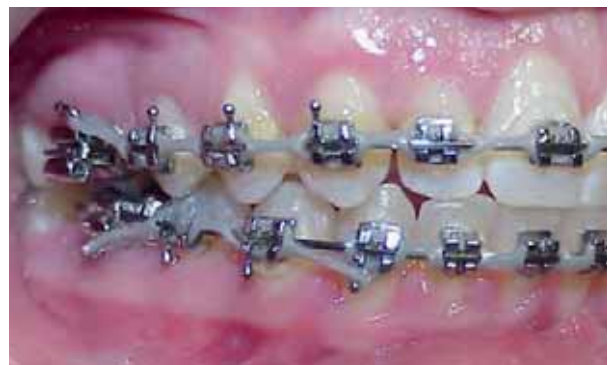16th month ▲



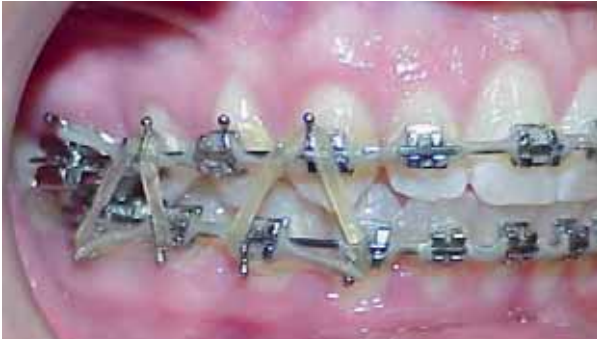23rd month ▲



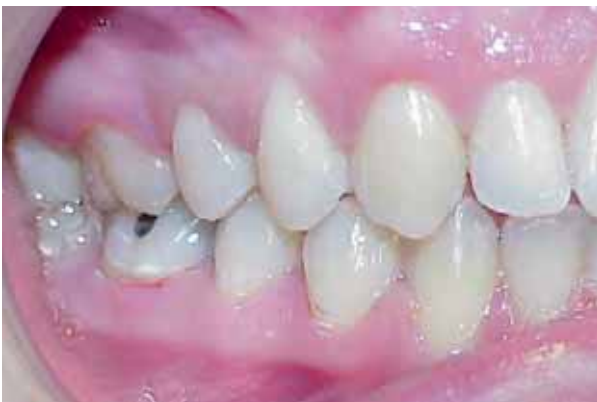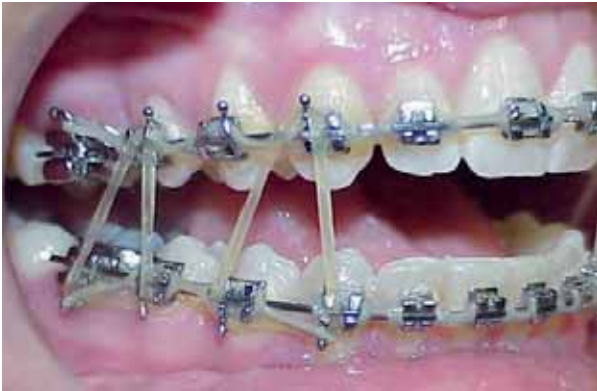19th month ▲



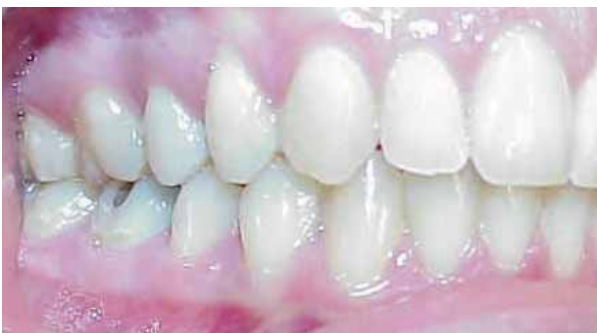24th month ▲



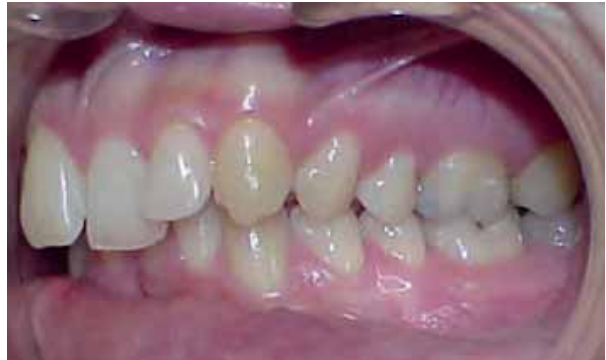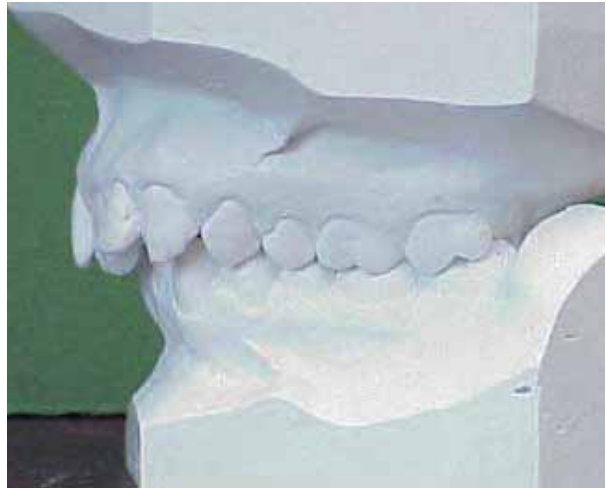25th month ▲



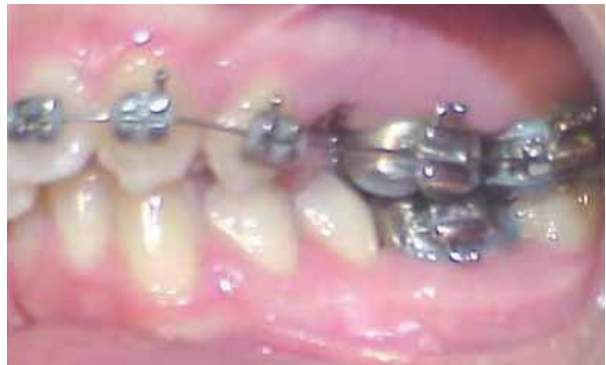26th month ▲



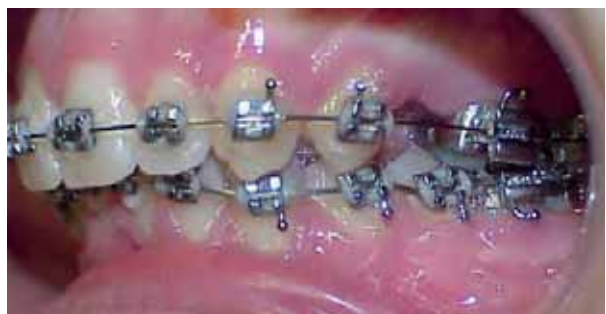38th month ▲



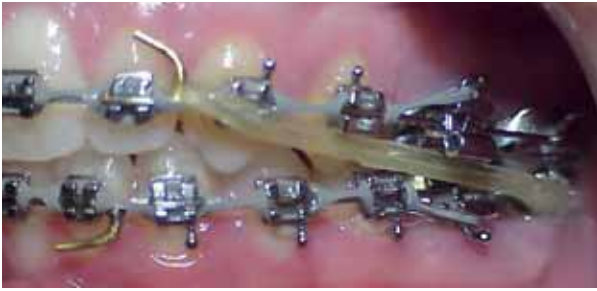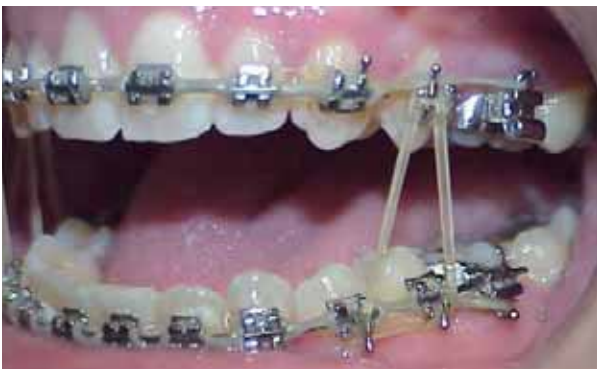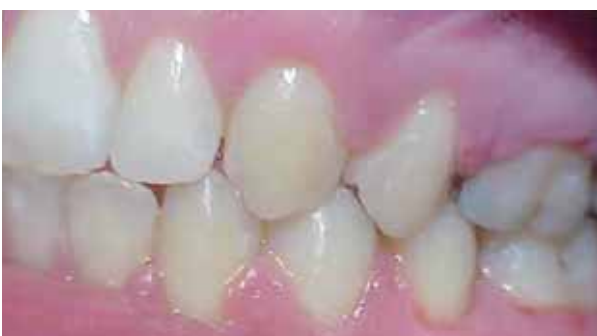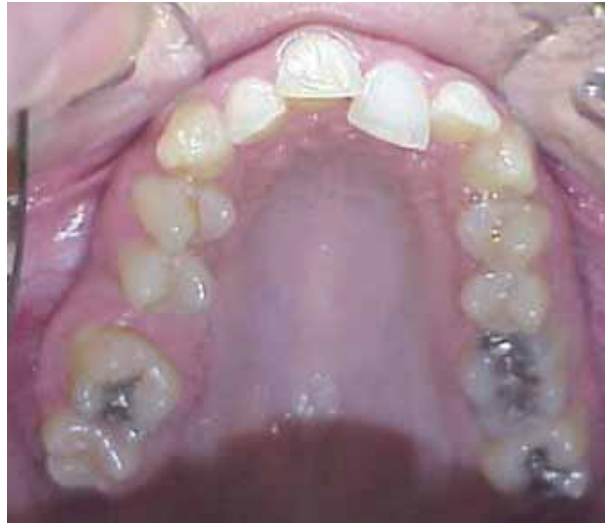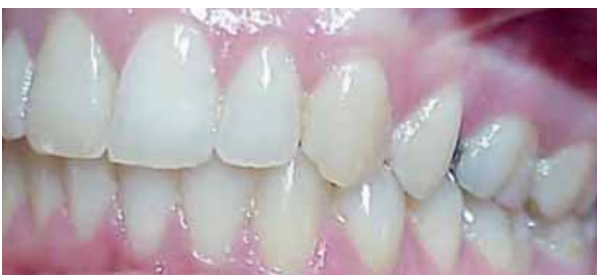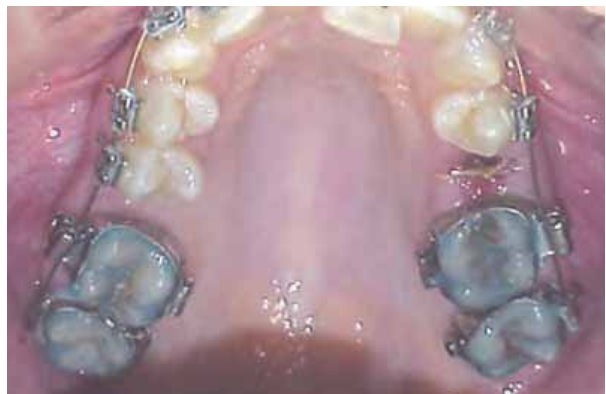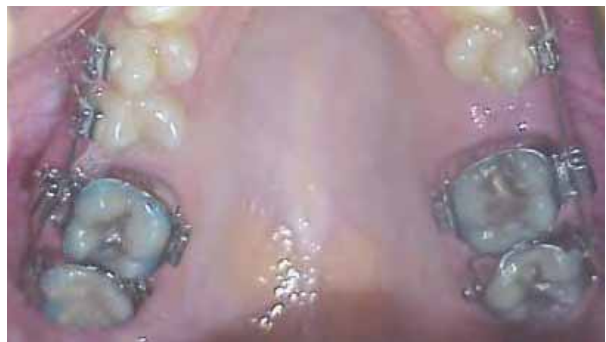Beginning ▲

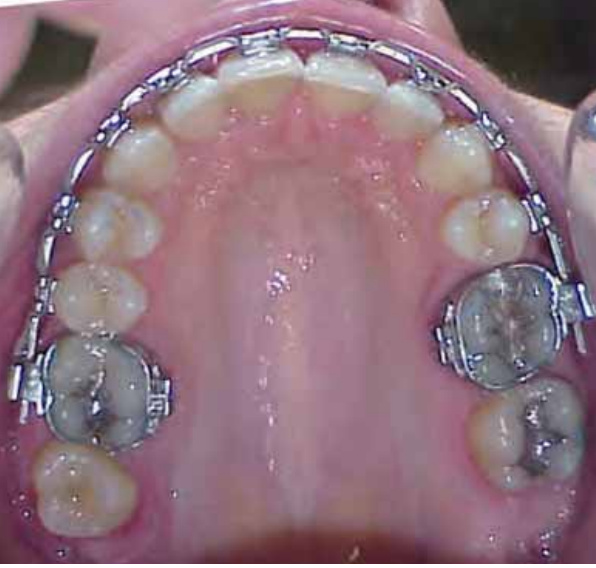
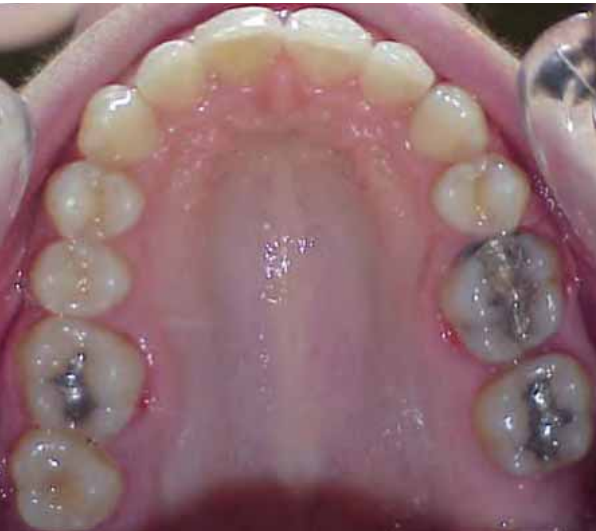
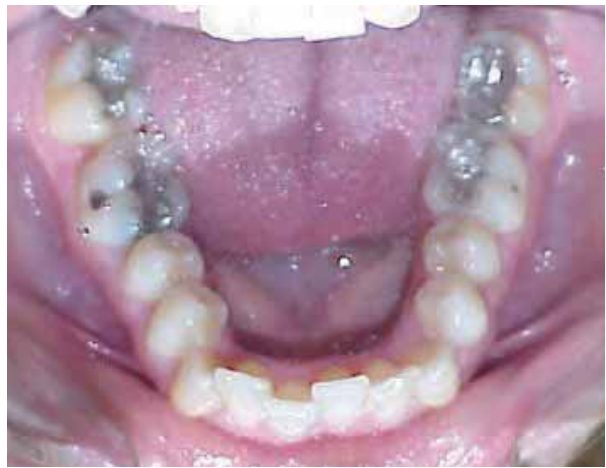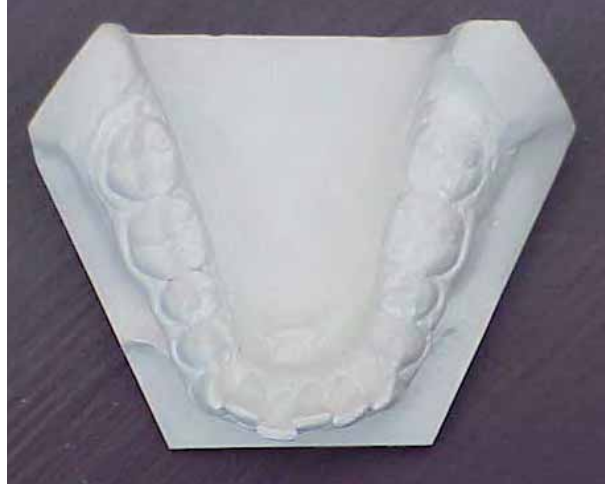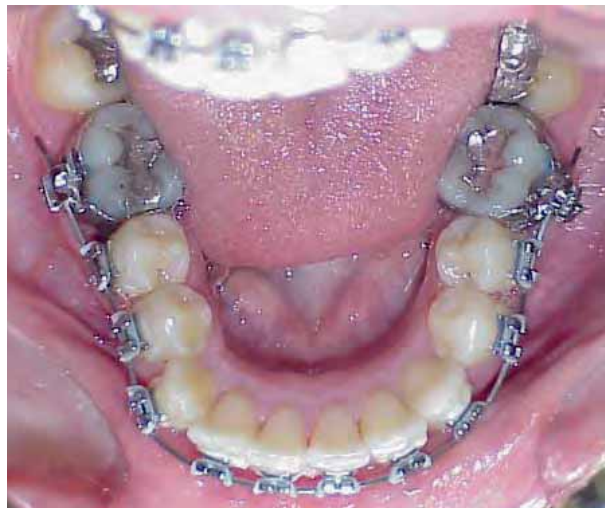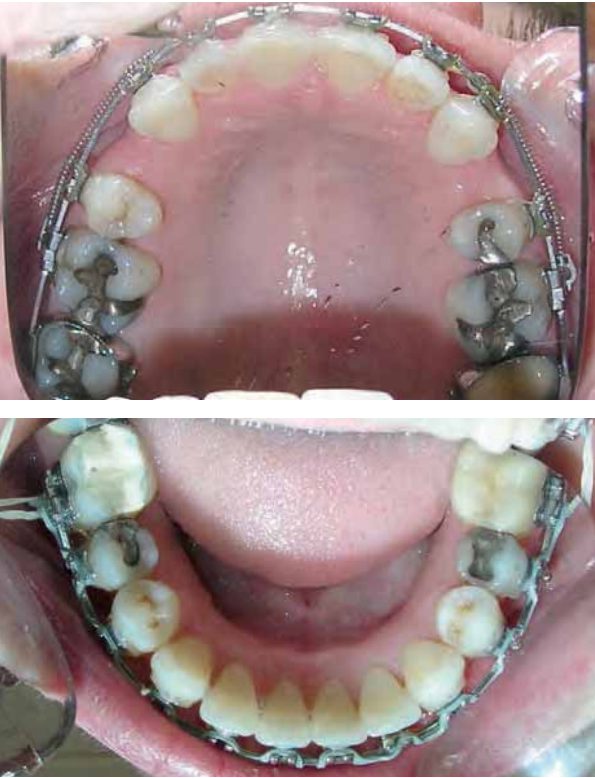1st month ▲



6th month ▲

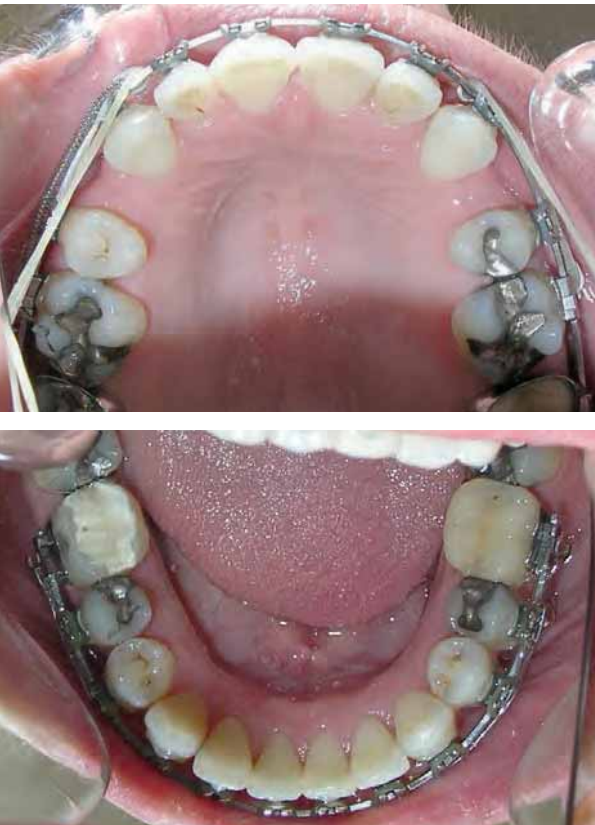23rd month ▲25th month ▲26th month ▲38th month ▲1st month ▲2nd month ▲

25th month [▶](#)26th month [▶](#)Beginning [▶](#)6th month [▶](#)



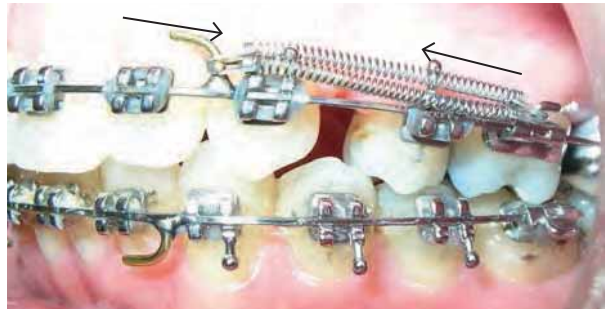
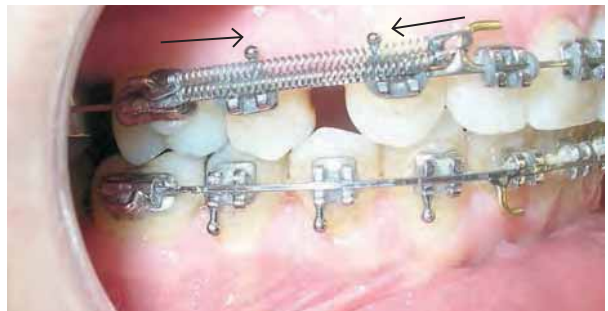
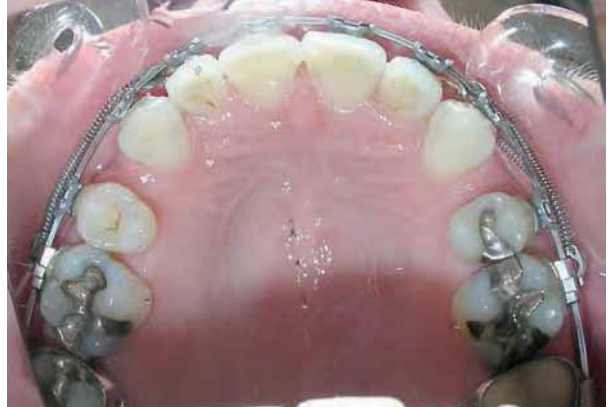“Stripping” of MAND incisors at each visit.

7TH MONTH



8TH MONTH

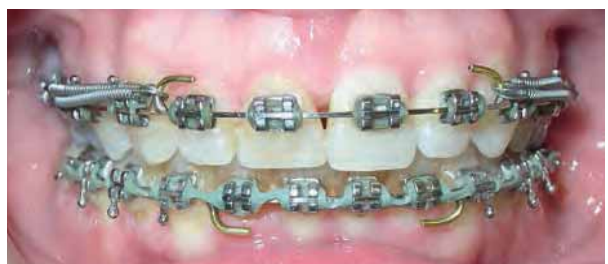MAX: same 19x25 posted steel, flat (no acc C). Stop CLI and CLII elastics. Change to 2 x 150gr NiTi closing springs. CLI forces, reciprocal space closure. MAND: same 19x25 posted steel. Stripping 3 to 3.

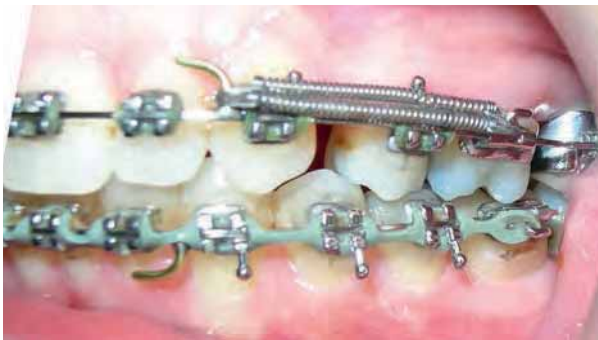
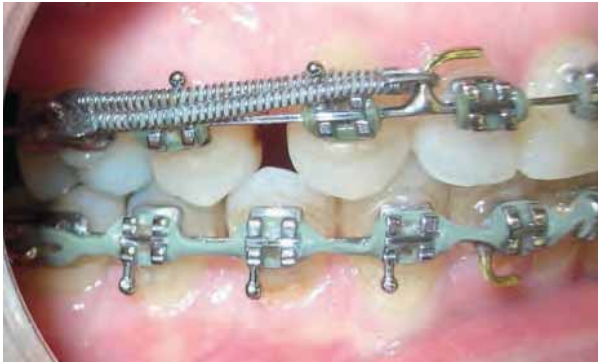
9TH MONTH

MAX: same 19x25 posted steel, no acc C. 2 x 150gr NiTi closing springs, no CLII elastics.

MAND: same 19x25 posted steel, L-L CH from M1-M1. Stripping 3 to 3.



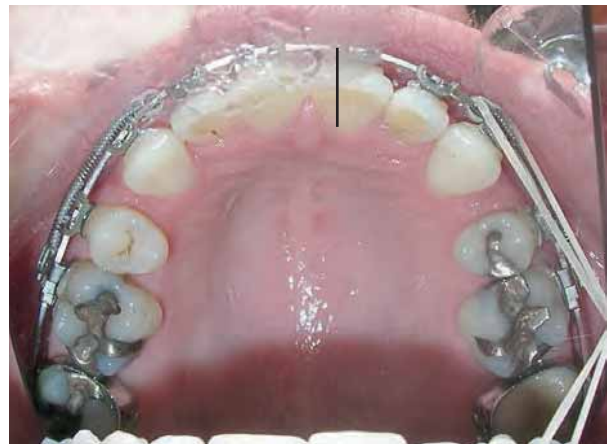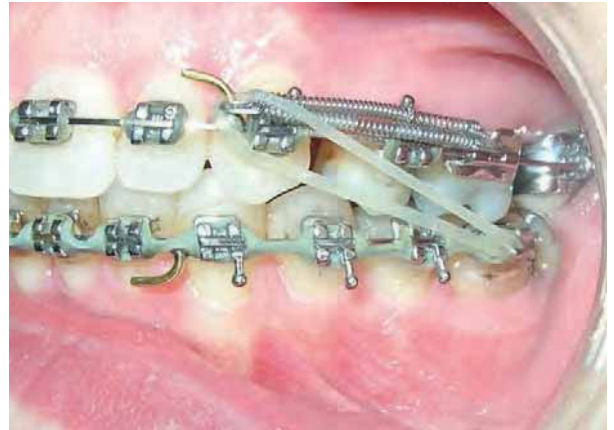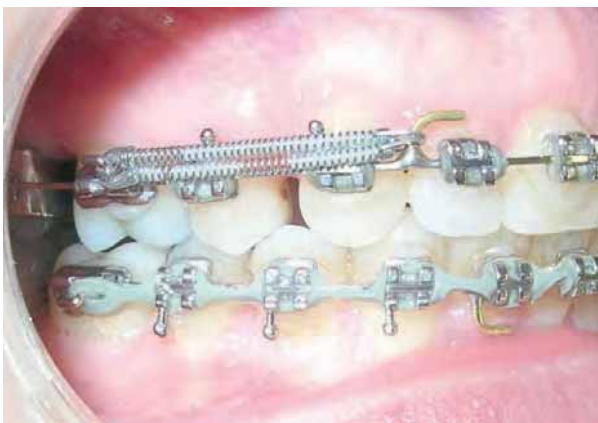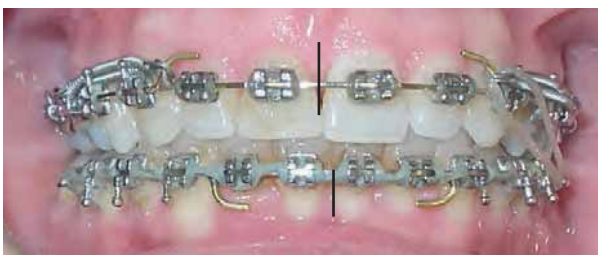**10TH MONTH**

MAX: same

MAND: same

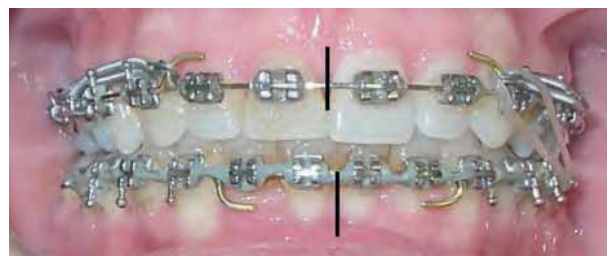MAX midline is deviated to the right.

Left side: There is more space available and the left side is more CLII than the right: start CLII elastic, 6 mm, 24/24, unilateral (left side only).



CLII elastic, 6 mm, 24/24, unilateral (left side only) to shift the MAX M-L and to obtain a CLI canine on the left side.

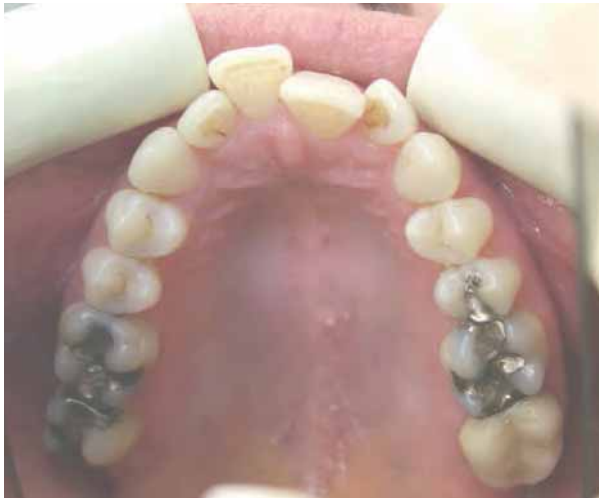In a CLII case where the MAX M-L is deviated to one side (in this case: right), the M-L can only be corrected if there is space on the opposite posterior side (in this case the left). By using asymmetric forces (in this case CLII elastics) the anterior segment and midline can be moved into this space correcting the midline, the OJ and the CLII canine position.



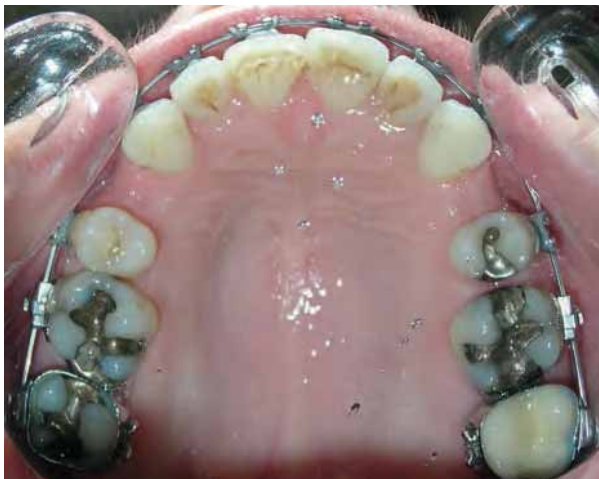General ideas: By contrast, generally in CLII cases, MAND midline deviations can be corrected without space using asymmetric CLII elastics, but this is possible only if there is an OJ anterior.

Without OJ, space would have to be created on the opposite posterior side.

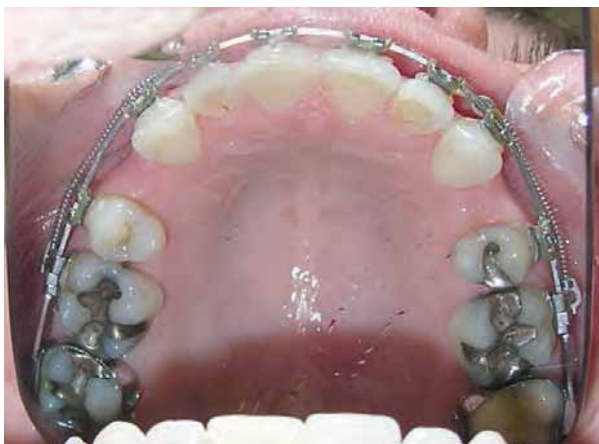REVIEW



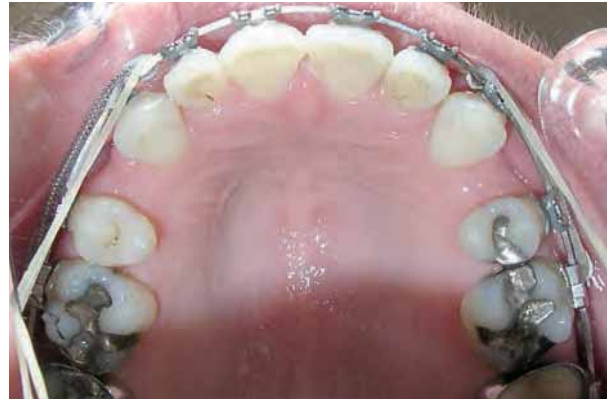Beginning



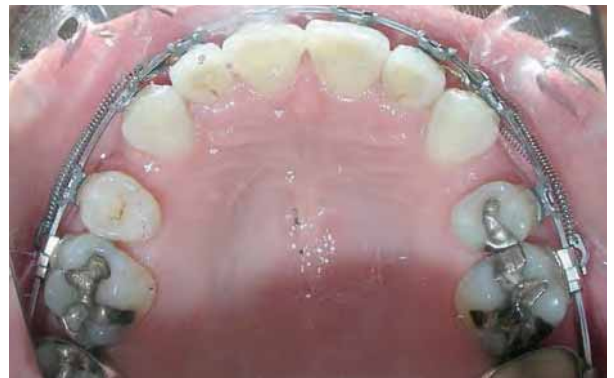4th month



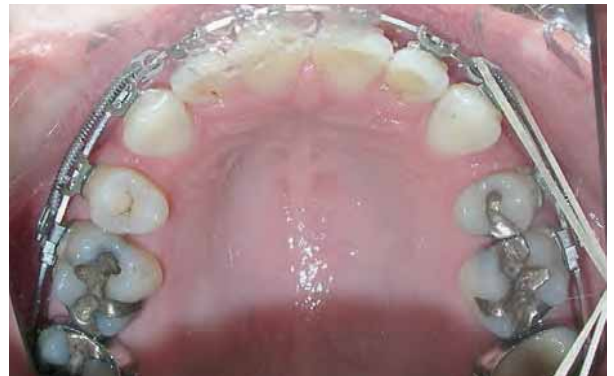6th month



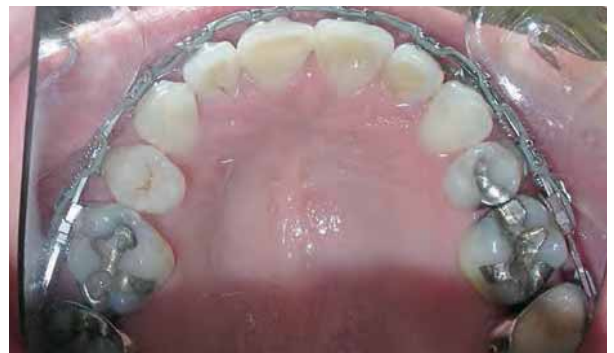7th month



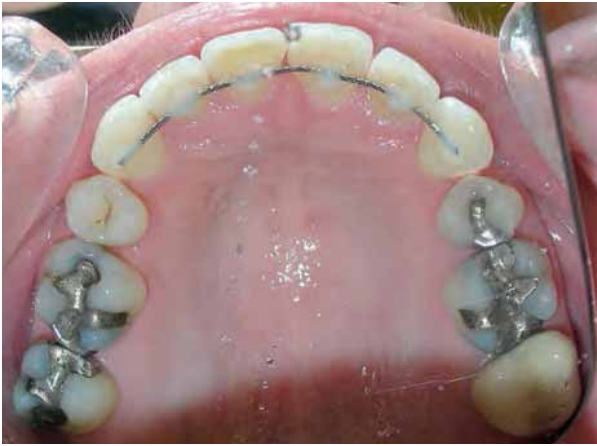8th month



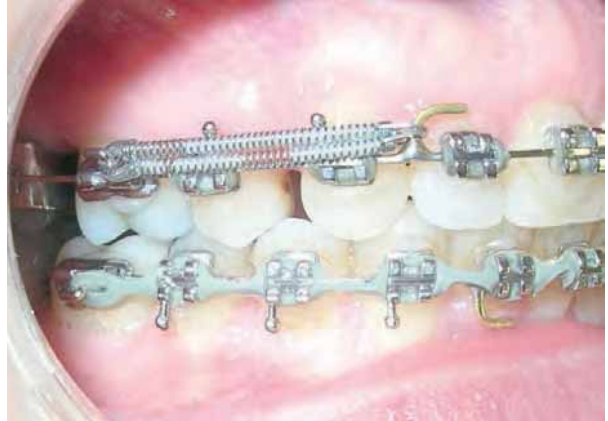10th month



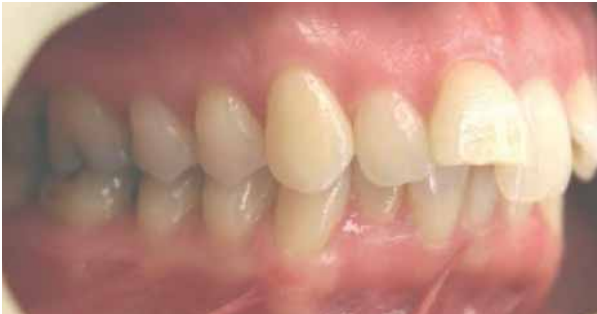13th month



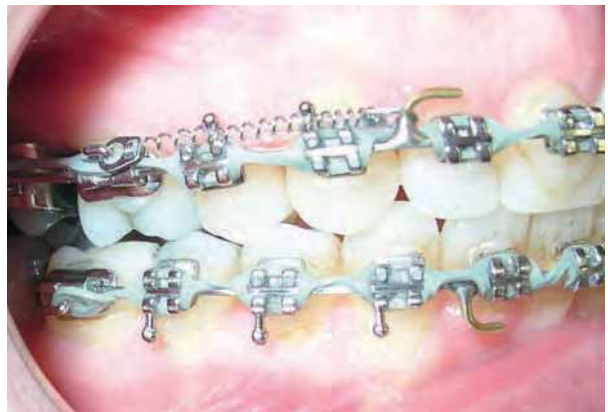16th month ▲



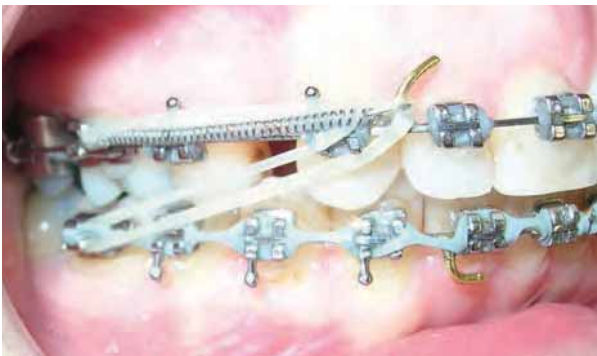10th month ▲



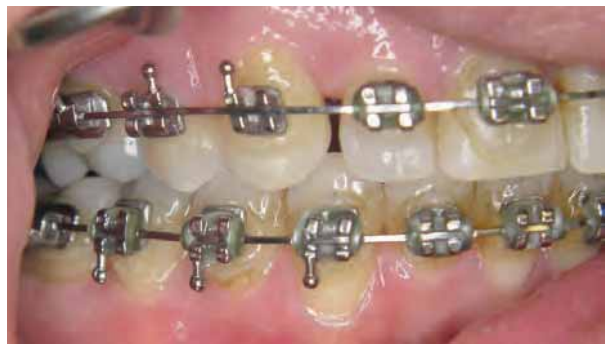Beginning ▲



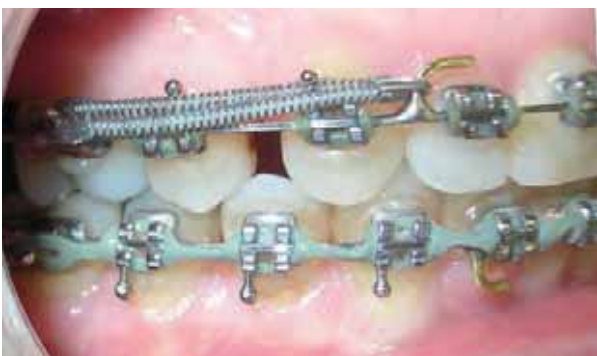13th month ▲



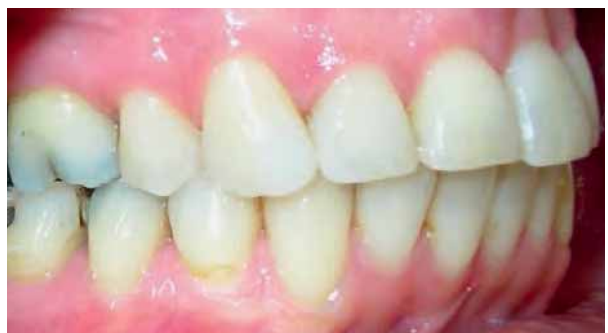6th month ▲



15th month ▲

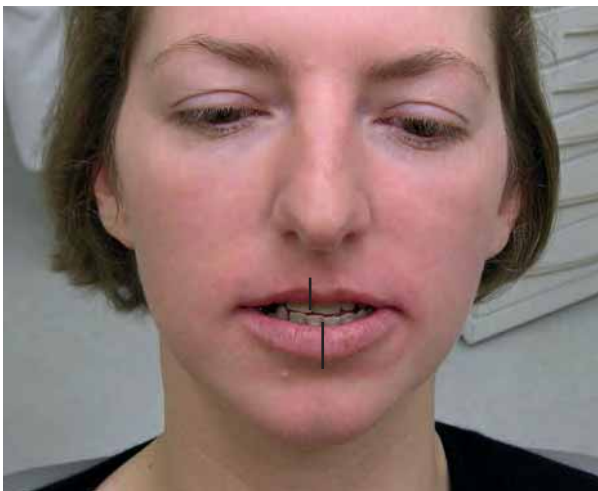
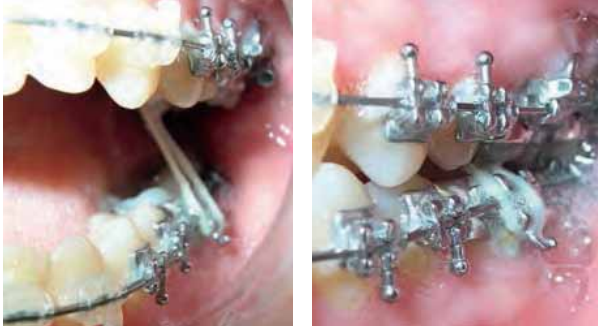
9th month ▲

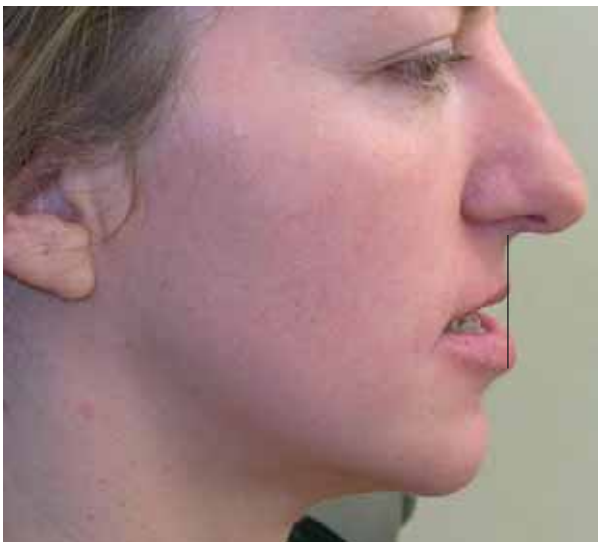

16th month ▲

6 mm X-elastic from lingual 26 to buccal 36, 24/24. X-bite is corrected.



The “CLIII Look” is temporarily worsened due to advancement of the MAND anterior teeth. M-Ls are deviated. ◆

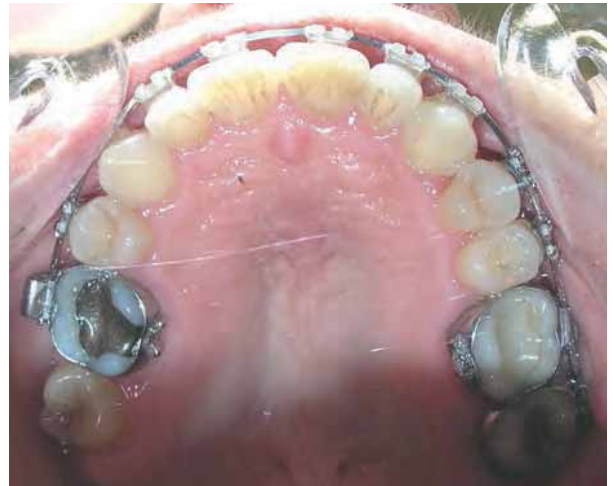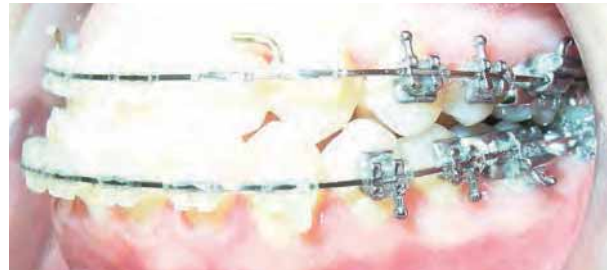
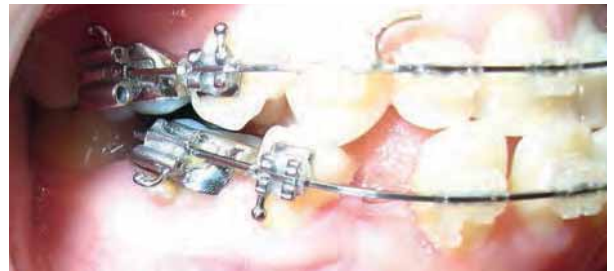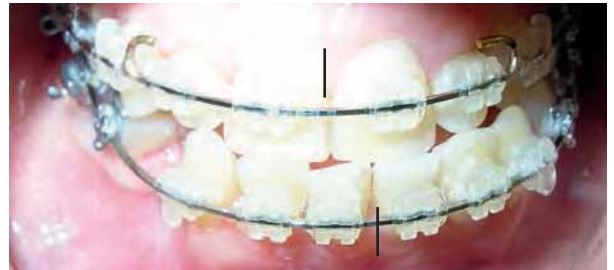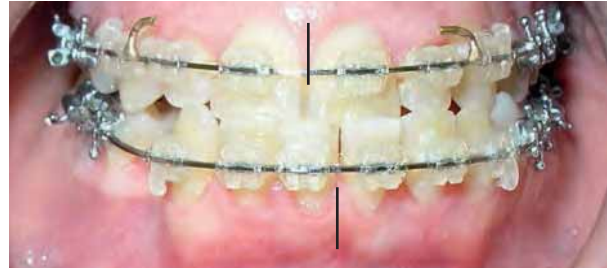


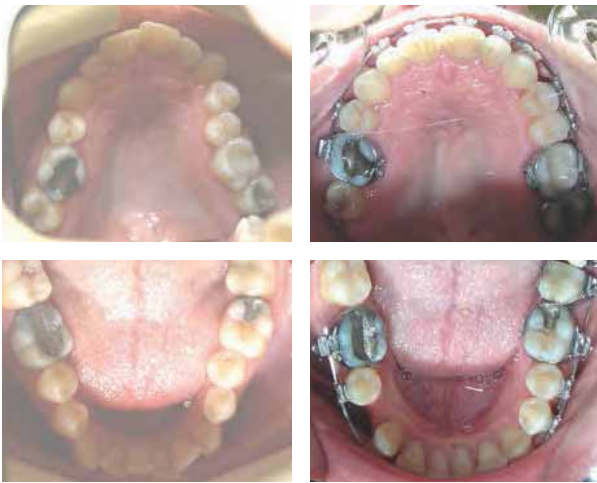
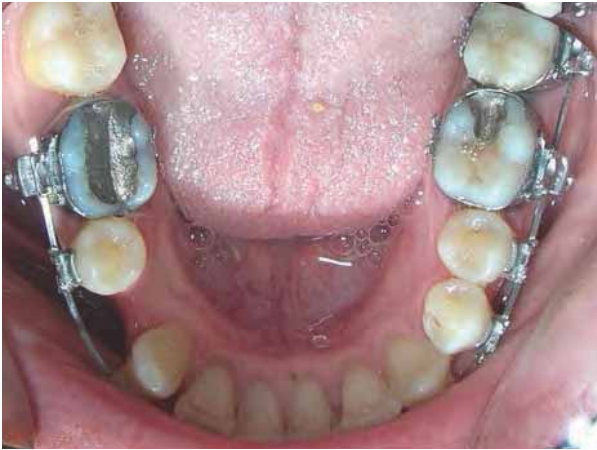Upper lip is behind the SNV line and lower lip is in front (normally this is the opposite). ◆

8TH MONTH

MAX: same 19x25 posted steel, 6 mm expansion. X-elastic.
MAND: N. 19x25 steel.

Allow both arches to finish leveling 1 more month.





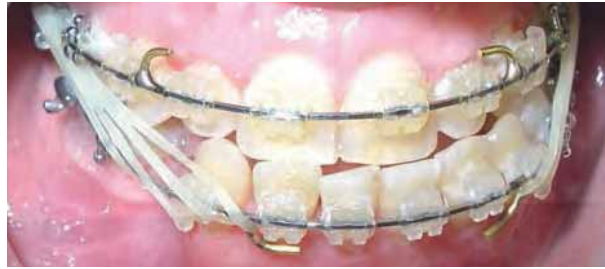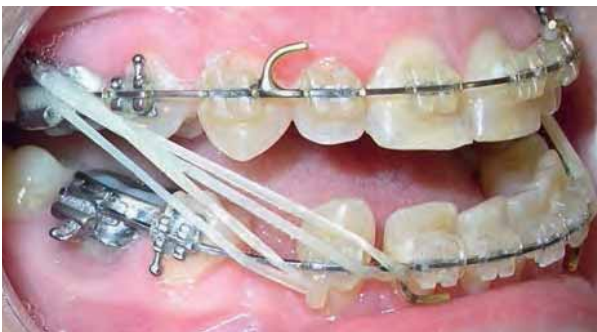9TH MONTH

MAX: same 19x25 posted steel, 6 mm expansion.

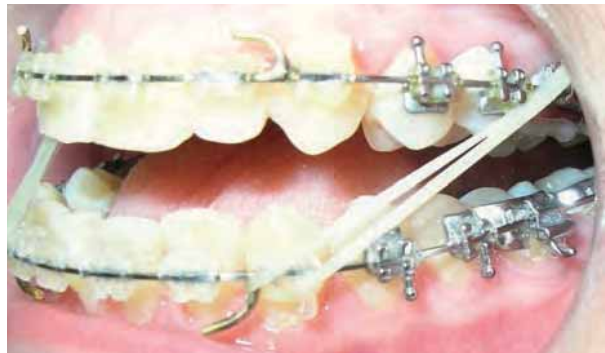MAND: 19x25 posted steel.

Left side: one, CLIII elastic, 8 mm, from 26 to wire post, 24/24 (this will help correct the CLIII occlusion).

Right side: two, CLIII elastics, 8 mm, 24/24, one from 16 to 43 and one from 16 to the wire-post. (This will help correct the mid-lines, CLIII canine and the CLIII occlusion under-bite).



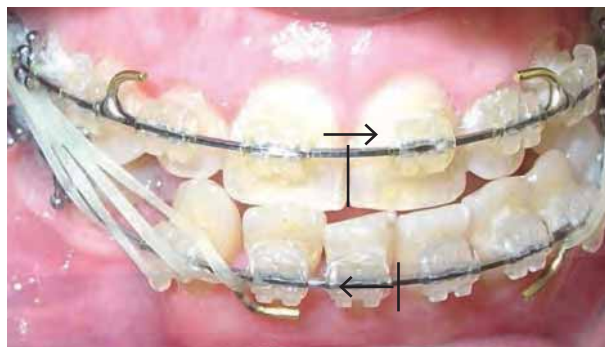
Of note: on the right side, both elastics could as well be attached simultaneously to the wire post.



Strategy: maximum anchorage is used on the right side at the beginning because 43 needs to distalize and “take the place” of the extracted 44: thus it must be moved distally 7mm. There are no forces on the MAND posterior segment.

The asymmetric CLIII forces allow the MAND anterior right segment to be distalized en masse which will move the midline to the right and at the same time correct the CLIII under-bite.

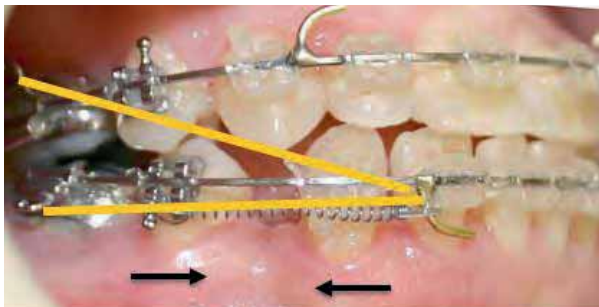
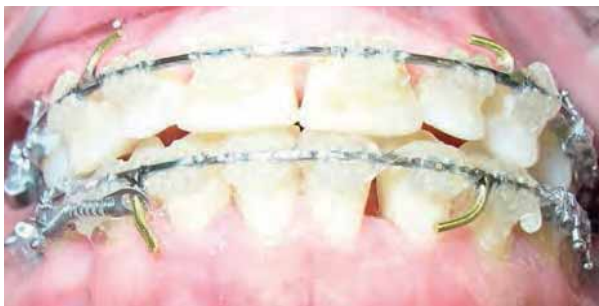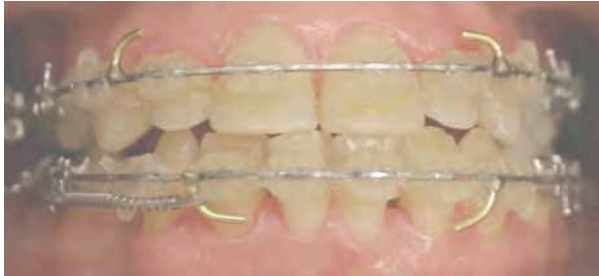Left side has one CLIII elastic to help in correcting the dental CLIII. The CLIII is corrected by distalizing the MAND anterior segment and by advancing the MAX arch 1 to 2 mm in the alveolar bone. And because this CLIII mesializing force on the MAX arch is asymmetric, the MAX midline can be corrected towards the left by about 1 mm.



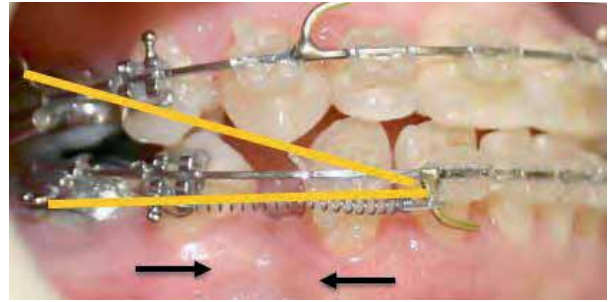
The CLIII “under-bite” must be corrected. At the same time the MAND M-L will be moved to the right about 3 to 4 mm, the MAX M-L will move to the left about 1 mm and the entire MAX arch will advance 1 to 2mm. ◆

11TH MONTH

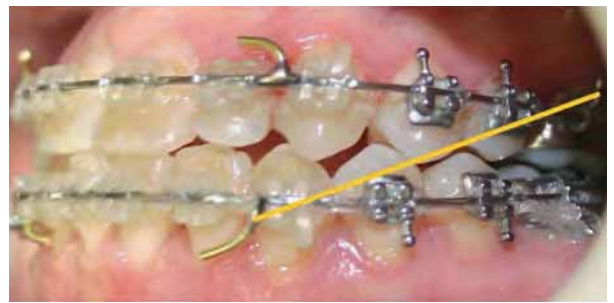Improved M-L relationship and the “under-bite” is being corrected.



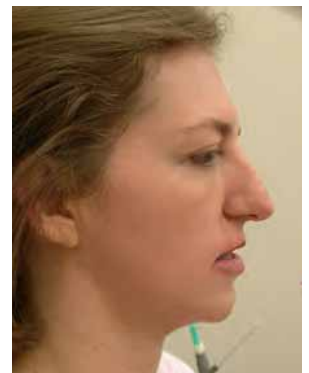
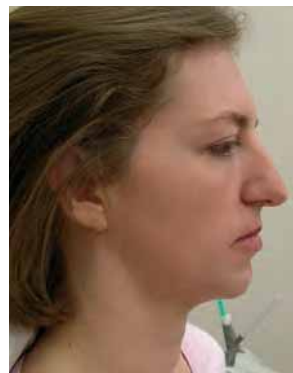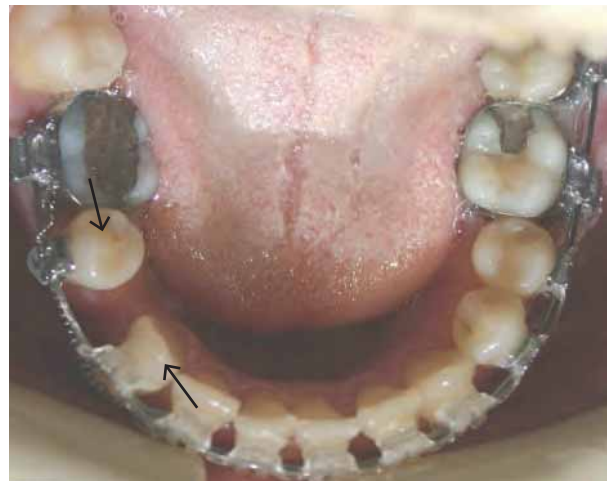
Right side: 43 is now only 2.5 mm from a CLI canine relation, but there remains 5 mm of space. This indicates that the original maximum anchorage can now become moderate and because of this, the posterior segment now can now be reciprocally advanced 2.5 mm. This will be accomplished with CLI reciprocal, en masse space closure: 1, elastic, 6 mm, and 1, 200 gr NiTi closing spring from 46 to MAND post. Continue with 1, CLIII elastic, 6 mm, from 16 to the MAND post (for the overall CLIII correction). The overall “anchorage change” here can be attributed to the MAX arch moving forward 1-2mm due to the CLIII elastics.



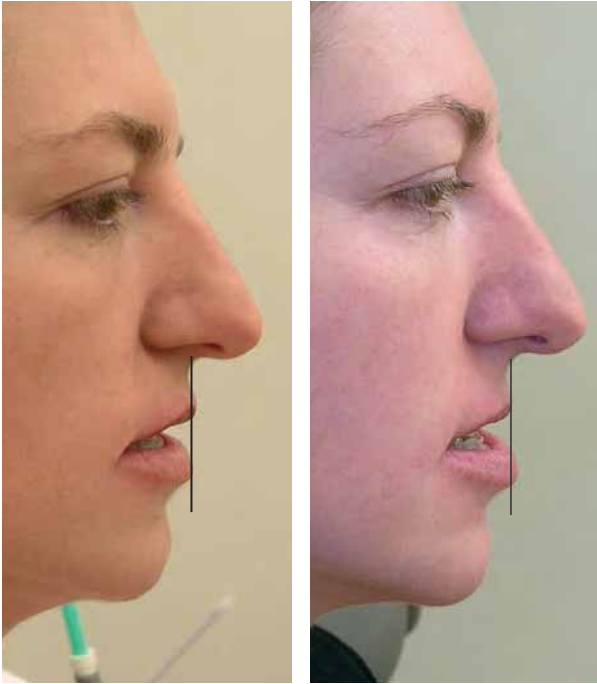MAND: 1, elastic, 6 mm and 1, 200gr NiTi closing spring from 46 to MAND post. 1, CLIII elastic, 6mm, from 16 to MAND post.



MAND: Continue: CLIII elastic, 6 mm, from 26 to post.

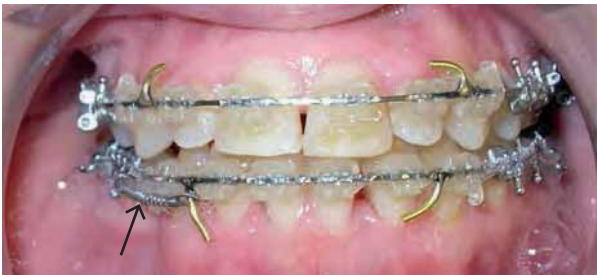

The upper lip is more full and the lower lip is retracted. This improves the profile by creating a better harmony between the lips and the face.

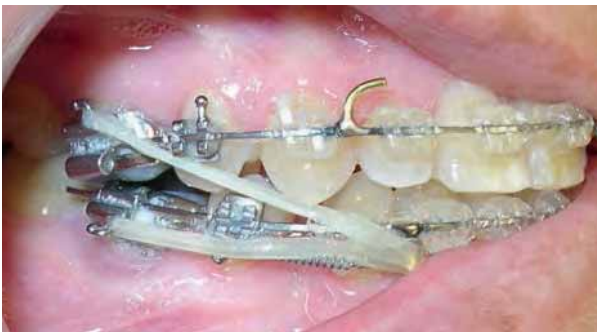

12TH MONTH

As the occlusion is settling into a CLI position, the teeth are inter-digitated more correctly so that the anterior segment has closed down and there is a 2.5 mm OB (no box elastics were needed). M-Ls are aligned.

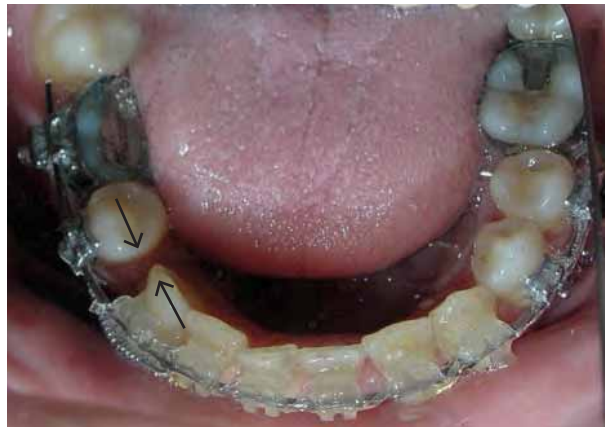
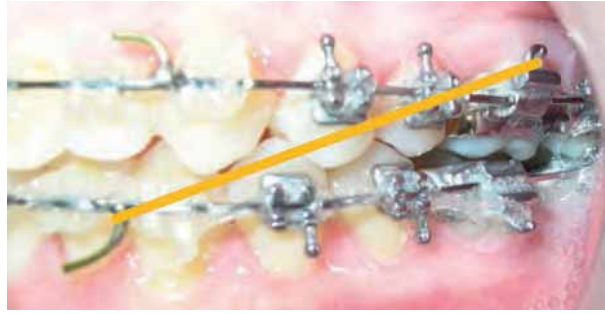
200 gr NiTi closing spring ◆

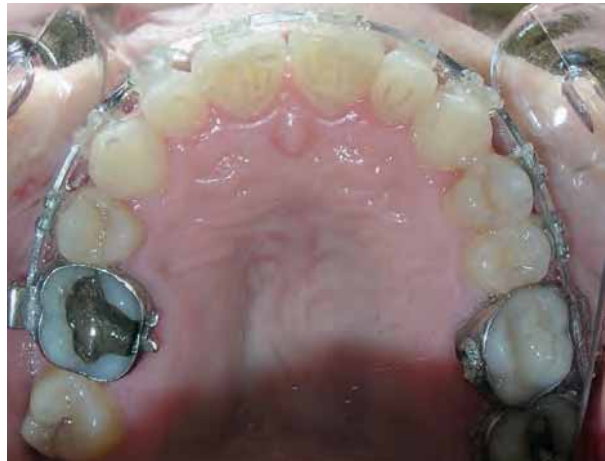

MAND: Continue bilateral CLIII elastics, 6 mm, 1 per side from the MAX MIs to the wire posts, 24/24.

Continue CLI 200 gr NiTi spring and 6 mm CLI elastic from 46 to wire post, 24/24.

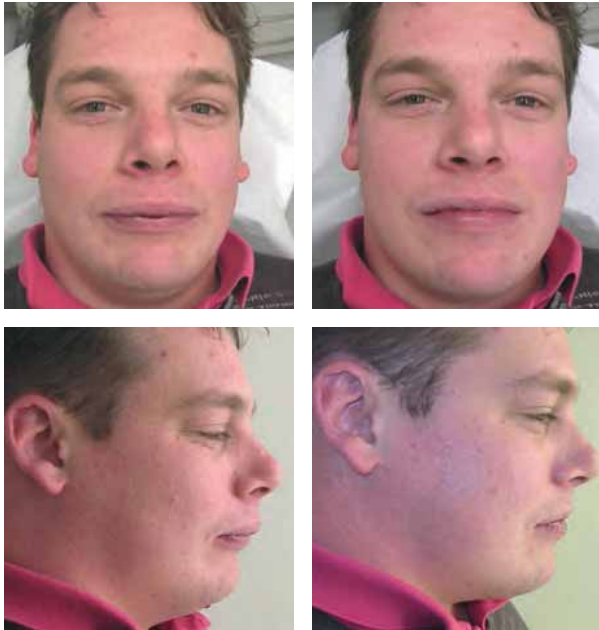

1.5 mm of space remains. ◆



Smile is larger and more ideal than before. CLIII Look is diminished. MAX and MAND M-Ls are “skeletally aligned” due to the asymmetric CLIII forces.

Since adult patients have no further growth, then the best solution both orthodontically and esthetically is a surgical mandibular advancement combined with pre and post-operative orthodontics. In this case this surgical procedure will both advance the mandible and open the deep bite.



MAND in the normal position ▲

MAND advanced “end to end” ▲

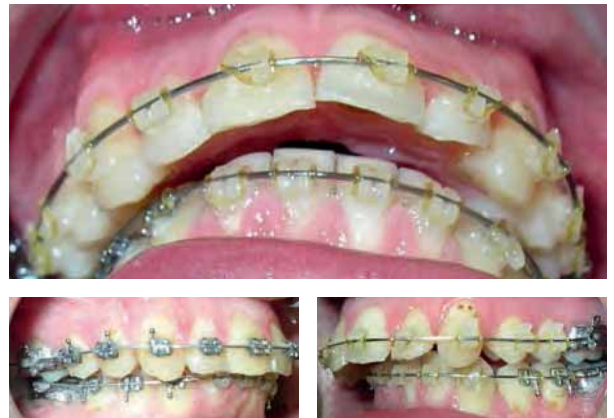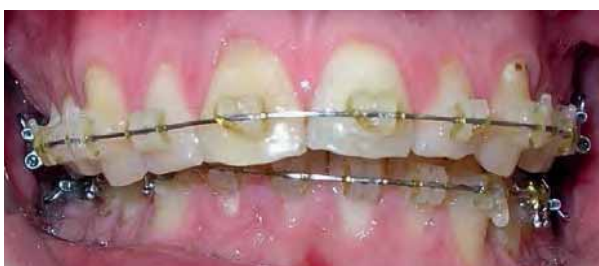TREATMENT PLAN

The orthodontic and surgical treatment plan must be made in conjunction with the oral surgeon and it is the surgeon who makes the final decision as to what surgical procedures will be used.

Orthodontic treatment plan: Level all the teeth in both arches using the SWA (sch 2) and the usual wire series until the 21x25 steel wires are in place. It is not needed nor indicated to try to open the bite. This is done during the surgery. After surgery, the case will be finished with the usual protocol as in a “normal” orthodontic treatment.

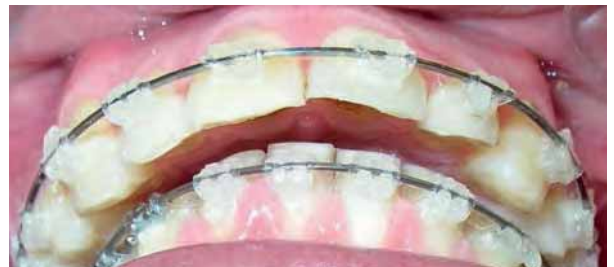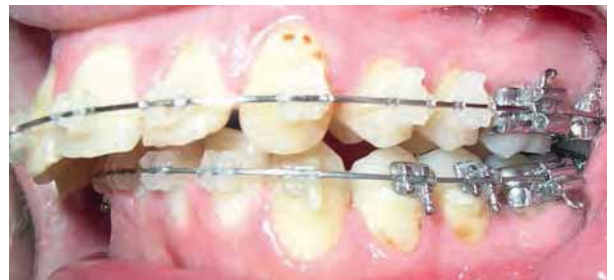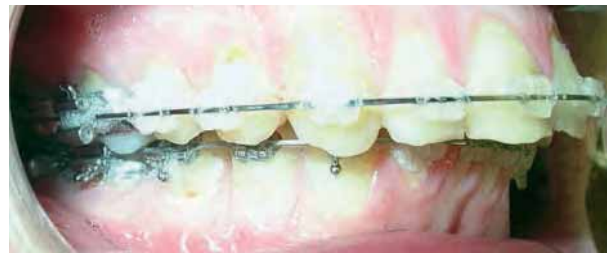4TH MONTH

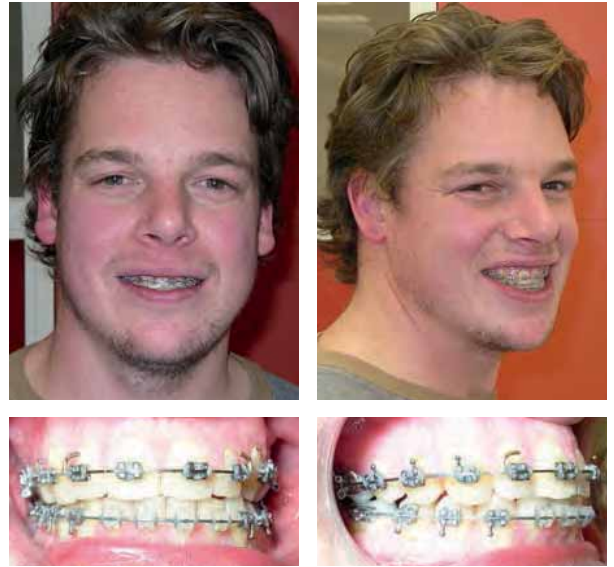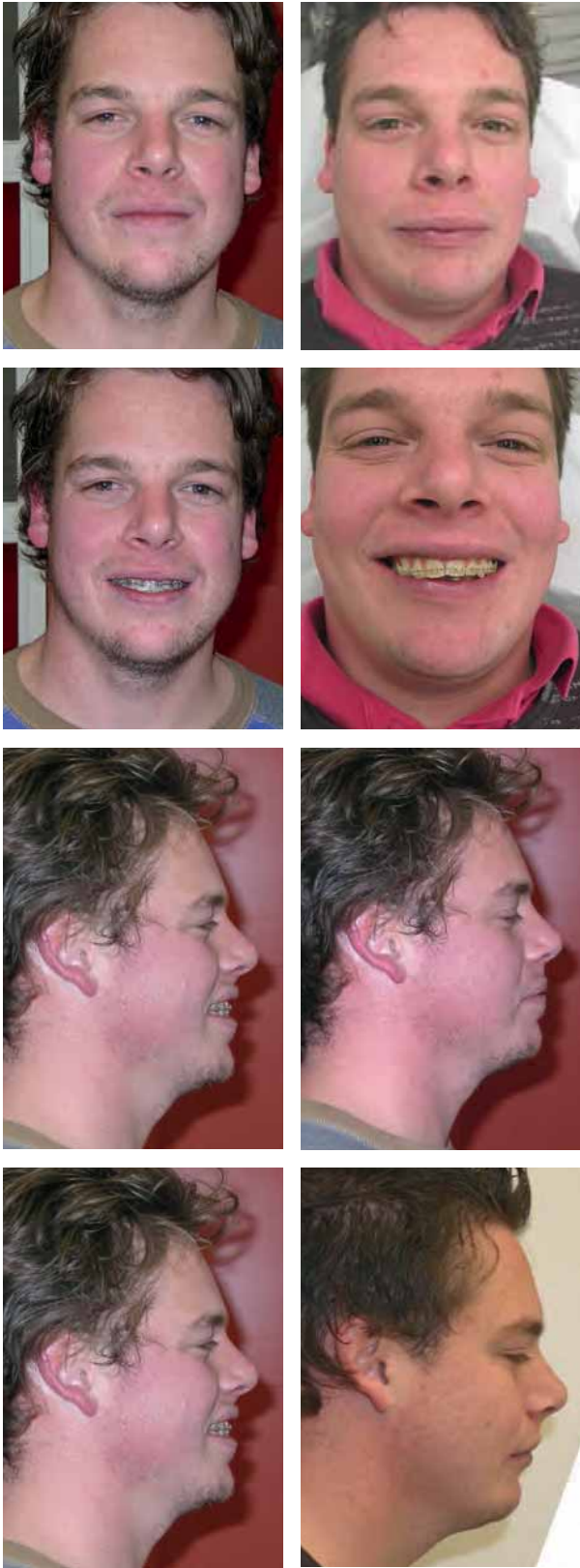MAX and MAND: N. 20x20 HA NiTi.



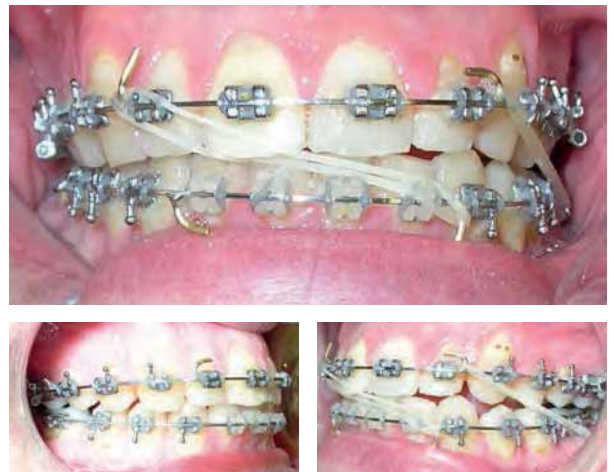6TH MONTH

MAX & MAND: 19x25 HA NiTi wires. Notice the deep bite and increased OJ (this would be impossible to correct “non-extraction” and have long term stability and proper condylar function).





MAX & MAND: same 19x25 posted steel. Begin finishing with elastics. Then, re-bracketing of various teeth and re-leveling.

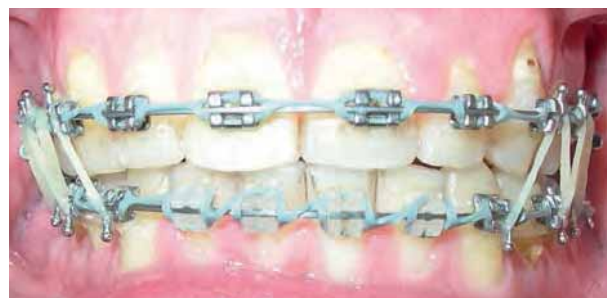

17TH MONTH

After the re-bracketing.

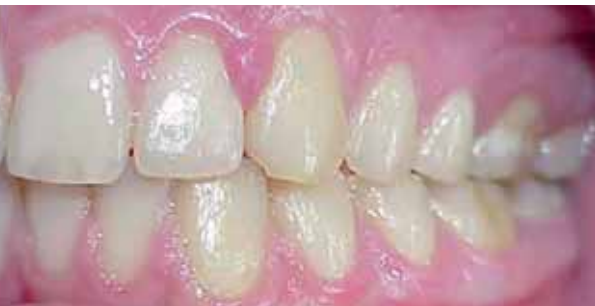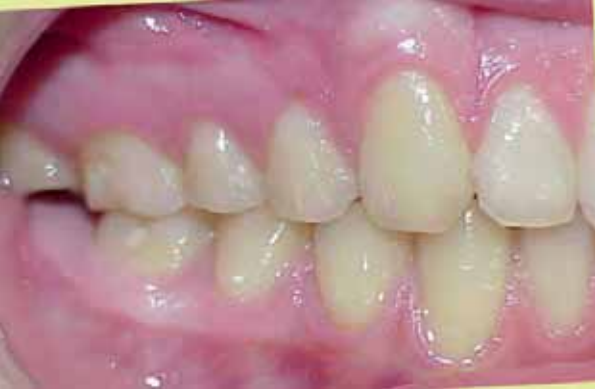MAX & MAND: 19x25 HA NiTi with L-L chain M1 to M1. 4 mm delta elastics, 24/24, are used to settle-in the occlusion.

Case is finished in an almost end-to-end position because there is always a rebound of the deep bite by 1–2 mm.



2 YEARS AFTER BRACES REMOVED

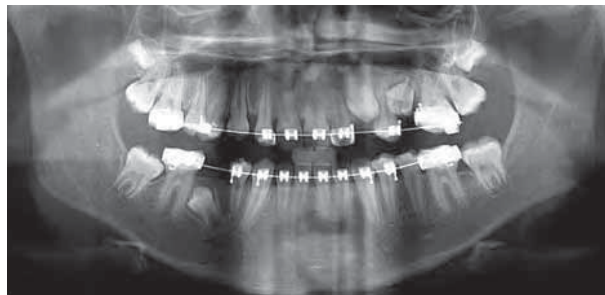Notice healthy attached gingiva.

**Impacted Premolar 45**

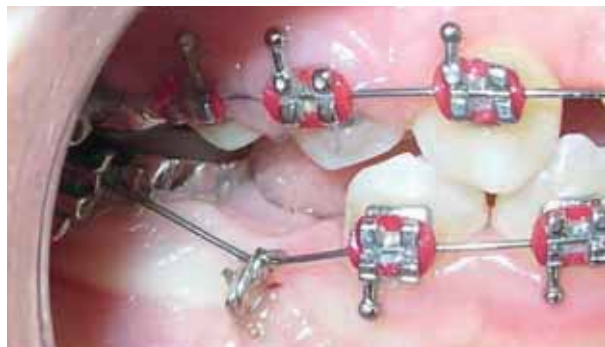For complete case: see the 1st case (Ve) in Chapter 16/6: “Maxillary 1st Molar Distalization”.



Panoramic X-ray to verify eruption of 45. Surgical attachment with wires is bonded. Will try to save 45. Explained possible complications. Note 47 and 25 may need attention also.

**16TH MONTH**

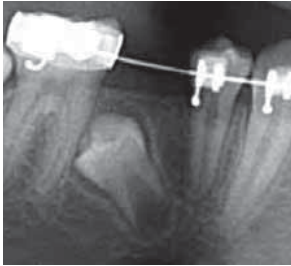
Metal ligature wires from attachment pass through the gingiva and are wrapped around and tightened down on the 16 HA wire. This “flexes” the wire slightly so as to apply a light ~60 gr force to 45.



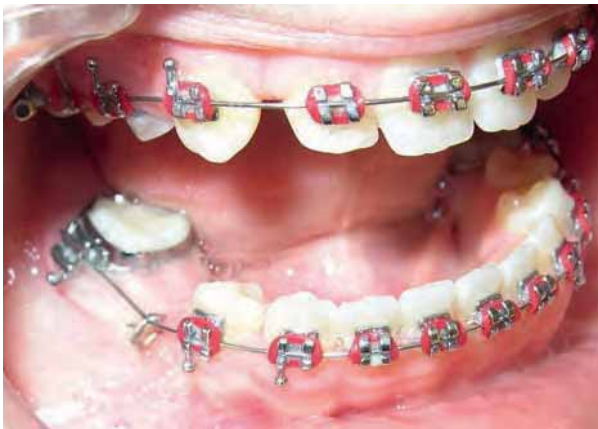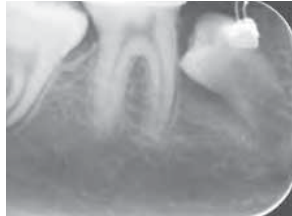
18TH MONTH

45 is moving with the light force from the 16 HA NiTi wire.
(But will the root develop properly?)

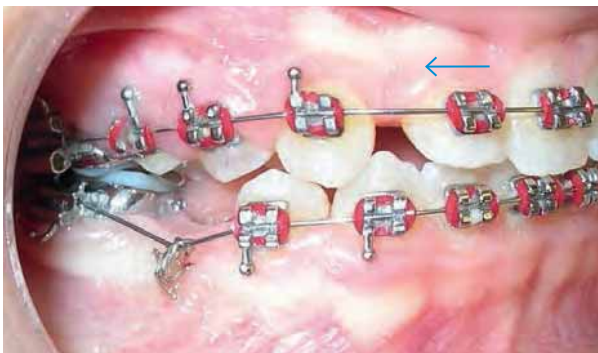Before ▼



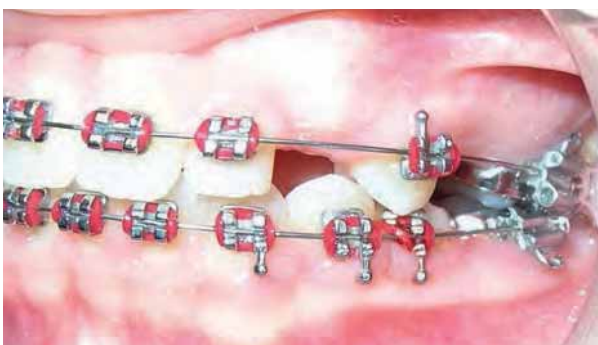2 months after surgery ▼



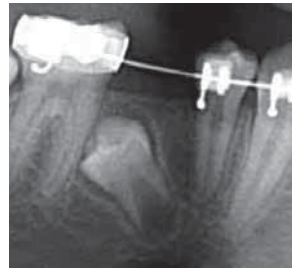2 months after surgery ▲



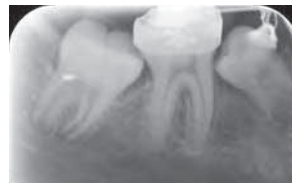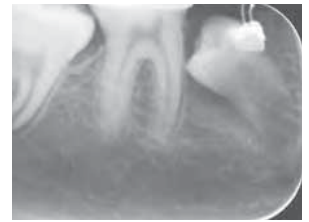
At each visit the wires of the attachment are tightened down around the archwire, thus reactivating the force.



16th month ▼



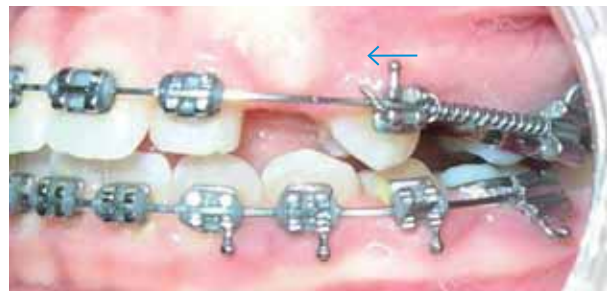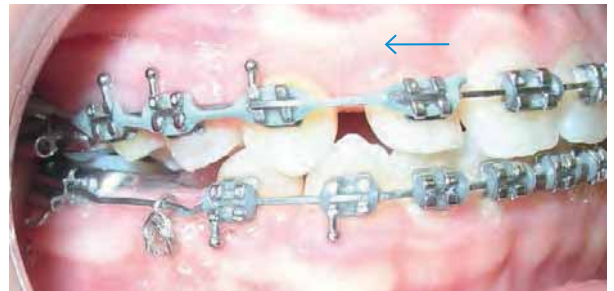
18th month ▼



19th month ▲

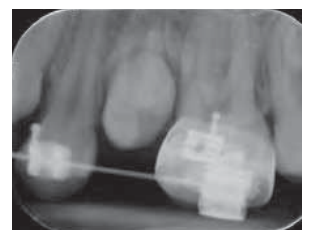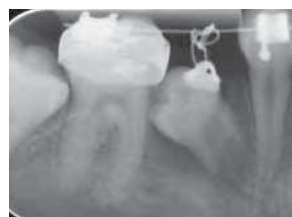20TH MONTH

45 is starting to erupt.



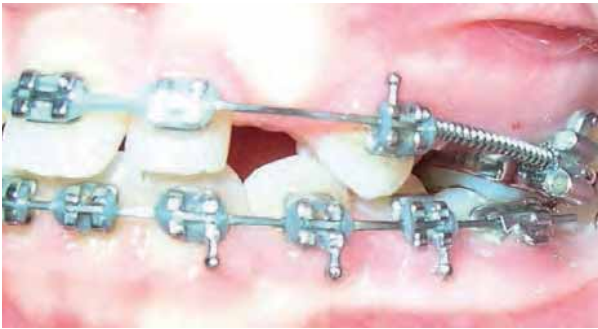
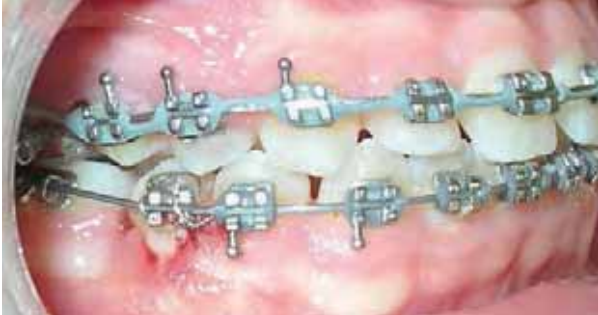MAX: 19x25 steel, L-L CH 16 to 12. O-C spring NiTi for 25 which has started to erupt.

MAND: 20x20 HA NiTi. 45 is starting to push through the surface.



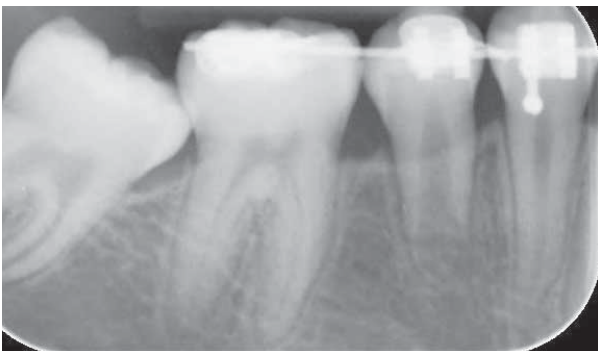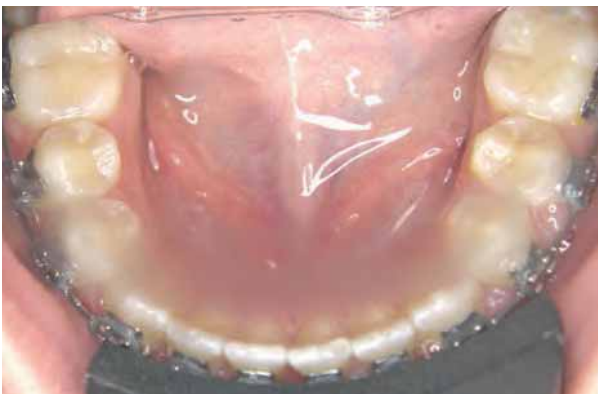22ND MONTH

45 is bracketed and tied in to the wire.

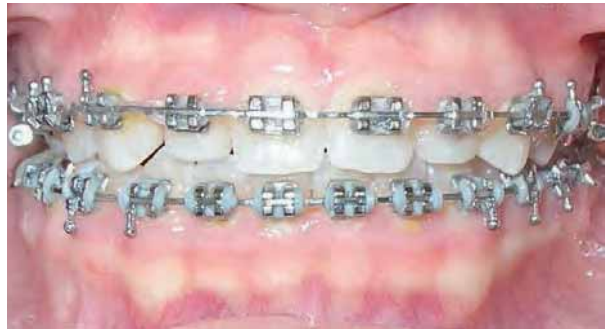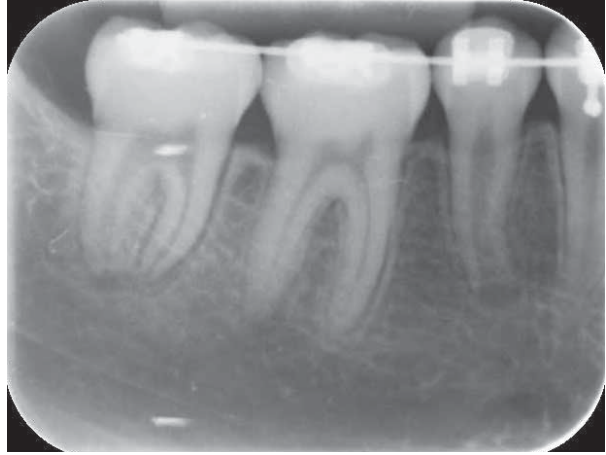**23RD MONTH**

MAND: Removed band on 46 (so it will not block-out 47) and placed a tube.

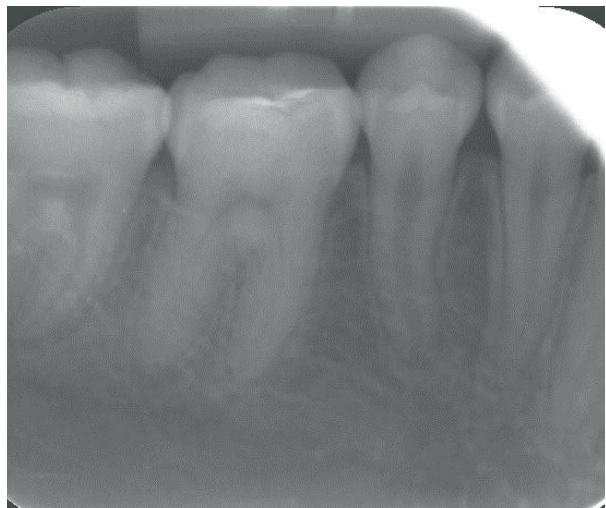
Root of 45 continues to slowly develop.

**27TH MONTH**

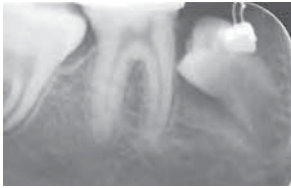Root of 45 continues to form.



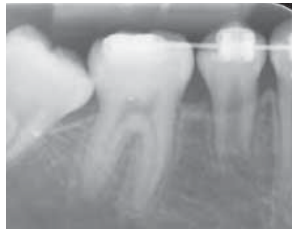
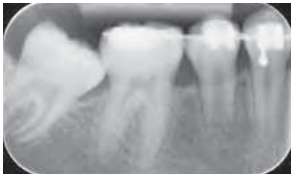
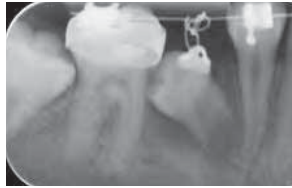It is apparent that 45 has been successfully saved (the root continues to form normally and the apex closes).



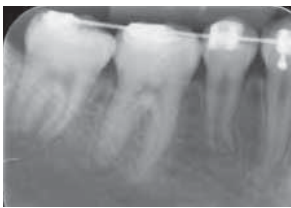18th month ▼



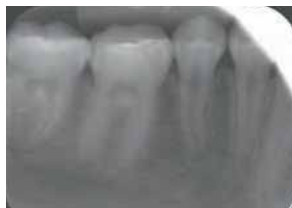20th month ▼



23rd month ▲



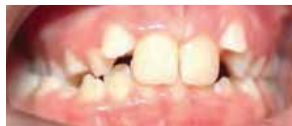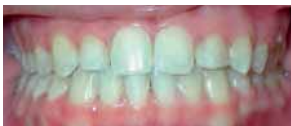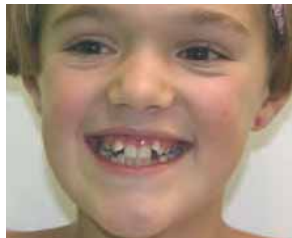24th month ▲



27th month ▼



30th month ▼



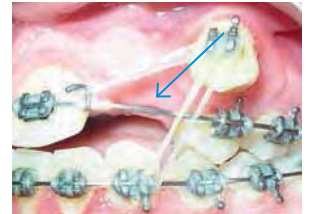
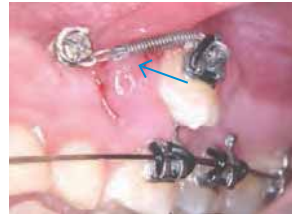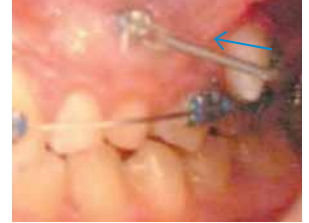
CASE: female, 13 years old

12 and 22 are agenetic.

23 is very ectopic and is located distal to 24.

For the complete case: see the last case in chapter 25: Mini-screw / TAD.

2nd month ▼

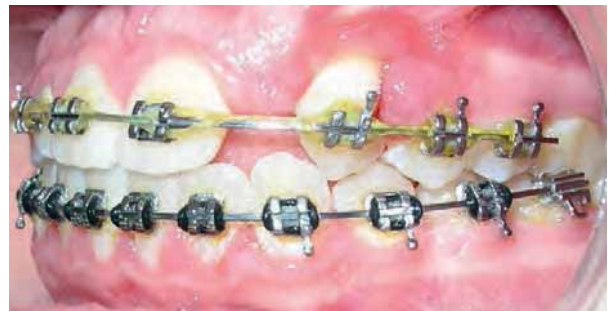
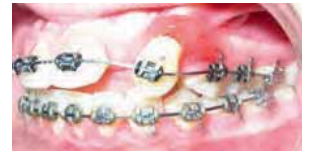
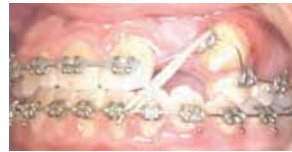3rd month ▲

6th month ▲

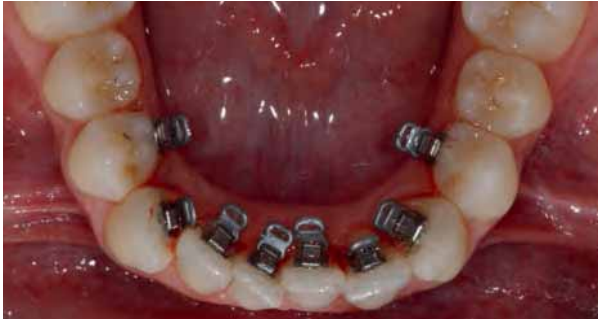8th month ▼

11th month ▼



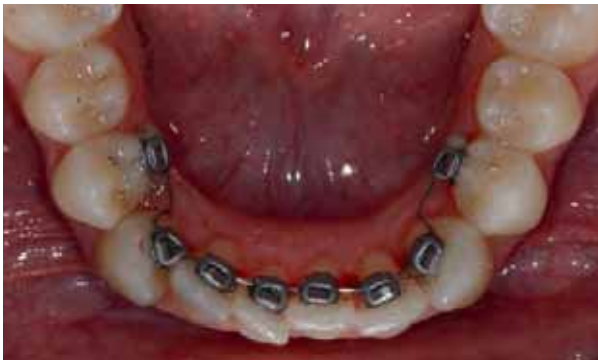13th month ▲

Brackets should be bonded with the ligatures already attached to the gingival tie-wings. Now it is an easy task to simply place the wire in the slots and close the ligatures on the upper tie-wings to activate the wire.



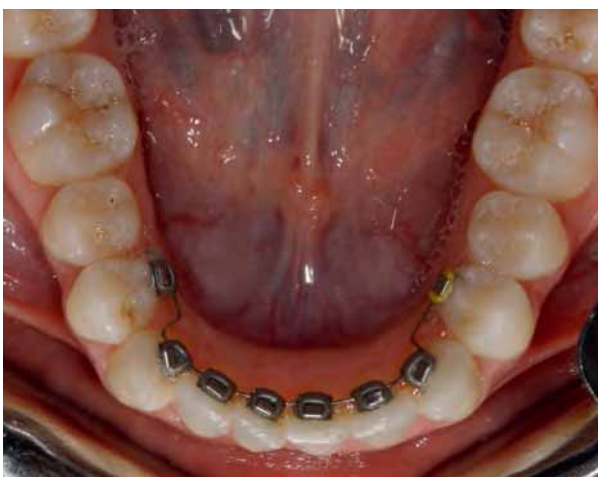12 NiTi with “distal-bends” and composite so the wire doesn’t slide out of the brackets. The *Slide* ligatures are closed. Allow the wire to work for 1–2 months before beginning slicing. ♥

The goal is to align the front teeth without changing the posterior occlusion. To stabilize the posterior occlusion, the 4s and the 5s can be temporarily bonded together with a flow-type composite.



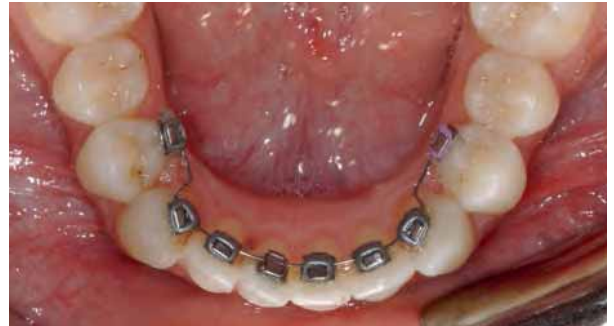2 MONTHS LATER

Begin stripping. The same ligatures can remain in place for about 4 months.



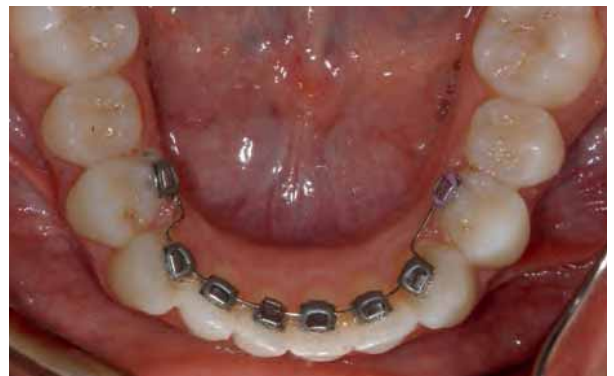3RD MONTH

14 NiTi. Stripping.

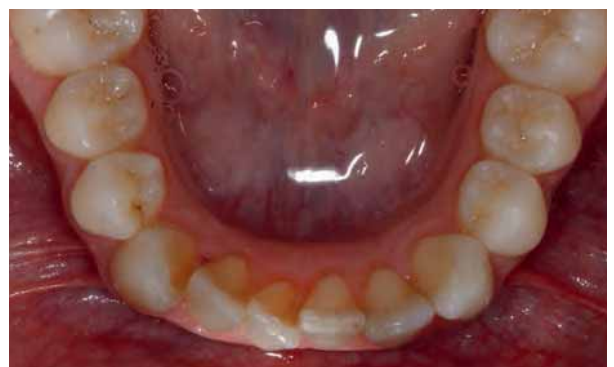

5TH MONTH

Stripping.



Beginning.



WORKSHOP 9: PLACEMENT OF FINISHING BENDS

Step-up, Step-down, Step-in, Step-out.

Step-up, Step-down bends are used to settle-in one or several teeth. In order to settle-in the bite correctly, large, rectangular NiTi wires (preferably a 19x25) should be used. These are softer and more forgiving than steel wires and the coupling effect of the rectangular wire assures settling-in with the proper crown/root torque. Because of this, lingual tipping of the crown is avoided as would occur when settling-in with small, round wires.

If Step pliers are used, steps can be quickly, efficiently and easily bent on NiTi wires, even HA NiTi. These pliers will not affect nor deform the overall arch shape while bending the wire.

There are available Step-pliers to make bends in various “step heights”. The most commonly used are 1 mm, .75 mm, .5 mm and .25 mm Step-pliers. A 3 mm step pliers is used for making an intrusion wire and for placing the mushroom bends for lingual wires.


To make steps, the wire should always be removed from the mouth. In this way one can assure the step bend is correct before replacing the wire in the brackets.

After a few practices, one becomes familiar with the correct orientation of the pliers in order to make the desired step bends. (*see photos*)

Pliers orientation to make a Step-down bend. 19x25 HA NiTi wire. Pliers are held in a parallel direction with the wire. ♦
.75 mm step.



Turn pliers 180° to complete the Step-down bend.



Completed .75 mm Step-down bend.



1 mm Step-down bend.



Turn the pliers 180° to complete the 1 mm Step-down bend.



Step-in/out bend is used for final finishing of the tooth position in the vestibular – lingual direction.

A round or square NiTi wire is preferable such as the 16, 16x16 or 18x18. However a 19x25 NiTi can be used.

The pliers are held at a 90° angle to the wire so that the bend is in the vestibular or lingual direction.

1. “Step-up type bend” being made



- The pliers are moved forward along the wire, flipped over, and a “step-down” type bend is made.



Completed 1 mm Step-out bend. ♥

“Step-down type bend” being made ♥ Final 1 mm Step-out bend ♥




.75 mm “Step-out” bend being made

- make a “Step-up type bend”.




.75 mm Step-out bend





- The pliers are moved forward along the wire, flipped over, and a “step-down” type bend is made.

Final .75 mm and 1 mm Step-out bends.



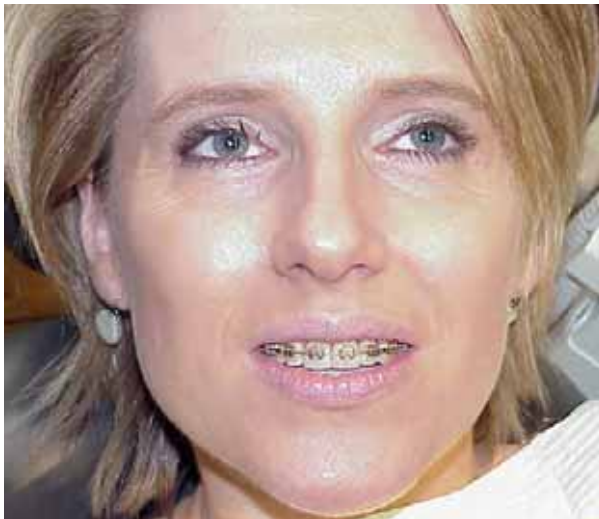Step-in bend: just reverses the order as seen for the Step-out bend.

- Make a “Step-down type bend”.
- Advance the pliers and make a “Step-up type bend”.



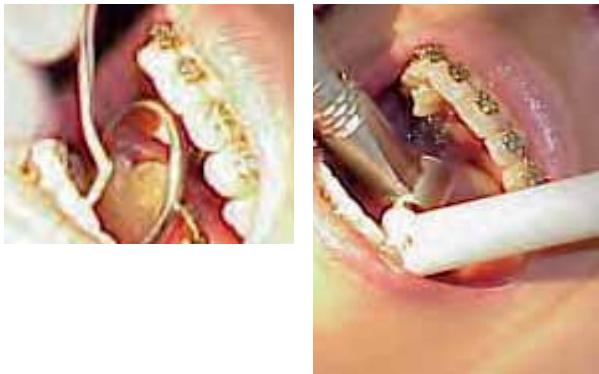Final .5 mm Step-in bend.

PLACEMENT OF FIXED LINGUAL RETENTION, REMOVAL OF BRACKETS AND BANDS AND PLACING REMOVABLE HAWLEY RETAINERS

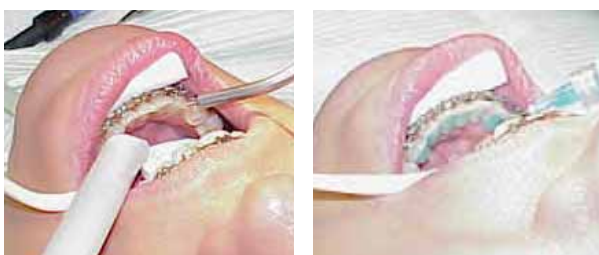


Retention: fixed lingual wire 3 to 3 or 4 to 4.

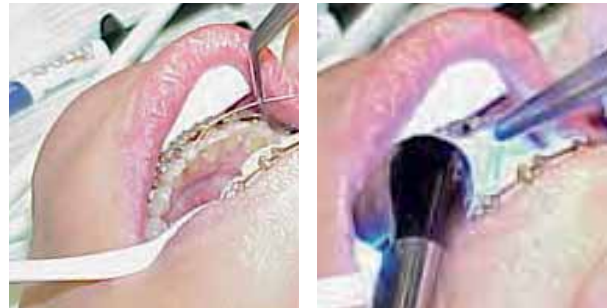Clean lingual surfaces 3 to 3 or 4 to 4. ♥



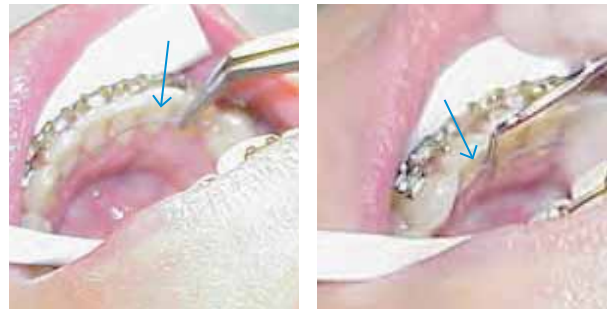
Rinse, dry, isolate and then etch the lingual surfaces. After 1 minute, rinse, dry and isolate for bonding.



Cut the “dead-soft wire” to the proper length. Bond the wire one tooth at a time to the lingual surfaces with a strong permanent light-cure composite.

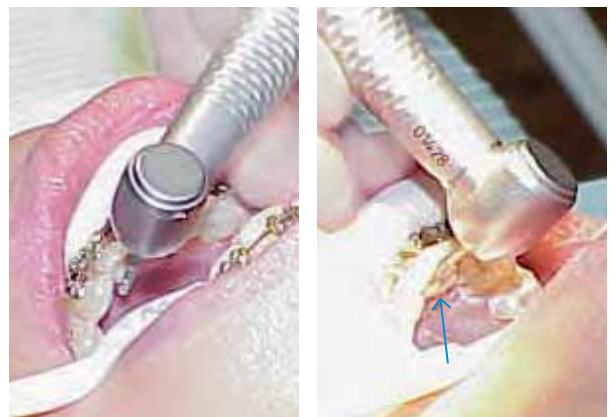

Before placing the composite, the wire is contoured around each tooth using an instrument.

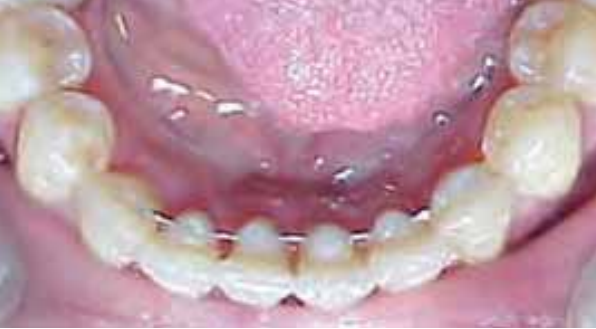

Contour/finish the composite (using a flat-end carbide bur).

A “step” can be made on the incisal side of each piece of composite (using a flat-end carbide bur).



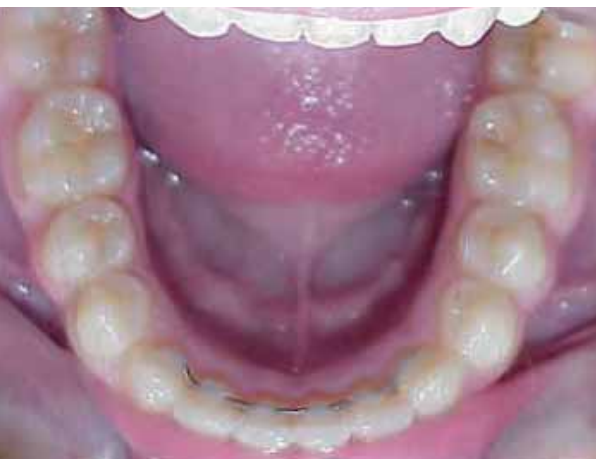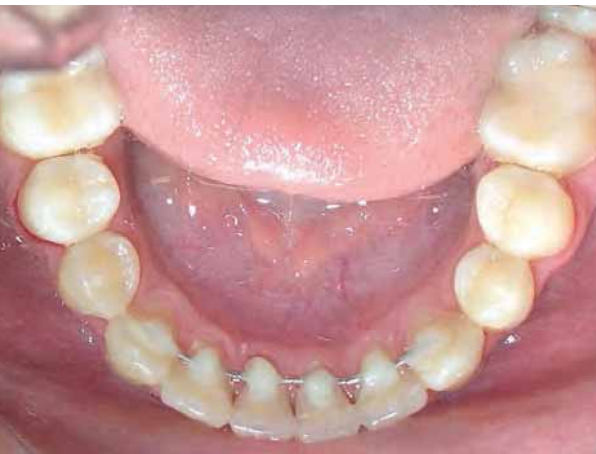Wire should be on gingival 1/3 of teeth so that removable retainer can finish above the composite and then the acrylic of the removable retainer will rest on top of these steps in the composite.



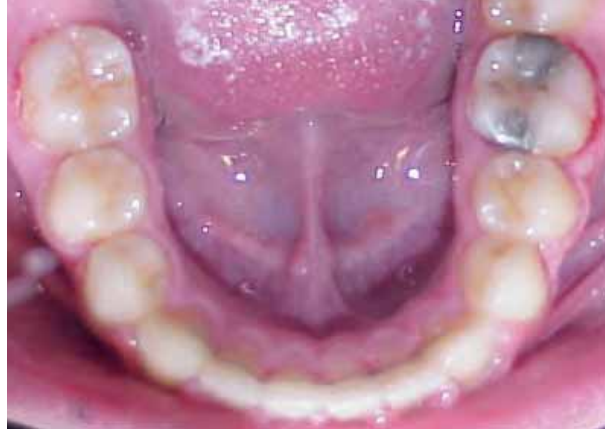Retainer wire prepared in the labo, to be placed "indirectly" using the placement "key" to orient the wire precisely.



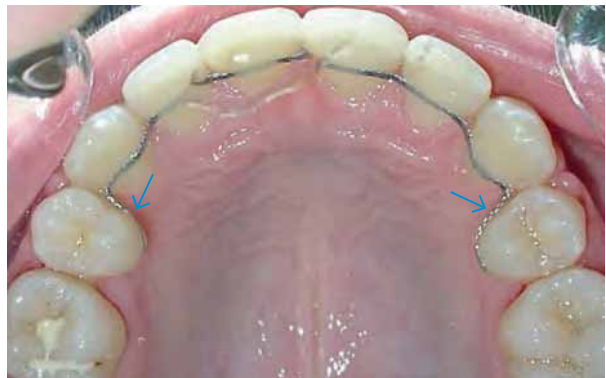Examples of fixed retainers from 3 to 3 using dead soft wire and composite. ♥



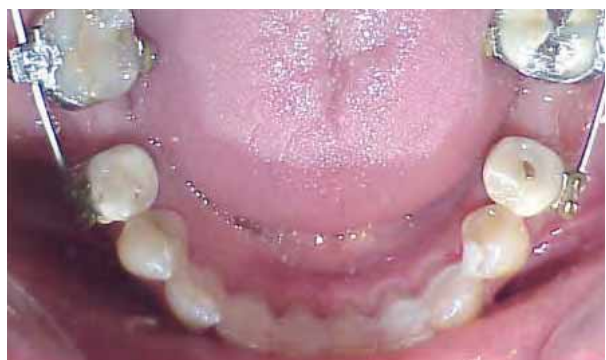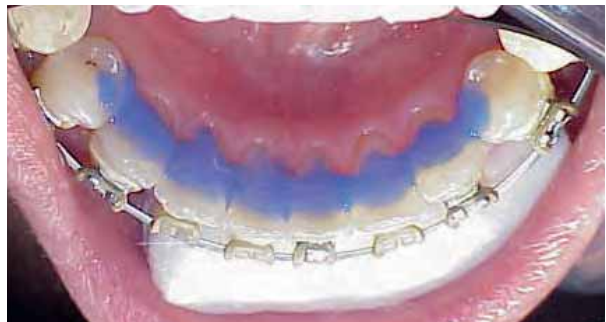Fixed dead-soft retainer from 34 to 44: this is made from a periodontal splint "metal mesh" with composite. Result is a very flat retainer. ♥



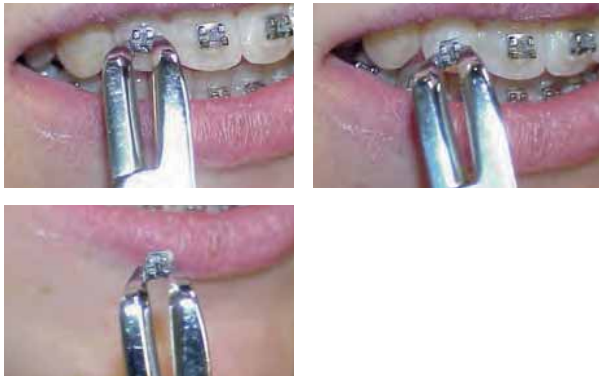Fixed wire retainer from 14 to 24 to hold extraction spaces closed. ♥



Fiber glass fixed retainer. ♥



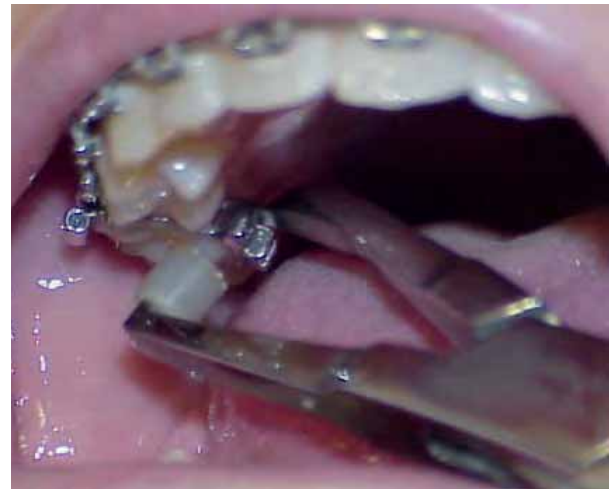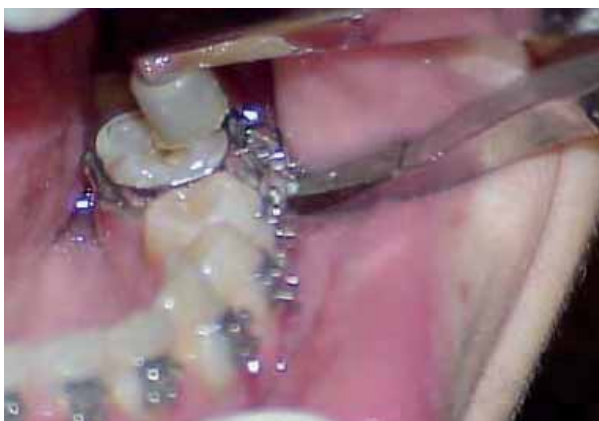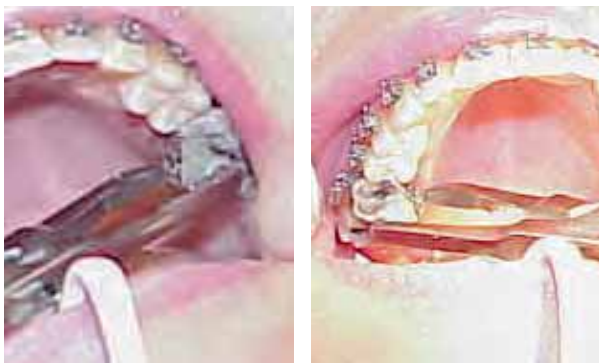Remove brackets using bracket removing pliers.



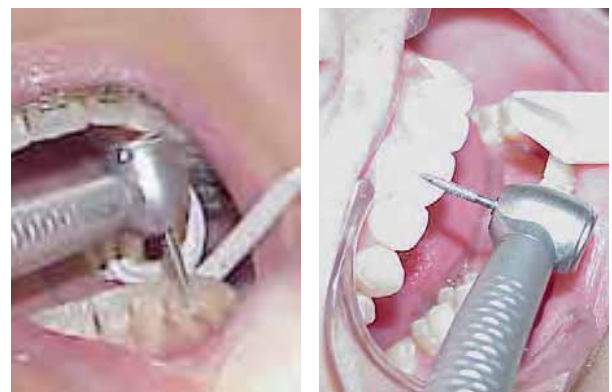For patient comfort, one can “support or stabilize” each tooth with a finger from the other hand.



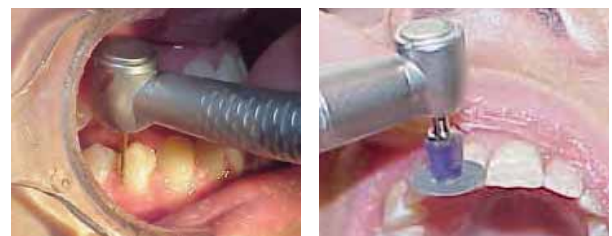
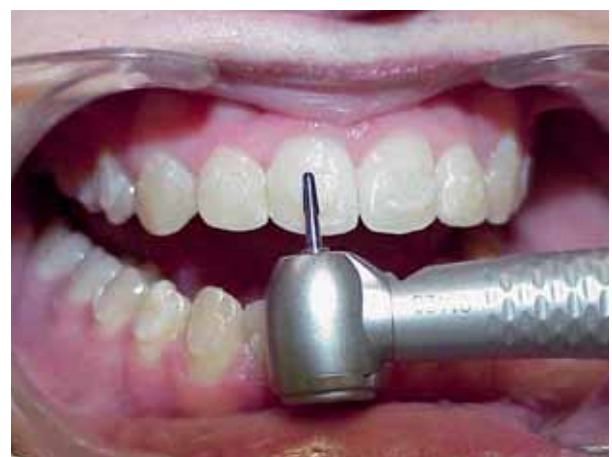Remove bands using the band removing pliers. Engage the band, and then with the plastic part on the occlusal surface, squeeze the handles together which will break the cement bond – don't pull on the band.

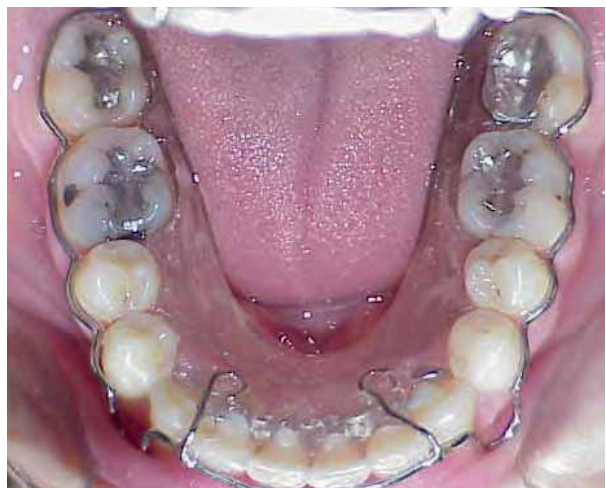
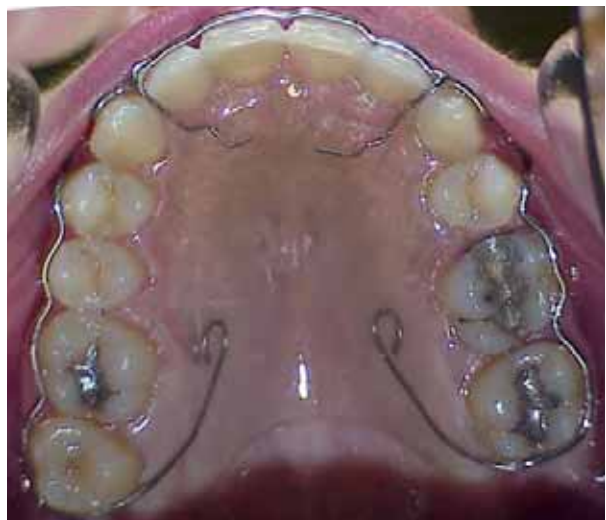
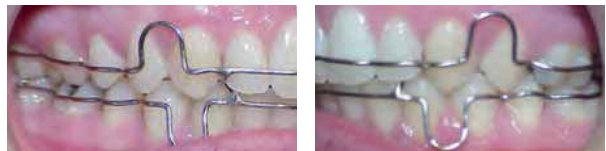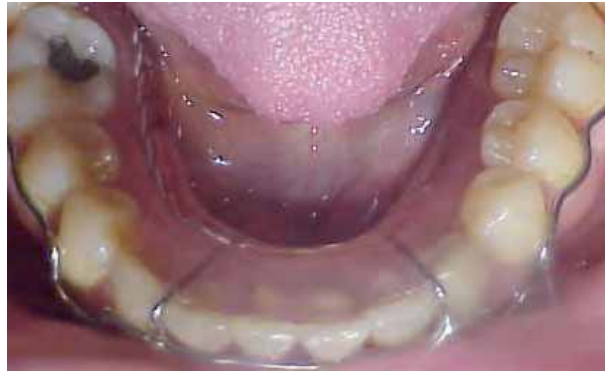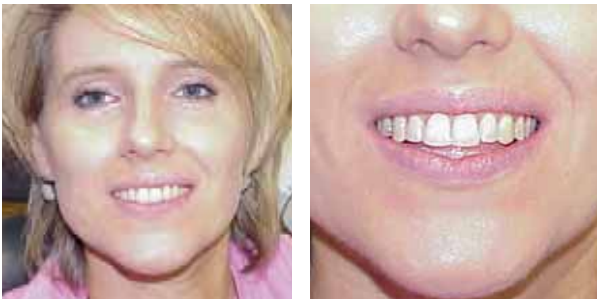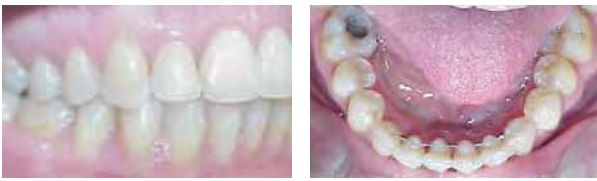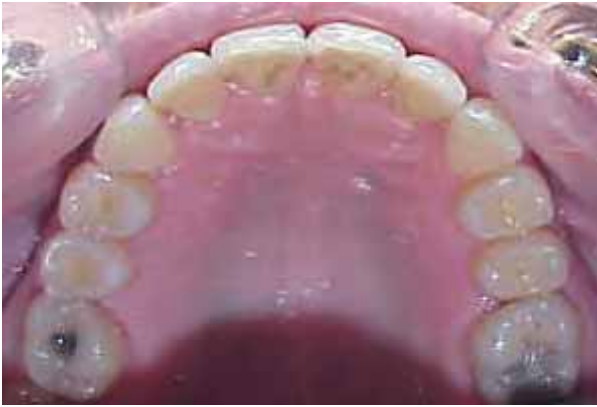Finish: first remove the bulk of the composite with large diamond burs. Then using water, finishing burs and discs are used for finishing.



Then along with water, use finishing burs and discs.





Wrap-around Hawley retainers ♥

